






# Intrahospital mortality of patients presenting with cardiac tamponade: retrospective analysis

 Domagoj Vučić<sup>1,2\*</sup>,  
 Sergej Nadalin<sup>1,3</sup>,  
 Zvonimir Bosnić<sup>4</sup>,  
 Ana Kovačević<sup>1</sup>,  
 Katica Cvitkušić Lukenda<sup>1,2</sup>

<sup>1</sup>General Hospital "Dr. Josip Benčević", Slavonski Brod, Croatia

<sup>2</sup>Josip Juraj Strossmayer University of Osijek, Faculty of Dental Medicine and Health Osijek, Osijek, Croatia

<sup>3</sup>Catholic University of Croatia, School of Medicine, Zagreb, Croatia

<sup>4</sup>Josip Juraj Strossmayer University of Osijek, Faculty of Medicine, Osijek, Croatia

**KEYWORDS:** cardiac tamponade, cisplatin, intrahospital mortality, pericardiocentesis.

**CITATION:** *Cardiol Croat.* 2024;19(3-4):135-6. | <https://doi.org/10.15836/ccar2024.135>

**\*ADDRESS FOR CORRESPONDENCE:** Domagoj Vučić, Opća bolnica "Dr. Josip Benčević", Andrije Štampara 42, HR-35000 Slavonski Brod, Croatia. / Phone: +385-35-201-685 / E-mail: [domagojvucicmedri@gmail.com](mailto:domagojvucicmedri@gmail.com)

**ORCID:** Domagoj Vučić, <https://orcid.org/0000-0003-3169-3658> • Sergej Nadalin, <https://orcid.org/0000-0002-1601-9094> • Zvonimir Bosnić, <https://orcid.org/0000-0002-4101-9782> • Ana Kovačević, <https://orcid.org/0000-0002-8909-9216> • Katica Cvitkušić Lukenda, <https://orcid.org/0000-0001-6188-0708>

**Introduction:** The pericardium is a double-walled sac (consisting of visceral and fibrous layers) between which lies the pericardial space, enveloping the heart and the roots of blood vessels entering or exiting the heart<sup>1</sup>. Although pericardial effusion can arise from various pathological conditions, its etiology is typically presumed based on clinical presentation and comorbidities, and an accurate diagnosis is established through biochemical, microbiological, and cytological analysis of the effusion. However, pericardiocentesis is an invasive procedure indicated when effusion onset is symptomatic or accompanied by tamponade, or when its etiology is unclear<sup>2,3</sup>.

**TABLE 1. The patient characteristics.**

	No. of patients (%)
<b>Sex</b>	
Males	32 (66.7)
Females	16 (33.3)
<b>Etiology</b>	
Malignant disease	19 (39.6)
Inflammation	8 (16.7)
Post-procedural	7 (14.6)
Other	14 (29.2)
<b>Therapy</b>	
No therapy	1 (2.1)
Drainage	36 (75.0)
Surgery	8 (16.7)
Conservative	3 (6.3)
<b>Application of cisplatin</b>	
No	39 (81.3)
Yes	9 (18.8)
<b>Intrahospital mortality</b>	
No	35 (72.9)
Yes	13 (27.1)
<b>Total</b>	48 (100)

RECEIVED:  
October 22, 2023

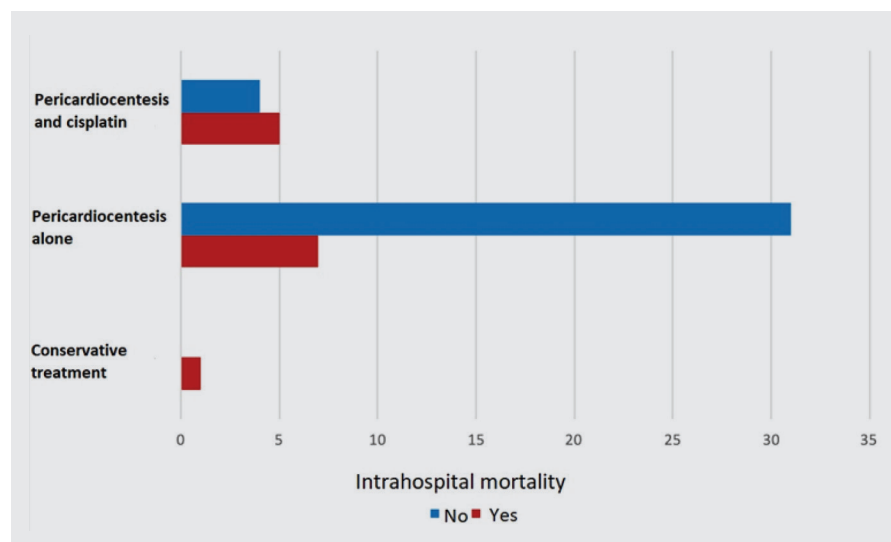
ACCEPTED:  
October 27, 2023



## Intrahospital mortality of patients presenting with cardiac tamponade: retrospective analysis

**Patients and Methods:** The retrospective analysis included 48 patients with echocardiographically confirmed cardiac tamponade of various etiologies in the period from 2016 to 2021. Descriptive statistical data are presented as a percentage. Due to a small sample size and uneven distribution, the examination of intrahospital mortality between patient groups, based on etiology and effusion treatment, was performed using the Fisher's exact test and statistical significance was indicated as p-value < 0,05. The statistical analysis was conducted using IBM SPSS Statistics.

**Results:** The median age was 66.5 years (IQR 59-72 years), with a minimum value of 21 years and a maximum of 87 years (**Table 1**). No statistically significant difference in intrahospital mortality was found among patients with different etiologies of cardiac tamponade ( $p > 0.05$ ). However, patients treated with a combination of cisplatin and pericardiocentesis had a lower mortality rate compared to those treated with pericardiocentesis alone,  $p < 0.05$  (**Figure 1**).



**FIGURE 1.** Statistically significant difference in intrahospital survival among patients treated with a combination of cisplatin and pericardiocentesis and those undergoing pericardiocentesis alone ( $p = 0.016$  - Fisher's exact test).

**Conclusion:** Malignant diseases are one of the leading causes of death worldwide, and when combined with pericardial effusion and tamponade, the most common ones are lung and breast cancer, melanoma, and lymphoma. The therapy of choice for acutely occurring pericardial effusion is pericardiocentesis, which alleviates symptoms and provides additional diagnostic possibilities. The effectiveness of cisplatin administration in combination with pericardiocentesis is independent of hemodynamic instability parameters and inflammatory markers in patients with recurrent pericardial effusion.

### LITERATURE

1. Little WC, Freeman GL. Pericardial disease. *Circulation*. 2006 Mar 28;113(12):1622-32. <https://doi.org/10.1161/CIRCULATIONAHA.105.561514>
2. Sagristà-Sauleda J, Mercé AS, Soler-Soler J. Diagnosis and management of pericardial effusion. *World J Cardiol*. 2011 May 26;3(5):135-43. <https://doi.org/10.4330/wjc.v3.i5.135>
3. Darocha S, Wilk M, Walaszewska-Czyż A, Kępski J, Mańczak R et al. Determinants of Survival After Emergency Intrapericardial Cisplatin Treatment in Cancer Patients with Recurrent Hemodynamic Instability After Pericardiocentesis. *In Vivo*. 2018 Mar-Apr;32(2):373-379. <https://doi.org/10.21873/invivo.11248>