



LAPAROSCOPY FOR RISK-REDUCING CYTOREDUCTIVE SURGERY AND HYPERTHERMIC INTRAPERITONEAL CHEMOTHERAPY (CASE SERIES AND REVIEW OF LITERATURE)

VEDRANA BIOŠIĆ¹, EMIL KINDA² and PETAR MATOŠEVIĆ²

¹County Hospital Čakovec, Čakovec, Croatia;

²Department of Surgery, University Hospital Centre Zagreb, Zagreb, Croatia

Summary

Open cytoreductive surgery (CRS) plus hyperthermic intraperitoneal chemotherapy (HIPEC) is still considered the golden standard of treatment, but for well-selected patients, minimally invasive surgery is showing promising results in reducing overall morbidity and hospital stay with no apparent consequences on long-term outcomes. One area where minimally invasive modalities bring evident benefits is risk-reducing CRS plus HIPEC where usually the overall bulk of resections being made are procedures where laparoscopy already is the golden standard of treatment. We present a case series of three patients with type II low-grade appendiceal mucinous neoplasm (LAMN) who, after reviewing the pathological and radiological findings, were selected for risk-reducing laparoscopic CRS and HIPEC. One of the patients was converted to open surgery due to discrepancies between the intraoperative findings and the preoperative radiological assessment. The median follow-up was 17 months with no recurrence found. A review of the Pubmed database was performed and was in congruence with our experience: The role of laparoscopic CRS plus HIPEC in well-selected patients surpasses diagnostic or palliative purposes and is an important option especially when speaking about risk-reducing surgeries with several benefits concerning morbidity and noninferiority in long-term oncological outcomes.

KEYWORDS: *laparoscopy, HIPEC, CRS, LAMN.*

INTRODUCTION

Although terms like Jelly belly (1) (gelatinous masses filling the abdominal cavity) and omental cake (2) (infiltration and encompassment of the omentum by mucinous deposits) might seem endearing and less than serious, pseudomyxoma peritonei is well recognized as a severe condition, usually as a result of low-grade appendiceal mucinous neoplasms (LAMN) or low-grade mesothelioma with historically abysmal results in treatment. Even Werth, who was the first to describe the pathology of the disease in 1884, acknowledged its severity and spoke of frequent fatal outcomes (3).

With the introduction of cytoreductive surgery (CRS) followed by hyperthermic intraperito-

neal chemotherapy (HIPEC), the prognosis of patients with *pseudomyxoma peritonei* has improved dramatically. The results of the studies reported a 20-year overall survival (OS) of greater than 70% (bearing in mind the correlation of OS with the Index of peritoneal cancer (PCI), introduced by Sugarbaker - OS at the 10-year mark falls to 55% with PCI greater than 21)(4,5). Open CRS plus HIPEC is still considered the golden standard of treatment but for well-selected patients, minimally invasive surgery is showing promising results in reducing overall morbidity and hospital stay with no apparent consequences on long-term outcomes

Corresponding author: Vedrana Biošić, County Hospital Čakovec, I. G. Kovačića 1E; 40 000 Čakovec, Croatia. e-mail: vedrana.biosic@gmail.com

Table 1.

An overview of the basic characteristics of the patients in the three presented cases

	Case 1	Case 2	Case 3
Gender	male	male	female
Age	47	59	28
Prior surgeries	Lap. appendectomy	Lap. appendectomy	Lap. appendectomy
PCI	2	7	0
CC	0	0	0
HIPEC drugs	Mitomycin, Doxorubicin	Mitomycin, Doxorubicin	Mitomycin
Operative time (including drug perfusion)	250 min	405 min	260 min
Extent of surgery	Right colectomy, falciform and round ligament excision, peritonectomy	Right colectomy, falciform and round ligament excision, omentectomy, peritonectomy	Right colectomy
Conversion	-	+	-
Postoperative complications	-	-	Pneumothorax (Clavien-Dindo gr. IIIa)
Hospital stay (days)	8	8	7
Follow-up	17 months	14 months	38 months
Recurrence	no	no	no

(4,6-9). This is especially true for risk-reducing CRS plus HIPEC where usually the overall bulk of resections being made are procedures where laparoscopy already is the golden standard of treatment. Risk-reducing CRS with HIPEC refers to the treatment of type II LAMN where global intraabdominal dissemination has not yet occurred, but the surgery is being performed to prevent the latter from happening. Our paper aims to present a case series where risk-reducing laparoscopic CRS and HIPEC were used with a review of literature stressing the role of minimally invasive surgery in the treatment of type II LAMN.

METHODS

We present a series of three cases of patients who, after reviewing the pathological and radiological findings, were selected for risk-reducing laparoscopic CRS and HIPEC. We additionally searched of the Pubmed database to review the literature on the role of minimally invasive CRS and HIPEC and adequate patient selection.

RESULTS

All patients were referred to our institution from other centers after laparoscopic appendectomy with a pathohistological diagnosis of type II

LAMN. After clinical and radiological evaluation, the three patients were selected for minimally invasive treatment with one of the patients being converted to open surgery due to discrepancies between the intraoperative findings and the preoperative radiological assessment. The median follow-up was 17 months with no recurrence found (Table 1.) A review of the Pubmed database was performed in December of 2022. with keywords: *laparoscopy*, *HIPEC*, *CRS*, and *LAMN*.

CASE ONE

A 47-year-old patient was referred to our institution after a type II low-grade appendiceal mucinous neoplasm (LAMN) was diagnosed during the pathohistological examination of the urgent appendectomy specimen. No signs of intraabdominal disease spread were observed on radiological evaluation, and laparoscopic risk-reducing CRS with HIPEC was planned. A supraumbilical incision was made with CO₂ insufflation via the Veress needle to achieve a pneumoperitoneum of 12 mmHg. The optical 10 mm trocar was placed on the left side in the medioclavicular line and under visual supervision the remaining trocars and instruments were placed: a 12 mm trocar in the medioclavicular line on the left side above the optical trocar and a 5mm trocar beneath it. An additional 5 mm trocar was introduced supraumbilically on the Veress needle entry site. A stan-

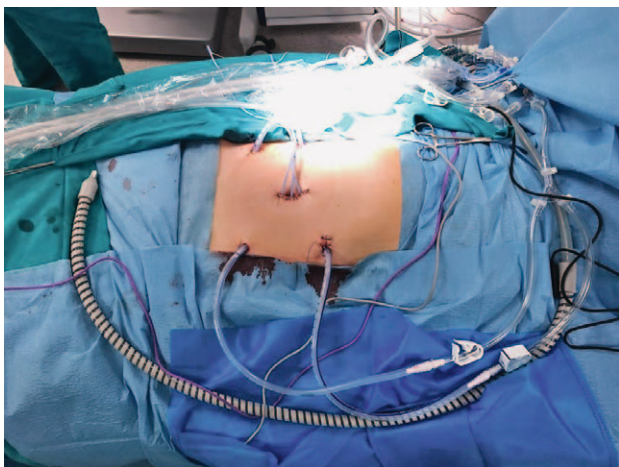


Figure 1. Arrangement of drains and temperature probes during laparoscopic HIPEC

standardized exploration of the peritoneal cavity was performed and PCI was assessed. It was calculated as two so we continued the laparoscopic procedure. Intraoperative findings included status after appendectomy and mucinous deposits surrounding the cecum and along the right paracolic sulcus. The surgical resection included falciform ligament and round ligament excision, peritonectomy of the affected area, and right colectomy with extracorporeal ileotransversal anastomosis. The sight of the mini-median laparotomy for specimen extraction was closed after three temperature probes were placed and fixed intraabdominally. Under camera supervision, four intraabdominal drains were placed - two inflow drains on the left side using the trocar entry sites, and two outflow drains on the right side. Finally, a HIPEC protocol was used consisting of mitomycin and doxorubicin, with perfusion time being 60 minutes at 42 degrees Celsius (Figure 1). Pathohistological examination showed clear resection margins. The postoperative recovery was uneventful, and the patient was discharged on the eighth postoperative day with no recurrence during the 17 months of postoperative surveillance.

CASE TWO

A 59-year-old patient was referred to our institution after being diagnosed with type II LAMN (T4aNxM1a). A laparoscopic appendectomy was performed in another center, and a pathohistological examination revealed a positive resection margin at the base of the appendix. After clinical

and radiological evaluation, laparoscopic CRS with HIPEC was planned. The pneumoperitoneum and the access were as described in Case one (see above). During laparoscopic exploration, peritoneal deposits of the right subphrenium and in the Morisson space were found, and we decided to convert to an open surgery procedure. We performed a right colectomy with ileotransversal anastomosis and hepatic mobilization to alleviate the right subphrenic peritonectomy. Small mucinous deposits on the small bowel mesentery and the liver surface were electrocauterized. The falciform ligament and omentum were excised and sent to pathohistological examination. We used a closed-abdomen HIPEC system to deliver doxorubicin and mitomycin under 42 degrees Celsius with a perfusion time of 101 minutes. Intraoperative PCI was calculated as 7. The pathohistological examination showed clear resection margins and 17 lymph nodes without malignant infiltration. The patient was discharged on the eighth postoperative day without any complications. Postoperative surveillance (14 months) showed no recurrence.

CASE THREE

A 28-year-old female patient was referred to our institution with a diagnosis of type II LAMN (laparoscopic appendectomy was performed in another center). After clinical and radiological examination, laparoscopic CRS with HIPEC was planned. The trocar arrangement was as described in Case one (see above). Intraoperatively, no signs of intraabdominal deposits were found. A right colectomy was performed with an extracorporeal anastomosis (Figure 2). We used the same laparoscopic HIPEC system as was presented in Case one (see above). The HIPEC procedure involved the perfusion of mitomycin at 42 degrees Celsius for 60 minutes. PCI score was 0. However, on the fourth postoperative day, the patient developed dyspnea which led to the placement of a thoracic drainage for a radiologically verified pneumothorax. After the removal of drainage on the fifth postoperative day the patient had no further complications and was discharged on the 7th postoperative day in good condition. Postoperative surveillance showed no recurrence. 24 months after the procedure the patient delivered a baby after an uneventful pregnancy.

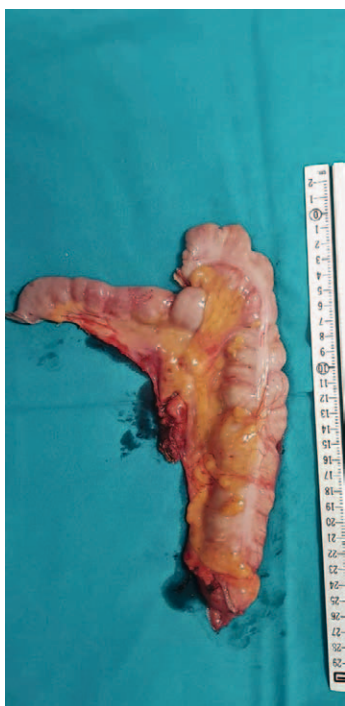

Figure 2. The intraoperative/surgical specimen

DISCUSSION

Low-grade appendiceal mucinous neoplasm (LAMN) as a subgroup of epithelial mucinous neoplasms of the appendix is a rare condition found in up to 2% of appendectomy specimens(10). According to the PSOGI 2016. classification(1) LAMN are divided into type I and II (non-perforated (type I) versus perforated appendix with mucinous deposits found outside the appendix lumen (type II)). A distinct characteristic of LAMN is that it rarely shows lymphatic and hematologic dissemination but inherently carries the hazard of peritoneal spread causing a malignant condition called pseudomyxoma peritonei(11). With type II LAMN there is no real consensus on an adequate treatment modality. Studies that promoted the watch-and-wait option (meaning appendectomy as the only and sufficient treatment with periodical radiological surveillance) defended this position with low recurrence rates in radically resected LAMN, even with local extra appendiceal mucinous deposits. Furthermore, additional procedures after appendectomy were accompanied with a risk of perioperative morbidity (open CRS plus HIPEC have been associated

with grade III and IV morbidity by the Clavien-Dindo classification(12-14). Guaglio et al. found a recurrence in 4.9% of patients while a much larger number (51.2%) had evidence of extraappendiceal mucin intraoperatively during appendectomy(15). This being said, a disparate predisposition for intraperitoneal recurrence has been found with acellular versus cellular mucinous deposits (4-8% and 33-75% respectively)(5). We would like to argue that in well-selected patients laparoscopic CRS + HIPEC largely mitigates the major perioperative complications seen in open surgery. We have found that an adequate pathohistological description of the cellularity of mucinous deposits in cases of perforated appendix is seldom given. The watch-and-wait modality could also cause discomfort and anxiety in patients decreasing thereby quality of life. In the third case, the young female patient we described would have not been able to carry out a pregnancy with the high radiation doses brought on by CT surveillance. Searching the Pubmed database from the year 2000 onward, we found thirteen studies that evaluated the effectiveness of laparoscopic CRS plus HIPEC for treating a rare disease. Due to the generally low incidence of the disease, and the above-mentioned lack of consensus on its treatment, all of the studies dealt with a lower number of patients examined. The largest cohort consisted of only eighteen patients who underwent laparoscopic surgery(6). Our experience is in concordance with the mentioned studies which found that long-term outcomes between laparoscopic and open CRS+HIPEC are comparable with those in open procedures while decreasing overall postoperative complications and shortening the length of hospital stay(4-6,16). Because all of our cases were considered to be risk-reducing surgeries, the expected PCI was low and not an issue, but when the degree of dissemination is suspected, most studies use PCI as a selection criterion for laparoscopy, with a cut-off value of 10, without prior major intraabdominal surgery(6,8,17,18). Principles used intraoperatively were the ones proposed by Sugarbaker. Naysayers of the minimally invasive modality mention a significantly prolonged operative time compared to open surgery. The latter loses importance as the learning curve progresses(5). We have not found this point to be an issue since all laparoscopic operations have been performed by experienced laparoscopic surgeons (P.M. and E.K.) Con-

cerns have also been made about the possibility of laparoscopy underestimating disease extent(16,19). We therefore stress the importance of the quality of preoperative radiological imaging and a standardised laparoscopic examination of the abdominal cavity. One of the three patients in our series was converted to open surgery due to discrepancies between the preoperative radiological assessment and the intraoperative finding.

CONCLUSION

Laparoscopic CRS with HIPEC is a feasible and beneficial treatment modality in selected patients with most of the literature including selection criteria as a PCI cut-off of 10 and no major prior intraabdominal surgery. In Case two, we converted to open surgery due to discrepancies between the preoperative radiological evaluation and the intraoperative finding. This stresses the importance of quality preoperative radiological imaging. A standardized and systematic abdominal exploration is crucial so that the extent of the disease will not be underestimated. The role of laparoscopic CRS with HIPEC in well-selected patients therefore surpasses diagnostic or palliative purposes and is an important option especially when speaking about risk-reducing surgeries with several benefits concerning the morbidity of patients and no difference in long-term oncological outcomes.

Abbreviations

CRS – Cytoreductive surgery
 HIPEC – Hyperthermic intraperitoneal chemotherapy
 LAMN – Low-grade appendiceal mucinous neoplasm

REFERENCES

- Govaerts K, Lurvink RJ, De Hingh IHJT, Van der Speeten K, Villeneuve L, Kusamura S, et al. Appendiceal tumours and pseudomyxoma peritonei: Literature review with PSOGI/EURACAN clinical practice guidelines for diagnosis and treatment. *Eur J Surg Oncol.* 2021;47:11-35. doi:10.1016/j.ejso.2020.02.012.
- Sugarbaker PH. Cytoreductive surgery and perioperative intraperitoneal chemotherapy: a new standard of care for appendiceal mucinous tumors with peritoneal dissemination. *Clin Colon Rectal Surg.* 2005 Aug;18(3):204-14. doi:10.1055/s-2005-916281.
- Werth in Kiel, Y. Klinische und anatomische Untersuchungen zur Lehre von den Bauchgeschwülsten und der Laparatomie. *Archiv für Gynaekologie*, 1884;24(1):100-118.
- Mercier F, Jeremie G, Alyami M, Delphine V, Vahan K, Pascal R, et al. Long-term results of laparoscopic cytoreductive surgery and HIPEC for the curative treatment of low-grade pseudomyxoma peritonei and multicystic mesothelioma. *Surg Endosc.* 2020 Nov;34(11):4916-4923. doi:10.1007/s00464-019-07280-1.
- Abudeeb H, Selvasekar CR, O'Dwyer ST, Chakrabarty B, Malcolmson L, Renehan AG, et al. Laparoscopic cytoreductive surgery and hyperthermic intraperitoneal chemotherapy for perforated low-grade appendiceal mucinous neoplasms. *Surg Endosc.* 2020 Dec;34(12):5516-5521. doi:10.1007/s00464-019-07349-x.
- Rodríguez-Ortiz L, Arjona-Sánchez A, Ibañez-Rubio M, Sánchez-Hidalgo J, Casado-Adam A, Rufián-Peña S, et al. Laparoscopic cytoreductive surgery and HIPEC: a comparative matched analysis. *Surg Endosc.* 2021 Apr;35(4):1778-1785. doi: 10.1007/s00464-020-07572-x.
- Arjona-Sánchez A, Cortés-Guiral D, Duran-Martínez M, Villarejo-Campos P, Sánchez-Hidalgo JM, Casado-Adam A, et al. Complete laparoscopic pelvic peritonectomy plus hyperthermic intraperitoneal chemotherapy. *Tech Coloproctol.* 2020 Oct;24(10):1083-1088. doi: 10.1007/s10151-020-02277-8.
- Arjona-Sanchez A, Esquivel J, Glehen O, Passot G, Turaga KK, Labow D, et al. A minimally invasive approach for peritonectomy procedures and hyperthermic intraperitoneal chemotherapy (HIPEC) in limited peritoneal carcinomatosis: The American Society of Peritoneal Surface Malignancies (ASPSM) multi-institution analysis. *Surg Endosc.* 2019 Mar;33(3):854-860. doi: 10.1007/s00464-018-6352-4.
- Cho CY, Veerapong J, Baumgartner JM, et al. Laparoscopic cytoreductive surgery and hyperthermic intraperitoneal chemotherapy: a prospective clinical trial and comparative analysis. *Surg Endosc.* 2023; Jul;37(7):5644-5651. doi: 10.1007/s00464-022-09589-w
- Delhorme JB, Villeneuve L, Bouché O, Averous G, Dohan A, Gornet JM, et al. Appendiceal tumors and pseudomyxoma peritonei: French Intergroup Clinical Practice Guidelines for diagnosis, treatments and follow-up (RENAPE, RENAPATH, SNFGE, FFCD, GERCOR, UNICANCER, SFCD, SFED, SFRO, ACHBT, SFR). *Dig Liver Dis.* 2022 Jan;54(1):30-39. doi: 10.1016/j.dld.2021.10.005
- McDonald JR, O'Dwyer ST, Rout S, Chakrabarty B, Sikand K, Fulford PE, et al. Classification of and cytoreductive surgery for low-grade appendiceal mucinous neoplasms. *Br J Surg.* 2012 Jul;99(7):987-92. doi: 10.1002/bjs.8739.
- Foster JM, Sleightholm RL, Wahlmeier S, Loggie B, Sharma P, Patel A. Early identification of DPAM in at-

- risk low-grade appendiceal mucinous neoplasm patients: a new approach to surveillance for peritoneal metastasis. *World J Surg Oncol*. 2016 Sep 13;14(1):243. doi: 10.1186/s12957-016-0996-0.
13. Esquivel J, Averbach A. Laparoscopic Cytoreductive Surgery and HIPEC in Patients with Limited Pseudomyxoma Peritonei of Appendiceal Origin. *Gastroenterol Res Pract*. 2012;2012:981245. doi: 10.1155/2012/981245.
 14. Bravo R, Jafari MD, Pigazzi A. The Utility of Diagnostic Laparoscopy in Patients Being Evaluated for Cytoreductive Surgery and Hyperthermic Peritoneal Chemotherapy. *Am J Clin Oncol*. 2018 Dec;41(12):1231-1234. doi: 10.1097/COC.0000000000000463.
 15. Guaglio M, Sinukumar S, Kusamura S, Milione M, Pietrantonio F, Battaglia L, et al. Clinical Surveillance After Macroscopically Complete Surgery for Low-Grade Appendiceal Mucinous Neoplasms (LAMN) with or Without Limited Peritoneal Spread: Long-Term Results in a Prospective Series. *Ann Surg Oncol*. 2018 Apr;25(4):878-884. doi: 10.1245/s10434-018-6341-9.
 16. Yurttas C, Überück L, Nadiradze G, Königsrainer A, Horvath P. Limitations of laparoscopy to assess the peritoneal cancer index and eligibility for cytoreductive surgery with HIPEC in peritoneal metastasis. *Langenbecks Arch Surg*. 2022 Jun;407(4):1667-1675. doi: 10.1007/s00423-022-02455-2.
 17. Sommariva A, Valle M, Gelmini R, Tonello M, Carboni F, De Manzoni G, et al. Laparoscopic Cytoreduction Combined with Hyperthermic Intraperitoneal Chemotherapy (HIPEC) in Peritoneal Surface Malignancies (PSM): Italian PSM Oncoteam Evidence and Literature Review. *Cancers (Basel)*. 2022 Dec 31;15(1):279. doi:10.3390/cancers15010279.
 18. Enomoto LM, Levine EA, Perry KC, Votanopoulos KI, Kuncewitch M, Shen P. Minimally Invasive Surgical Approaches for Peritoneal Surface Malignancy. *Surg Oncol Clin N Am*. 2019 Apr;28(2):161-176. doi: 10.1016/j.soc.2018.11.010.
 19. Passot G, Dumont F, Goéré D, Arvieux C, Rousset P, Regimbeau JM, et al. BIG-RENAPE Surgery Working Group. Multicentre study of laparoscopic or open assessment of the peritoneal cancer index (BIG-RENAPE). *Br J Surg*. 2018 May;105(6):663-667. doi: 10.1002/bjs.10723.

Sažetak

LAPAROSKOPIJA U PREVENTIVNOJ CITOREDUKCIJI I HIPEC-U KOD TIPA II LAMN-A (PRIKAZ SERIJE SLUČAJA TE PREGLED LITERATURE)

V. Biošić, E. Kinda, P. Matošević

Kad je riječ o citoredukciji i HIPEC-u, otvorena kirurgija se još uvijek smatra zlatnim standardom liječenja. Za dobro selekcionirane pacijente minimalno invazivna kirurgija ipak pokazuje obećavajuće rezultate uz smanjenje morbiditeta i dužine hospitalizacije te bez očitih negativnih posljedica na dugoročne onkološke ishode. Područje gdje su prednosti laparoskopije posebno uočljive su preventivni zahvati u liječenju tipa II mucinoznih neoplazmi apendiksa niskog gradusa gdje opseg kirurškog zahvata obično uključuje procedure u kojima je zlatni standard ionako minimalno invazivna kirurgija. U ovom radu prikazujemo seriju od tri pacijenta gdje je korištena preventivna laparoskopska citoreduktivna kirurgija te HIPEC pri čemu je u jednog pacijenta zahvat konvertiran u otvoreni zbog diskrepance između preoperativnog radiološkog nalaza te intraoperativnog stanja. Median postoperativnog praćenja je 17 mjeseci bez nađene progresije bolesti. Učinjeni pregled literature slaže se s našim iskustvom: uloga laparoskopije kod citoredukcije i HIPEC-a u dobro selekcioniranih pacijenta nadilazi dijagnostičke i palijativne mogućnosti i važan je modalitet liječenja osobito kod preventivnih zahvata s jasnim benefitima vezanim za morbiditet pacijenata te bez razlike u dugotrajnim onkološkim ishodima u usporedbi s otvorenom kirurgijom.

KLJUČNE RIJEČI: *laparoskopija, CRS, HIPEC, LAMN*