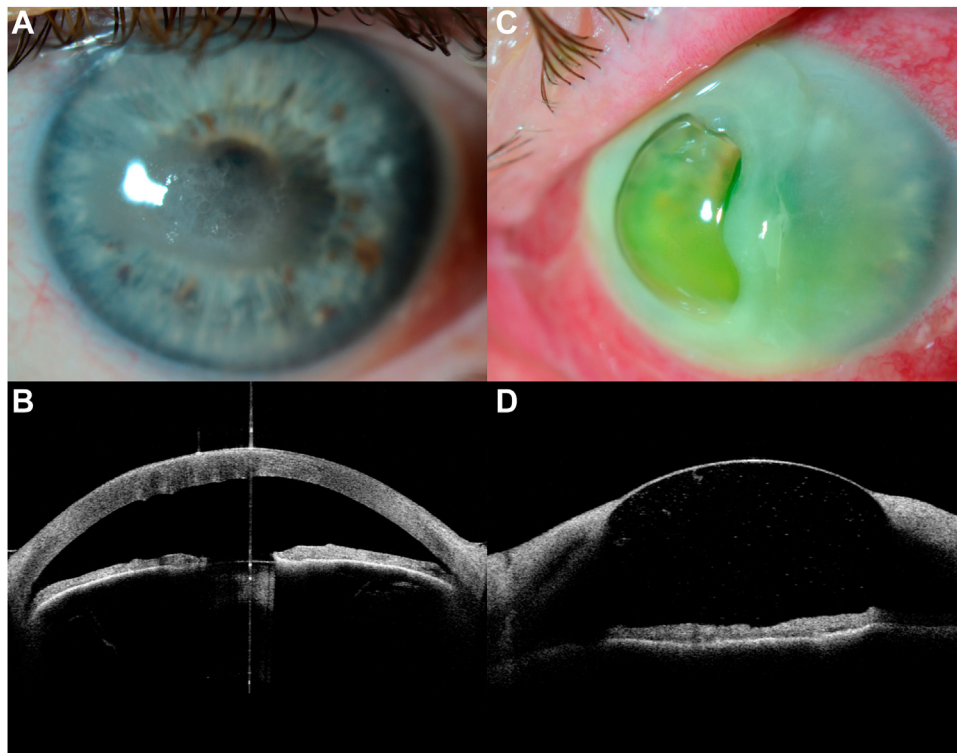


Pictures & Perspectives



Severe Descemetocoele after EDTA Chelation for Band Keratopathy

A 62-year-old man presented with bilateral band keratopathy (A, anterior segment [AS] photography; B, AS-OCT) with no other relevant systemic or ocular findings. The patient was treated with topical ethylenediaminetetraacetic acid (EDTA) 2% twice daily bilaterally. The patient reported acute vision loss in his left eye 20 days later. He showed a severe descemetocoele with surrounding stromal melting and anterior chamber inflammatory response (C, AS photography; D, AS-OCT). His right eye showed no significant changes. The following week, the patient required an urgent penetrating keratoplasty due to corneal perforation (Magnified version of Figure A-D is available online at www.aaojournal.org).

SANTIAGO MONTOLÍO-MARZO, FICO, FEBO^{1,2}

GUILLERMO RODRÍGUEZ-IRANZO, MD, FICO²

CRISTINA PERIS-MARTÍNEZ, MD, PhD^{2,3}

¹Oftalvist, Valencia, Spain; ²Fundación Oftalmología Médica, Valencia, Spain; ³Ophthalmology Department, University of Valencia, School of Medicine, Valencia, Spain