



Infectious disease

The first report of *Listeria monocytogenes* detected in pinnipeds

Johanna L. Baily ^{a, b}, Gavin K. Paterson ^c, Geoffrey Foster ^d, Nicholas J. Davison ^e,
Lineke Begeman ^f, Ailsa J. Hall ^g, Mark P. Dagleish ^{h, *}

^a Institute of Aquaculture, University of Stirling, Stirling FK9 4LA, Scotland, UK

^b Moredun Research Institute, Pentlands Science Park, Bush Loan, Penicuik, Midlothian EH26 0PZ, Scotland, UK

^c Royal (Dick) School of Veterinary Studies and the Roslin Institute, University of Edinburgh, Easter Bush Campus, Midlothian EH25 9RG, Scotland, UK

^d SRUC Veterinary Services, An Lochran, 10 Inverness Campus, Inverness IV2 5NA, Scotland, UK

^e Scottish Marine Animal Stranding Scheme, School of Biodiversity, One Health and Veterinary Medicine, University of Glasgow, Glasgow G12 8QQ, Scotland, UK

^f Department of Viroscience, Erasmus University Medical Centre, Wytemaweg 80, 3015 CN Rotterdam, the Netherlands

^g Sea Mammal Research Unit, Scottish Oceans Institute, University of St Andrews, St Andrews KY16 8LB, Scotland, UK

^h Department of Pathology, Public Health and Disease Investigation, School of Biodiversity, One Health and Veterinary Medicine, University of Glasgow, Jarrett Building, 464 Bearsden Road, Glasgow G61 1QH, Scotland, UK

ARTICLE INFO

Article history:

Received 22 September 2023

Accepted 14 December 2023

Keywords:

bacterial genome sequencing

neonatal mortality

seals

septicaemia

ABSTRACT

The aim of this study was to describe the pathology in seals from which *Listeria monocytogenes* was isolated and investigate if the lesions' nature and severity were related to the phylogeny of isolates. *L. monocytogenes* was isolated from 13 of 50 (26%) dead grey seal (*Halichoerus grypus*) pups, six (12%) in systemic distribution, on the Isle of May, Scotland. Similar fatal *L. monocytogenes*-associated infections were found in a grey seal pup from Carnoustie, Scotland, and a juvenile harbour seal (*Phoca vitulina*) in the Netherlands. Whole genome sequencing of 15 of the *L. monocytogenes* isolates identified 13 multilocus sequence types belonging to the *L. monocytogenes* lineages I and II, but with scant phenotypic and genotypic antimicrobial resistance and limited variation in virulence factors. The phylogenetic diversity present suggests there are multiple sources of *L. monocytogenes*, even for seal pups born in the same colony and breeding season. This is the first description of *L. monocytogenes* isolated from, and detected in lesions in, pinnipeds and indicates that infection can be systemic and fatal. Therefore, listeriosis may be an emerging or overlooked disease in seals with infection originating from contamination of the marine environment.

© 2023 The Authors. Published by Elsevier Ltd. This is an open access article under the CC BY license (<http://creativecommons.org/licenses/by/4.0/>).

1. Introduction

Listeria monocytogenes is a gram-positive bacillus, found widely in soil and freshwater, that can contaminate foodstuffs. In animal species and humans, infection with this bacterium has the potential to cause severe disease including sepsis, neurological disease and abortion [1]. Ingestion of contaminated food or soil is the most common source of exposure for humans and animals [2]. The bacterium is relatively widely distributed in aquatic food products (eg, shellfish, fish skin and lightly preserved seafood), most likely contaminated by agricultural or urban surface water run-off [3], although it remains to be determined if specific subtypes, so called

ecotypes, of *L. monocytogenes* are adapted to particular niches (eg, food, soil, water, animal hosts) [4].

Infection with *L. monocytogenes* in humans can occur by ingestion of aquatic food products and, therefore, marine mammals feeding on fish or shellfish would also be expected to be exposed to the bacterium. There are a few reports of *L. monocytogenes* in cetaceans but the routes of infection were not determined. A 6-year-old, captive, male killer whale (*Orcinus orca*) succumbed to meningoencephalitic listeriosis in Canada in 2004 [5]. An adult female striped dolphin (*Stenella coeruleoalba*) was found dead-stranded on the Italian Ligurian coast in 2015 and necropsy revealed *L. monocytogenes*, *Toxoplasma gondii* and *Brucella* spp co-infection in the brain associated with severe non-suppurative meningoencephalitis [6], but the contribution of each of these three known pathogens was unclear. There are also two records of isolation of *L. monocytogenes* from the lungs of cetaceans in the UK. The organism was recovered from the lung of a harbour porpoise

* Corresponding author.

E-mail address: Mark.Dagleish@Glasgow.ac.uk (M.P. Dagleish).

(*Phocoena phocoena*) found dead-stranded in Bude, Cornwall, UK, in February 1999. The cause of death was attributed to by-catch (the lungs were congested and chronic interstitial pneumonia with a moderate nematode burden was present) and isolation of *L. monocytogenes* was considered most likely incidental. *L. monocytogenes* was also recovered from lung and heart blood of a short-beaked common dolphin (*Delphinus delphis*) found dead-stranded at the Lizard, Cornwall, UK, in September 1996. The cause of death was attributed to severe diffuse pleuropneumonia of unspecified origin, but the finding of *L. monocytogenes* was deemed significant (both cases: UK Cetacean Strandings Investigation Programme, unpublished data). These cases indicate that *L. monocytogenes* infection can occur in both captive and free-ranging cetaceans of various species. However, there are no reports of *L. monocytogenes* having been recovered from, or causing disease in, pinnipeds.

In this study, fatal infection due to *L. monocytogenes* in grey seal (*Halichoerus grypus*) pups within a breeding colony, a single live-stranded grey seal pup remote from the breeding colony and a juvenile harbour seal (*Phoca vitulina*) at an entirely different location is described. The objectives of this study were to (1) describe the pathology associated with *L. monocytogenes* infection in seals, (2) determine the genetic diversity of *L. monocytogenes* isolates recovered, (3) using full genome analyses, identify potential virulence factors, and (4) by traditional microbiology, determine the antibacterial resistance profiles of the recovered *L. monocytogenes* isolates.

2. Materials and methods

2.1. Sample collection and processing

As part of a wider disease study [7,8], 50 grey seal pups that died during the 2011 pupping season (late October to early December) at various sites (Fig. 1) of the breeding colony on the Isle of May (IOM) in the Firth of Forth, Scotland, UK, were subjected to post-mortem

examination within 48 h of death. Samples of brain, lung, liver and spleen were collected and stored at -80°C before being processed for bacteriology using standard methods. All samples were cultured on Columbia blood agar (ThermoFisher Scientific, www.thermofisher.com) incubated at 37°C in air plus 5% CO_2 and MacConkey agar without salt (ThermoFisher Scientific) incubated aerobically at the same temperature. Selective culture for *Brucella* spp bacteria was also undertaken as described [9]. Suspect *L. monocytogenes* isolates were further characterized by catalase testing, the CAMP (Christie–Akins–Munch–Petersen) test with *Staphylococcus aureus* and *Rhodococcus equi* [10] and reactions with the API Coryne identification system (BioMérieux, www.biomerieux.co.uk). Samples for histology from each grey seal pup, including a minimum of 46 individual tissue samples from 34 organs [7], were fixed in 10% neutral buffered formalin, processed routinely through graded alcohols and embedded in paraffin wax prior to being sectioned ($4\ \mu\text{m}$) and stained with haematoxylin and eosin (HE) for examination by a board-certified veterinary pathologist (JLB). A cause of death was assigned to each animal following gross post-mortem examination, detailed histopathological examination, routine bacteriological examination and polymerase chain reaction (PCR) for targeted viral pathogens including herpesviruses [7,10].

Two additional *L. monocytogenes* isolates were obtained from European pinnipeds that were not part of the IOM study. The first isolate was from a female grey seal pup (M280/10, 12.8 kg), which live-stranded in Carnoustie, Angus, Scotland, UK (Fig. 1), and was admitted to a seal rehabilitation centre in Middlebank, Fife, Scotland, in Autumn 2010. On arrival, the pup presented with seizures and severe eye injuries and was euthanized on humane grounds. The second isolate was from a juvenile female harbour seal (PV150116, 28.8 kg) found dead in January 2015 on Zoutelande Beach, Zeeland, the Netherlands (Fig. 1). Gross post-mortem examination and histological examination were performed on both animals and bacteriology was performed on brain, lung, liver, spleen and mesenteric lymph node (M280/10) or lung and tracheobronchial lymph node (PV150116).

2.2. Immunohistochemistry

Immunohistochemistry (IHC) targeting *L. monocytogenes* was performed on sections of brain, lung, liver and spleen, dependent on histological lesions being present, of three animals from the IOM (CD002, CD035 and CD042). After dewaxing and rehydration through graded alcohols, antigen retrieval was performed using a solution of 0.1% trypsin and 0.1% calcium chloride in Tris HCl buffer (pH 7.8) for 50 min. Endogenous peroxidase activity was blocked by immersion in 3% H_2O_2 in methanol (vol/vol) for 20 min. Tissues were washed in running tap water for 5 min and then incubated in 25% normal goat serum (NGS) (Vector Laboratories, www.vectorlabs.com) in phosphate buffered saline (PBS) with 0.05% Tween 20 added (PBST) for 1 h at room temperature to block non-specific antibody binding. Immunolabelling was performed using rabbit monoclonal anti-*L. monocytogenes* antibody (BD Difco Listeria O Antisera, 223,021; BD, www.fishersci.com), diluted 1:4,000 in 25% NGS in PBST and incubated overnight at 4°C . Visualization of the primary antibody was by Envison Goat anti-rabbit HRP polymer (Vector Laboratories) using the chromogen Vector NovaRED (Vector Laboratories) as per the manufacturer's protocol. Slides were washed in running tap water, counterstained with haematoxylin, blued in Scott's tap water substitute, dehydrated through graded alcohols, cleared in xylene and mounted. Positive control material consisted of ovine cerebellum infected with *L. monocytogenes* with proven lesion-associated immunolabelling. Negative control preparations comprised semiserial tissue sections treated identically,

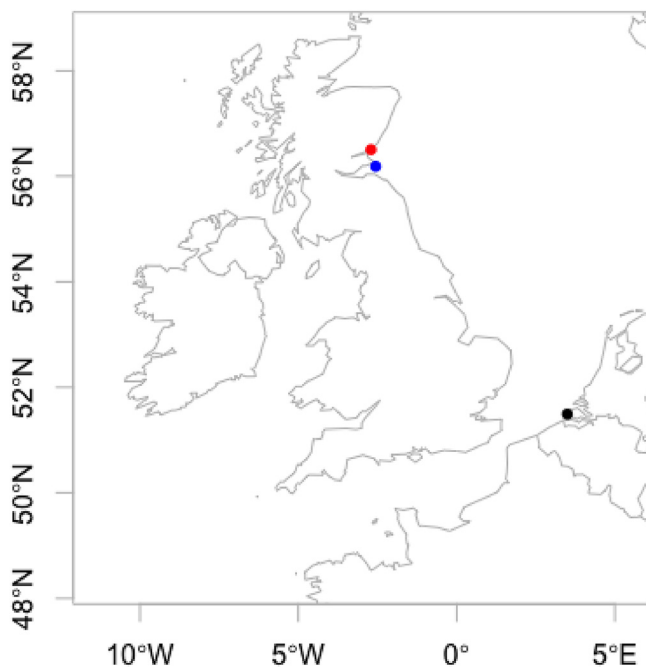


Fig. 1. Map of stranding locations of seals sampled for this study. Blue: free-ranging grey seal pups on the Isle of May, Scotland ($n = 50$). Red: stranded grey seal pup, Carnoustie, Scotland ($n = 1$). Black: stranded harbour seal juvenile, Zoutelande Beach, the Netherlands ($n = 1$).

except that the primary antibody was substituted with rabbit IgG purified from normal rabbit serum (Vector Laboratories).

2.3. Genome sequencing and analysis

Whole genome sequencing of recovered isolates of *L. monocytogenes* was performed by MicrobesNG (<https://microbesng.com>) as described [11]. Phylogenetic relationships were assessed using Ridom SeqSphere + version 6.0.0 [12] and the published *L. monocytogenes* core genome multilocus sequence type (cgMLST) scheme, version 2.1, consisting of 1,701 loci [13]. Calculation of allelic distances was performed in the mode 'pairwise ignore missing values' and the tree annotated using the Interactive Tree of Life [14]. The seven-gene multilocus sequence type (ST) and clonal complex were also derived by Ridom SeqSphere + version 6.0.0 from the genome sequences. Virulence factor genes were identified using MyDbFinder 2.0 (<https://cge.food.dtu.dk/services/MyDbFinder/>); thresholds were 85% for percentage identity and 80% for minimum length. The input database was taken from VirulenceFinder 2.0 (<https://cge.food.dtu.dk/services/VirulenceFinder/>) and supplemented with LIPI-3 genes *lIsAGHXBYDP* from *Listeria innocua* SLCC6294 (accession number KJ394488) taken from Virulence Factors of Pathogenic Bacteria (www.mgc.ac.cn/VFs/). The list of 100 virulence factor genes is provided in [Supplementary Table 1](#). Acquired antimicrobial resistance genes were identified using ResFinder-3.2 (<https://cge.food.dtu.dk/services/ResFinder/>) [15]; thresholds were 80% for percentage identity and 60% for minimum length.

2.4. Antimicrobial sensitivity testing

Sensitivity to benzylpenicillin, meropenem, erythromycin and trimethoprim-sulfamethoxazole was investigated according to EUCAST Disk Diffusion Test Methodology (v 8.0 January 2020).

2.5. Statistical analyses

Data were analysed using the R statistical software package (R Core Team 2013) and statistical significance was set at $P \leq 0.05$. For prevalence data Fisher's exact test (FET) was performed. Odds ratios (OR) were calculated using a generalized linear model with a binomial family and a logit link function. Presence/absence of select lesions or other pathogens was used as a fixed explanatory factor.

3. Results

The precise locations, dates of sampling, key pathological findings, causes of death and other critical data for all 15 seals from which *L. monocytogenes* was recovered are presented in [Supplementary Table 2](#).

3.1. Grey seal pups on the Isle of May, Scotland

L. monocytogenes was cultured from 13 of the 50 dead grey seal pups (26%) examined on the IOM in 2011, predominantly from the liver (9/13) and spleen (9/13) and less frequently from lung (4/13) and brain (1/13). Six of these pups (CD002, CD020, CD031, CD035, CD041 and CD042) had systemic *Listeria* infection as denoted by bacterial recovery from two or more tissues ([Supplementary Table 2](#)). In one case (CD042), *L. monocytogenes* was the only bacterium isolated and was recovered from all four organs cultured (brain, lung, liver and spleen). Coinfections with other known bacterial pathogens were observed frequently and included *Streptococcus halichoeri* subsp *halichoeri*, *Streptococcus phocae*, *Arcanobacterium phocae*, *Salmonella typhimurium*, *Salmonella Bovismorbificans* and *Erysipelothrix rhusiopathiae* ([Supplementary Table 2](#)).

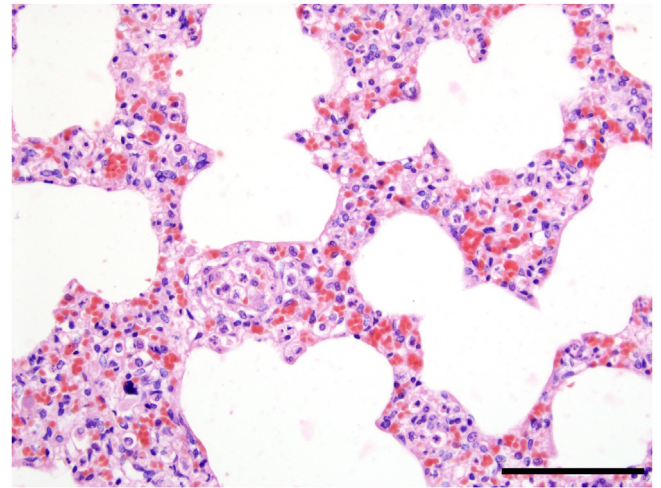


Fig. 2. Interstitial pneumonia, lung, seal pup CD042. Alveolar walls expanded by neutrophils, macrophages and fewer lymphocytes associated with moderate diffuse congestion. HE. Bar, 100 μ m.

IHC was successful on the tissues of all three seals examined (results described below). All negative control preparations were devoid of any immunolabelling and positive control sections showed specific positive labelling in the expected distribution.

3.2. Pathology

Of the 13 grey seal pups on the IOM from which *L. monocytogenes* was recovered, seven (53.8%) had substantial lung pathology ranging from suppurative to fibrinosuppurative pleuritis to broncho-interstitial pneumonia ([Fig. 2](#), CD042), and these lesions were present in four (CD031, CD035, CD041 and CD042) of six of the pups with a systemic distribution of *L. monocytogenes*. Small clusters of *L. monocytogenes* bacteria were localized within alveolar walls in the two animals with lung lesions that were subjected to IHC (CD035 and CD042). A further four pups had oedema of the alveolar septa.

Ten of the 13 (76.9%) pups had either suppurative or necrotizing hepatitis ([Fig. 3](#)) or a combination of both ([Supplementary Table 2](#)). This change was present in all six pups that had systemic *L. monocytogenes*. In five cases the distribution was multifocal and random, typical of haematogenous spread. *L. monocytogenes* was localized within foci of hepatic necrosis in two (CD002 and CD042) of three liver sections subjected to IHC ([Fig. 4](#)).

Seal CD035 had mild, multifocal suppurative splenitis and seal CD042 had mild, multifocal, chronic–active vasculitis in this organ. IHC revealed a single small cluster of immunolabelled *L. monocytogenes* within an aggregate of neutrophils in the spleen of seal CD042.

Five of the six seals that had systemic *L. monocytogenes* infection had suppurative to granulomatous encephalitis or meningoencephalitis ([Fig. 5A](#) and [B](#)). Seal CD042, from which *L. monocytogenes* was isolated from the brain, had granulomatous encephalitis with vasculitis, type II astrocytes and gitter cells. One of the remaining seven pups (CD051) had granulomatous meningoencephalitis. No immunolabelling was present within the brain sections subjected to IHC (0/2 seals). In total, 4/13 (30.7%) and 5/13 (38.4%) pups had encephalitis or meningitis, respectively, compared with 8/37 (21.6%) and 11/37 (29.7%) seals from which *L. monocytogenes* was not isolated.

3.3. Additional findings

Umbilical infection was a common finding (8/13 seals) and was often associated with peritonitis and hepatitis ([Fig. 6](#)). Gross and

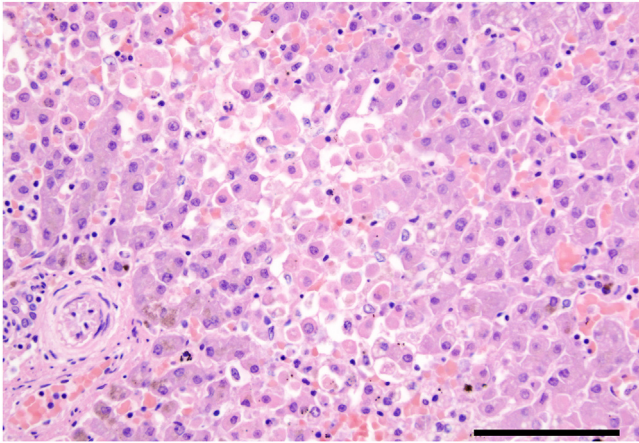


Fig. 3. Necrotizing hepatitis, liver, seal pup. Poorly demarcated focus of necrotic hepatocytes with dissociation, hypereosinophilia, steatosis, pyknosis and karyorrhexis. Haemosiderin (brown) pigment in periportal hepatocytes normal in neonatal pinnipeds. HE. Bar, 100 μ m.

histological examinations revealed a wide range of other changes including emaciation, infection with phocid alphaherpesvirus 1 (PhHV-1), confirmed by specific PCR [10], thymic atrophy and septicaemia from agents other than *L. monocytogenes*. The presence of *L. monocytogenes* was significantly more common in pups with mild to severe thymic atrophy ($P = 0.049$, FET; OR = 5.19, $P = 0.029$) than in pups with no or minimal thymic atrophy. Despite being isolated more frequently in affected animals, there was no statistical relationship between the presence of *L. monocytogenes* and umbilical infection (OR = 1.22, $P = 0.764$), histological evidence of peritonitis (OR = 2.67, $P = 0.147$) or hepatic necrosis (OR = 2.27, $P = 0.228$) compared with pups without these lesions. There was no significant relationship with the PhHV-1 infection status of pups when compared with seals from which *L. monocytogenes* was not isolated (FET, $P = 0.51$) (full data presented in Baily [7]).

3.4. Seals remote from the Isle of May

Necropsy of the grey seal pup found live-stranded in Carnoustie, Angus, Scotland, in October 2010 (M280/10) and euthanized subsequently revealed suppurative omphalitis and moderate diffuse

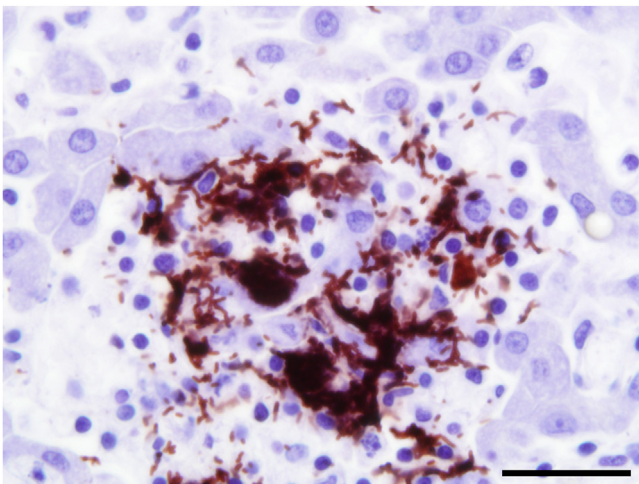


Fig. 4. Intense immunolabelling of *Listeria monocytogenes* within focus of hepatic necrosis and chronic-active inflammation. IHC. Bar, 20 μ m.

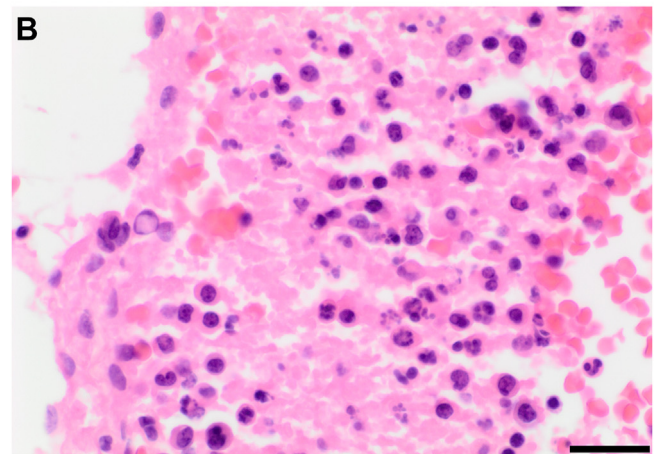
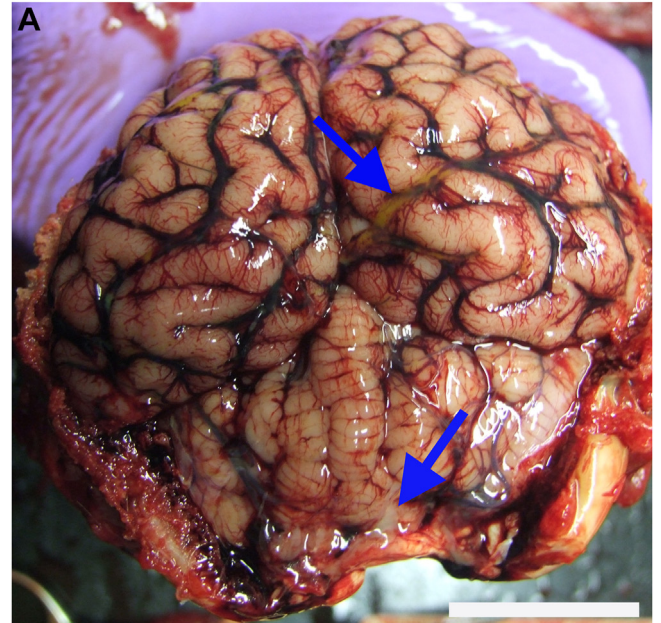


Fig. 5. Listerial suppurative meningitis, meninges, seal pup CD042. (A) Pus present (arrows). Bar, 3 cm. (B) Degenerate and non-degenerate neutrophils. HE. Bar, 20 μ m.

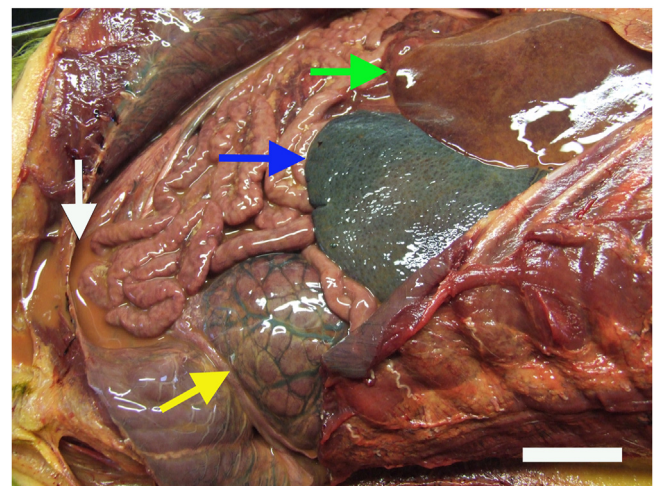


Fig. 6. Septicaemic listeriosis, seal pup CD042. (*L. monocytogenes* isolated from liver, lung, spleen and brain). Peritonitis with suppurative peritoneal effusion (white arrow), suppurative hepatitis (green arrow), perirenal oedema (yellow arrow) and splenomegaly (blue arrow). Bar, 4 cm.

congestion of the whole carcass. Skin ulcers were present over the ventral neck, periocular regions and flippers along with multiple mucosal ulcers of the lips and tongue and a severe focal corneal ulcer (descemetocoele) with conjunctivitis of the left eye. *L. monocytogenes* was isolated from the brain, lungs, liver, spleen and mesenteric lymph nodes. *S. phocae* was also isolated from the brain, lung and spleen of this animal and histopathology was consistent with septicaemia secondary to omphalitis.

Necropsy of the juvenile harbour seal found dead on Zoutelande Beach, Zeeland, the Netherlands (PV150116), revealed large necropurulent foci throughout the lungs, tracheobronchial and mesenteric lymph nodes, liver and adrenal glands consistent with disseminated embolic bacterial infection. The lungs also had hyperaemia, emphysema and atelectasis and heavy growths of *L. monocytogenes* and *Klebsiella pneumoniae* were recovered from the lungs and tracheobronchial lymph nodes. In addition, a heavy growth of *Citrobacter* sp was cultured from lungs only.

3.5. Whole genome sequencing – molecular typing and phylogenetic relationships

The *L. monocytogenes* isolates recovered from the 15 different seals belonged to 11 multilocus sequence types, with each ST belonging to a different clonal complex. Three sequence types (ST8, ST391 and ST403) were found in multiple isolates (Fig. 7, Supplementary Table 2). Based on MLST, 13 isolates belonged to lineage II with only two, CD0351 (from seal CD035) and PV150116, belonging to lineage I. In agreement with the variety of sequence types present among the isolates, the cgMLST phylogeny showed a diverse population of isolates present among the pinniped collection (Fig. 7). The most frequent sequence type was ST8, isolated from three seal pups on the IOM (Supplementary Table 2). ST403 and ST391 were each detected in two seals. The mean pairwise allelic difference between isolates was 1,308 alleles for all 15 isolates, and for those from the IOM only was 1,250 alleles. Despite this population diversity, there were three examples of highly related isolates in different individuals. The two ST391 isolates, CD0292 (seal CD029) and CD0311 (seal CD031), could not be distinguished by cgMLST. Isolates CD0202 (seal CD020) and CD0421 (seal CD042), both ST403, were separated by 14 allelic differences and the mean pairwise difference between the three ST8 isolates from CD0024 (seal CD002), CD0252 (seal CD025) and CD0412 (seal CD041) was four alleles. NCBI accessions for the sequencing reads and assemblies are provided in Supplementary Table 3.

3.6. Distribution of virulence factor genes

A screen of 100 *L. monocytogenes* genes of known and putative virulence factors found limited variation in the presence or absence of these genes among the 15 isolates from the seal pups (Supplementary Table 1), with most genes being present in most isolates. The majority of virulence factor genes (81/100) were present in all isolates, although no isolate encoded all of the 100 known and putative virulence factor genes examined. Ubiquitous genes included those encoding key virulence factors such as listeriolysin O (*hyl*), internalin A and B (*intA*, *intB*), LIP-1 (*prfA*, *hly*, *mpl*, *iap*, *plcB*, *plcC* and *actA*) and fibronectin-binding protein A (*fbpA*). The virulence factor genes with the most limited distribution were the eight *lls* genes belonging to LIPI-3 (encoding listeriolysin S), which were present in a single isolate (PV150116). Only two other virulence factor genes were absent in the majority of isolates: *Vip*, which encodes a LPXTG-motif cell wall anchored protein involved in host cell invasion [16,17] (absent in 11 isolates), and *gadA*, which encodes a glutamate decarboxylase [18] (absent in eight isolates).

3.7. Analysis of phenotypic and genotypic antimicrobial resistance

All 15 isolates were sensitive to benzylpenicillin, meropenem, erythromycin and trimethoprim-sulphamethoxazole by disc diffusion. The fosfomycin resistance determinate *fosX* was present in all isolates but no other acquired resistance genes were present.

4. Discussion

To the authors' knowledge, this paper represents the first description of *L. monocytogenes* detected in pinnipeds. The high frequency of necrotizing to suppurative hepatitis (10/15 seals) and fibrinosuppurative pleuritis or pneumonia (8/15 seals) suggests that these two pathologies may be characteristic of *L. monocytogenes* infection in seals. Notably, specific intralesional immunolabelling is strong supportive evidence that this pathogen is the cause of some of the lesions in the grey seal pups. Although ingestion of contaminated food or soil is the most common source of exposure for humans and animals [2], given the frequent association with umbilical infection (9/15), *L. monocytogenes* is likely to be an opportunistic pathogen present in the environment benefitting from any breach in the integrity of the abdominal wall to cause aggressive disease in seal pups. Immunosuppression predisposes to development of clinical disease in many cases of listeriosis in land animals [1], which may also

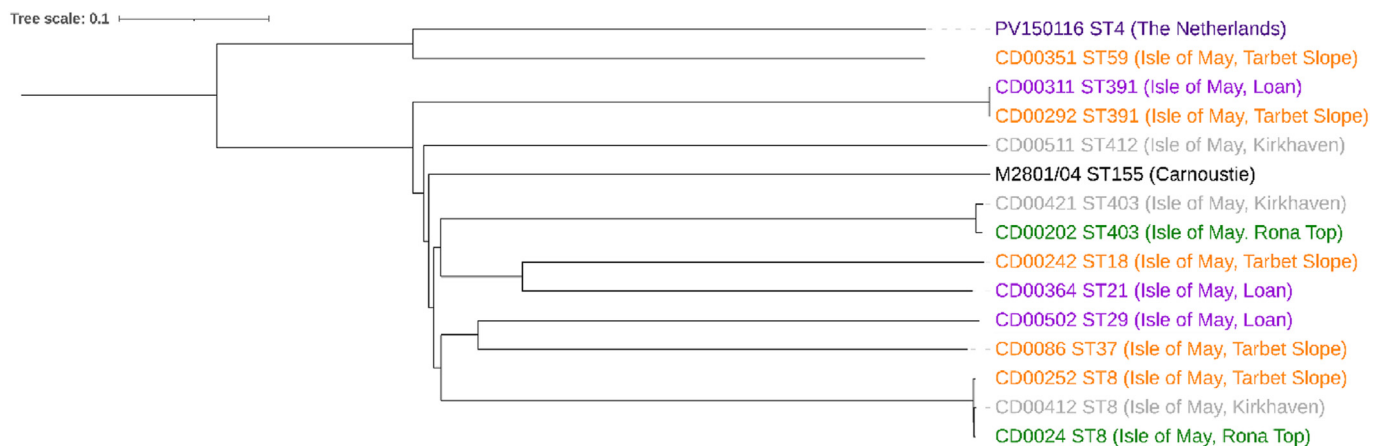


Fig. 7. Phylogenetic relationships among *L. monocytogenes* isolates from European pinnipeds. Neighbour-joining phylogeny generated using the *L. monocytogenes* cgMLST scheme of 1,701 loci. ST refers to multilocus sequence type. Geographical location given in brackets and reflected in text colour. **Note:** isolate references are derivatives of seal reference name (see Supplementary Table 2 for details).

be a factor in young seal pups as their immune system will still be immature [19].

Meningitis or encephalitis was found frequently in infected seals (6/13 seals) but as the prevalence was comparable to that seen in other pups not infected with *L. monocytogenes* its significance is doubtful. The failure to isolate *L. monocytogenes* from, or localize it by IHC in, brain tissue from most of the animals affected may suggest that seal pups develop a visceral form of the disease. Systemic listeriosis is more common in monogastric and neonatal animals, in which septicaemia with multifocal to diffuse hepatic and splenic necrosis, but without brain involvement, has been reported as the most frequent presentation [2].

No dominant sequence type or clonal complex was present in this study but rather a mix of sequence types within *L. monocytogenes* lineages I and II. This indicates exposure to a wide diversity of *L. monocytogenes* isolates, probably from a variety of sources or sources that themselves are comprised of diverse *L. monocytogenes* lineages. Whether these isolates reflect an adaptation to the marine environment is unclear. Among the more frequent STs, ST8, isolated from three seals on the IOM, has been found to be predominant in aquatic products in China [20]. ST403, which had clear septicaemic distribution in pup CD042 and inconclusive pathology in pup CD020, is a poorly known ST but was associated with a large outbreak of listeriosis in humans in Austria, Germany and the Czech Republic in 2009/2010 due to consumption of a traditional Austrian Quargel cheese [21]. However, ST391, detected in two seals, has been associated with human disease due to consumption of smoked fish in Denmark [22]. The presence of some highly related isolates is evidence of a closely linked transmission network and may indicate possible seal-to-seal transmission or, possibly more likely, infection from a common source, as infected cases ST391 and ST403 were >800 m distant from each other. Similarly, the three isolates of ST8 were from seal pups in three different locations on the IOM, so it is perhaps premature to speculate given the small geographical area studied.

L. monocytogenes has a high tolerance to moderate salinity, can be found in seawater, presumed due to run-off from the land, and is frequently isolated from seafood [3]. It is predominantly isolated from fish skin and viscera, fresh shrimp and shellfish but the associated human health risk is low due to the tendency to cook such foods [3]. As expected, ready-to-eat and lightly preserved fish and shellfish have a higher prevalence but total bacterial counts tend to be low [3]. Prevalence studies in Mexico's coastal ecosystems found *L. monocytogenes* in 4.5% of fish and 8.3% of estuarine water samples, but not in oysters [23]. However, in Egypt, 13% of coastal waters, 17.3% of fresh fish and 33% of shellfish were contaminated [24]. Therefore, there is likely to be a constant, if low level, exposure of coastal marine mammals to *L. monocytogenes* and this may be greater if intensive farming or other, yet unrecognized, land management practices occur upstream of estuarine rivers.

The limited variation in key virulence genes, despite the large number, in the *L. monocytogenes* isolates in this study suggests all are potentially pathogenic to their pinniped and human hosts. The presence of the eight *l* genes belonging to LIPI-3 (encoding the additional pathogenicity island listeriolysin S) in a single isolate, PV150116, is typical of a subset of lineage I isolates of *L. monocytogenes* [25]. This was isolated from the harbour seal in the Netherlands, whereas the other isolate of lineage I (ST59, CD0351), found on the IOM, does not possess this pathogenicity island, possibly reflecting differences in geographical location or host species.

The relative lack of antimicrobial resistance was noteworthy and reassuring given the emergence of resistant and multidrug resistant strains of *L. monocytogenes* in many different ecosystems over the past decades [26]. Only the fosfomycin resistance determinate *fosX* was present, which is an almost ubiquitous finding in

L. monocytogenes isolates [26]. It is important to note that all isolates in our study were distinct from the sheep pathogen *Listeria ivanovii*, a less common and less virulent pathogen of sheep [27], which is distinguished readily from *L. monocytogenes* and all other *Listeria* spp by the CAMP test [28]. However, *L. ivanovii* was reported in harbour seals in 1998 after being isolated, primarily, from umbilical abscesses but also associated with a range of other lesions including meningitis, pneumonia and septicaemia [29].

The present study raises questions as to the origins of the bacteria in these animals. Plausible explanations include agricultural run-off, untreated sewage, maternal exposure to contaminated fish skin, fish faecal content or shellfish consumed as part of the normal diet, or exposure to isolates within the cool, damp sediment in the pools present on the IOM, possibly due to faecal contamination from the many seabirds that visit and nest there; however, further studies are required to confirm these possibilities. Nevertheless, the isolation of *L. monocytogenes* in such a high proportion of grey seal pups raises concerns of zoonotic disease risk to humans in contact with carcasses of grey seal pups. Furthermore, despite the completely unknown prevalence and significance of this pathogen in adult grey seal populations, it is tempting to speculate that it may induce disease in older, immunosuppressed individuals or possibly act as an abortifacient agent as in other species [30]. The potential for long distance transmission of *L. monocytogenes* from areas of high human activity to pristine locations by these highly migratory seal species also remains to be determined.

5. Conclusion

The lack of historical reports in pinniped species could suggest that *L. monocytogenes* represents an emerging or overlooked infection in seals, originating from microbial contamination of the marine environment. Indeed, the prevalence of listeriosis in farm animals has increased dramatically since the advent of feeding ensiled fodder, especially grass [31], and emerging diseases in wildlife species are frequently a result of increased overlap in human–wildlife habitats and changes in human activity [32]. This work supports previous studies [33,34] suggesting that assessing coastal ecosystem health should include targeted studies of specific marine mammals species with appropriate life histories that render them useful as sentinels.

Funding

This work and JLB's PhD studentship were funded by the Moruden Research Institute and the Royal Zoological Society of Scotland. The necropsy of the grey seal from Carnoustie, Angus, was funded by Marine Scotland, a division of the Scottish Government. Genome sequencing was provided by MicrobesNG (<http://www.microbesng.com>), which is supported by the UK Biotechnology and Biological Sciences Research Council (grant number BB/L024209/1).

Statement of author contributions

J.L. Bailey: Performed all grey seal necropsies; Preliminary bacteriology; Histological examination of tissue sections; Statistical analyses; Original draft. **G.K. Paterson:** Supervised and performed molecular analyses and phylogeny of *L. monocytogenes* isolates. **G. Foster:** Supervised and performed significant aspects of bacteriology. **N.J. Davison:** Supervised and performed significant aspects of bacteriology. **L. Begeman:** Undertook all work relating to juvenile harbour seal. **A.J. Hall:** Conception and design of project; Supervision. **M.P. Dagleish:** Conception and design of project; Supervision; Reviewing and editing. All authors have reviewed and edited the manuscript.

Acknowledgments

We thank the Sea Mammal Research Unit at the University of St. Andrews for assistance with field sampling (Simon Moss, Matt Bivins, Kelly Robinson, Paula Redman, Chris McKnight and Amanda Stansbury), the Scottish SPCA National Wildlife Rescue Centre (Colin Seddon and staff), Jaap van der Hiele of A Seal, Stellendam, and Clare Underwood, Jeanie Finlayson and Val Forbes of the Moredun Research Institute Pathology Department and Peter van Run of Viroscience EMC for excellent histopathological and immunohistochemical preparations.

Declaration of competing interests

The authors declared no conflicts of interest in relation to the research, authorship or publication of this article.

Appendix A. Supplementary data

Supplementary data to this article can be found online at <https://doi.org/10.1016/j.jcpa.2023.12.003>.

References

- Haase JK, Didelot X, Lecuit M, Korkeala H, Achtman M. The ubiquitous nature of *Listeria monocytogenes* clones: a large-scale Multilocus Sequence Typing study. *Environ Microbiol* 2014;16:405–16.
- Walker RL. *Listeria*. In: Hirsh DC, MacLachlan NJ, Walker RL, editors. *Veterinary microbiology*. Oxford: Blackwell Publishing; 2004. p. 185–9.
- Jami M, Ghanbari M, Zunabovic M, Domig KJ, Kneifel W. *Listeria monocytogenes* in aquatic food products – a review. *Compr Rev Food Sci Food Saf* 2014;13:798–813.
- Vivant AL, Garmyn D, Piveteau P. *Listeria monocytogenes*, a down-to-earth pathogen. *Front Cell Infect Microbiol* 2013;4:1–10.
- Mergl J, Slavic D, Martineau D, Choczynski SM. Fatal *Listeria monocytogenes* infection in a killer whale (*Orcinus orca*). *IAAAM Archive* 2006:7868. <https://www.vin.com/doc/?id=3865267>.
- Grattarola C, Giorda F, Iulini B, Pintore MD, Pautasso A, Zoppi S, et al. Meningoencephalitis and *Listeria monocytogenes*, *Toxoplasma gondii* and *Brucella* spp. coinfection in a dolphin in Italy. *Dis Aquat Organ* 2016;118(2):169–74. <https://doi.org/10.3354/dao02957>.
- Baily JL. The pathology and occurrence of pathogens in Scottish grey seals (*Halichoerus grypus*). PhD thesis. University of St. Andrews; 2014.
- Baily JL, Foster G, Brown D, Davison NJ, Coia JE, Watson E, et al. *Salmonella* infection in grey seals (*Halichoerus grypus*), a marine mammal sentinel species: pathogenicity and molecular typing of *Salmonella* strains compared with human and livestock isolates. *Environ Microbiol* 2016;18:1078–87.
- Foster G, MacMillan AP, Godfroid J, Howie F, Ross HM, Cloeckaert A, et al. A review of *Brucella* sp. infection of sea mammals with particular emphasis on isolates from Scotland. *Vet Microbiol* 2002;90:563–80. [https://doi.org/10.1016/S0378-1135\(02\)00236-5](https://doi.org/10.1016/S0378-1135(02)00236-5).
- Baily JL, Willoughby K, Maley M, Chapman J, Pizzi R, Hall AJ, et al. Widespread neonatal infection with phocid herpesvirus 1 in free-ranging and stranded grey seals (*Halichoerus grypus*). *Dis Aquat Organ* 2019;133(3):181–7. <https://doi.org/10.3354/dao03345>.
- MacFadyen AC, Fisher EA, Costa B, Cullen C, Paterson GK. Genome analysis of methicillin resistance in *Macrococcus caseolyticus* from dairy cattle in England and Wales. *Microb Genom* 2018;4(8):e000191. <https://doi.org/10.1099/mgen.0.000191>.
- Jünemann S, Sedlazeck FJ, Prior K, Albersmeier A, John U, Kalinowski J, et al. Updating benchtop sequencing performance comparison. *Nat Biotechnol* 2013;31:294–6. <https://doi.org/10.1038/nbt.2522>.
- Ruppitsch W, Pietzka A, Prior K, Bletz S, Fernandez HL, Allerberger F, et al. Defining and evaluating a core genome multilocus sequence typing scheme for whole-genome sequence-based typing of *Listeria monocytogenes*. *J Clin Microbiol* 2015;53:2869–76. <https://doi.org/10.1128/JCM.01193-15>.
- Letunic I, Bork P. Interactive Tree of Life (iTOL) v4: recent updates and new developments. *Nucleic Acids Res* 2019;47:W256–9.
- Zankari E, Hasman H, Cosentino S, Vestergaard M, Rasmussen S, Lund O, et al. Identification of acquired antimicrobial resistance genes. *J Antimicrob Chemother* 2012;67:2640–4. <https://doi.org/10.1093/jac/dks261>.
- Cabanes D, Sousa S, Cebriá A, Lecuit M, García-del Portillo F, Cossart P. Gp96 is a receptor for a novel *Listeria monocytogenes* virulence factor, Vip, a surface protein. *EMBO J* 2005;24:2827–38.
- Martins M, Custódio R, Camejo A, Almeida MT, Cabanes D, Sousa S. *Listeria monocytogenes* triggers the cell surface expression of Gp96 protein and interacts with its N terminus to support cellular infection. *J Biol Chem* 2012;287:43083–93.
- Cotter PD, Gahan CG, Hill C. A glutamate decarboxylase system protects *Listeria monocytogenes* in gastric fluid. *Mol Microbiol* 2001;40:465–75.
- Hall AJ, McConnell BJ, Barker RJ. The effect of total immunoglobulin levels, mass and condition on the first-year survival of grey seal pups. *Funct Ecol* 2002;16:462–74.
- Chen M, Cheng J, Wu Q, Zhang J, Chen Y, Xue L, et al. Occurrence, antibiotic resistance, and population diversity of *Listeria monocytogenes* isolated from fresh aquatic products in China. *Front Microbiol* 2018;9:2215. <https://doi.org/10.3389/fmicb.2018.02215>.
- Rychlii K, Müller A, Zaiser A, Schoder D, Allerberger F, Wagner M, et al. Genome sequencing of *Listeria monocytogenes* “Quargel” listeriosis outbreak strains reveals two different strains with distinct in vitro virulence potential. *PLoS One* 2014;9:e89964.
- Gillesberg Lassen S, Ethelberg S, Björkman JT, Jensen T, Sørensen G, Kvistholm Jensen A, et al. Two listeria outbreaks caused by smoked fish consumption – using whole-genome sequencing for outbreak investigations. *Clin Microbiol Infect* 2016;22:620–4. <https://doi.org/10.1016/j.cmi.2016.04.017>.
- Rodas-Suárez OR, Flores-Pedroche JF, Betancourt-Rule JM, Quiñones-Ramírez EI, Vázquez-Salinas C. Occurrence and antibiotic sensitivity of *Listeria monocytogenes* strains isolated from oysters, fish, and estuarine water. *Appl Environ Microbiol* 2006;72:7410–2.
- El-Shenawy MA, El-Shenawy MA. *Listeria* spp. in the coastal environment of the Aqaba Gulf, Suez Gulf and the Red Sea. *Epidemiol Infect* 2006;134:752–7.
- Clayton EM, Daly KM, Guinane CM, Hill C, Cotter PD, Ross PR. Atypical *Listeria innocua* strains possess an intact LIPI-3. *BMC Microbiol* 2014;14:58.
- Olaimat AN, Al-Holy MA, Shahbaz HM, Al-Nabulsi AA, Abu Ghoush MH, Osaili TM, et al. Emergence of antibiotic resistance in *Listeria monocytogenes* isolated from food products: a comprehensive review. *Compr Rev Food Sci Food Saf* 2018;17:1277–92. <https://doi.org/10.1111/1541-4337.12387>.
- Radostits OM, Gay CC, Blood DC, Hinchcliff KW. *Diseases caused by bacteria*. In: *Veterinary medicine: a textbook of the diseases of cattle, sheep, pigs, goats and horses*. 9th ed. London: WB Saunders Company Ltd; 2000. p. 736–41.
- Seeliger HPR, Jones D. Genus *Listeria* Pirie, 1940, 383AL. In: Sneath PHA, Nair NS, Sharpe ME, Holt JG, editors. *Bergey's manual of systematic bacteriology*, vol 2. Baltimore: Williams and Wilkins; 1986. p. 1235–45.
- Thornton SM, Nolan S, Gulland FM. Bacterial isolates from California sea lions (*Zalophus californianus*), harbor seals (*Phoca vitulina*), and northern elephant seals (*Mirounga angustirostris*) admitted to a rehabilitation center along the central California coast, 1994–1995. *J Zoo Wildl Med* 1998;29:171–6.
- Hirsch DC. Family Enterobacteriaceae. In: *Veterinary microbiology*. Oxford: Blackwell Publishing; 2004. p. 57–60.
- Wilesmith JW, Gitter M. Epidemiology of ovine listeriosis in Great Britain. *Vet Rec* 1986;119:467–70.
- Gortazar C, Reperant LA, Kuiken T, de la Fuente J, Boadella M, Martínez-Lopez B, et al. Crossing the interspecies barrier: opening the door to zoonotic pathogens. *PLoS Pathog* 2014;10:e1004129. <https://doi.org/10.1371/journal.ppat.1004129>.
- Bossart GD. Marine mammals as sentinel species for oceans and human health. *Vet Pathol* 2011;48:676–90.
- Baily JL, Meric G, Bayliss S, Foster G, Moss SE, Watson E, et al. Evidence of land–sea transfer of the zoonotic pathogen *Campylobacter* to a wildlife marine sentinel species. *Mol Ecol* 2015;24:208–21.