

TO THE EDITOR:

Efficacy and safety of daratumumab in pure red cell aplasia after allogeneic transplantation: Dutch real-world data

Flores Weverling,¹ Mieke Roeven,² Clara Nijssen,¹ Annoek E. C. Broers,³ Elisabeth Dovern,⁴ Anna van Rhenen,¹ Geerte van Sluis,⁵ Carin L. E. Hazenberg,⁶ Peter van Balen,⁷ Maria T. Kuipers,⁴ Karen M. K. de Vooght,⁸ Linde Morsink,⁶ Jürgen Kuball,¹ Erfan Nur,⁴ and Moniek A. de Witte¹

¹Department of Hematology, University Medical Center Utrecht, Utrecht, The Netherlands; ²Department of Hematology, Radboud University Medical Center; Nijmegen, The Netherlands; ³Department of Hematology, Erasmus MC Cancer Institute, Rotterdam, The Netherlands; ⁴Department of Hematology, Amsterdam University Medical Center, Amsterdam, The Netherlands; ⁵Department of Hematology, Isala Hospital, Zwolle, The Netherlands; ⁶Department of Hematology, University Medical Center Groningen, Groningen, The Netherlands; ⁷Department of Hematology, Leiden University Medical Center, Leiden, The Netherlands; and ⁸Central Diagnostic Laboratory, University Medical Center Utrecht, Utrecht, The Netherlands

Pure red cell aplasia (PRCA) is a potential long-lasting and devastating complication after allogeneic hematopoietic stem cell transplantation (allo-SCT), with significant morbidity. Patients who underwent transplantation with major ABO-incompatible stem cell grafts can develop PRCA because of antidonor AB isohemagglutinins (IsoHGs). Approximately 25% of patients receive a major ABO-mismatched allograft,¹ of which up to 50% of patients develop PRCA.²⁻⁴ With >25 000 allo-SCTs reported annually by the European Society for Blood and Marrow Transplantation and the Center for International Blood and Marrow Transplant Research,^{5,6} it is evident that hundreds of patients undergoing transplantation must suffer from PRCA each year.

Although multiple strategies to eradicate persisting donor-specific IsoHGs (such as rituximab, bortezomib, and donor lymphocyte infusion [DLI]) have been applied, the evidence for the efficacy of these interventions remains inconclusive.^{3,7,8} Recently, daratumumab has been explored as a treatment for PRCA, with the hypothesis that residual plasma cells of the recipient producing antidonor A or B IsoHGs are CD38 positive and that treatment with daratumumab will deplete these residual plasma cells. In 2018, successful treatment of refractory PRCA with the anti-CD38 monoclonal antibody daratumumab was described for the first time.⁹ Since then, 9 additional cases have been reported,¹⁰ which unanimously showed swift resolution of PRCA after 2 to 4 courses of daratumumab.

To overcome reporting bias through individual case reports, we identified in our “real-world” all patients (n = 14) with posttransplant PRCA treated with daratumumab within 7 Dutch bone marrow transplant centers from 2020 to 2023 (Table 1). Most patients had anti-A antibodies (86%) with IsoHG titers ranging from 1:4 to 1:1024 (supplemental Table 2) and all patients required erythrocyte support. Previously administered therapies consisted of rituximab (43%), DLI (29%), and bortezomib (7%), all of which were unsuccessful. The start of daratumumab (1800 mg s.c. per administration) was heterogeneous (range, day 60 to day 2898 after transplantation), as daratumumab is currently neither registered as a treatment for PRCA nor part of the (inter)national treatment guidelines. Successful treatment of PRCA was defined as the development of reticulocytosis and was achieved in 13 of 14 patients (93%, median time 14 days; Table 1). Patients received either a fixed number of daratumumab administrations (n = 7) or the treatment was stopped after the development of reticulocytosis (n = 6). Therefore, the median number of daratumumab administrations after which reticulocytosis developed was 2 (range 1-5), but the median number of total daratumumab administrations was higher (median 4, range 1-6) (supplemental Figure 1). In all patients, ABO-titers were normalized (Figure 1, supplemental Figure 1). In 2 patients (numbers 2 and 3) ABO-titers and reticulocyte numbers were evaluated at each

Submitted 11 July 2023; accepted 30 November 2023; prepublished online on *Blood Advances* First Edition 17 January 2024; final version published online 28 March 2024. <https://doi.org/10.1182/bloodadvances.2023011190>.

Data will be available upon reasonable request from the corresponding author, Moniek de Witte (m.a.dewitte@umcutrecht.nl).

The full-text version of this article contains a data supplement.

© 2024 by The American Society of Hematology. Licensed under [Creative Commons Attribution-NonCommercial-NoDerivatives 4.0 International \(CC BY-NC-ND 4.0\)](https://creativecommons.org/licenses/by-nc-nd/4.0/), permitting only noncommercial, nonderivative use with attribution. All other rights reserved.

Table 1. Details of 14 cases of patients with PRCA treated with daratumumab in the Netherlands

No.	Age	Sex	Underlying disease	Donor type and match grade	Stem cell source	Conditioning intensity*	ABO-titer† before treatment	Donor chimerism	Prior treatment	Start daratumumab after SCT (d)	Total number of doses given (7 day interval)‡	Number of doses given at reticulocytosis§	Iso-hemagglutinin disappeared	Reported side-effects	Ongoing response (d)
1	63	M	AML	MUD 10/10	Peripheral blood	MAC	1:16 Anti-A	T 100% nT 100%	Rituximab + DLI	108	2	2	Yes	None reported	405
2	56	M	MDS	MUD 10/10	Peripheral blood	MAC	1:128 Anti-A	T 98% nT 96%	Steroids + Rituximab	140	5‡	5	Yes	PML (death)	191
3	63	M	PMF	MUD 9/10	Peripheral blood	MAC	1:32 Anti-B	T 100% nT 100%	Rituximab + DLI	121	2‡	2	Yes	None reported	294
4	28	M	Sickle cell disease	SIB 10/10	Peripheral blood	NMA	1:32 Anti-B	T 69% nT 100%	Rituximab	60	4	3	Yes	None reported	456
5	61	F	AML	MUD 10/10	Peripheral blood	MAC	1:512 Anti-A	Whole blood 100%	None	210	2	2	Yes	None reported	383
6	60	F	AML	MUD 10/10	Peripheral blood	MAC	1:64 Anti-A	Whole blood >95%	Rituximab	460	6	4	Yes	None reported	1045
7	55	M	AML	MUD 10/10	Peripheral blood	RIC	1:512 Anti-A	Whole blood >95%	Rituximab + DLI + BOR	2898	4	2	Yes	None reported	957
8	45	F	AML	MUD 10/10	Peripheral blood	MAC	1:16 Anti-A + B	T 99% nT 100%	None	176	3	2	Yes	Infuse reaction	389
9	55	F	MDS	MUD 10/10	Peripheral blood	RIC	1:128 Anti-A	T 96% nT 100%	None	111	6	1	Yes	None reported	229
10	61	M	MDS	SIB 10/10	Peripheral blood	MAC	1:512 Anti-A	T 99% nT 100%	None	123	4	2	Yes	None reported	700
11	60	M	AML	MUD 9/10	Peripheral blood	RIC	1:128 Anti-A	Whole blood 100%	DLI	391	1	1	Yes	None reported	219
12	46	M	AML	MUD 10/10	Peripheral blood	RIC	1:256 Anti-A	Whole blood >95%	None	136	4	2	Yes	None reported	126
13	45	M	AML	MUD 10/10	Peripheral blood	MAC	1:128 Anti-A	Whole blood >95%	None	160	4	3	Yes	None reported	105
14	58	M	T-cell lymphoma¶	MUD 10/10	Peripheral blood	MAC	1:512 Anti-A	Whole blood 99%	DLI	123	4‡	-	No	None reported	-

AML, acute myeloid leukemia; BOR, bortezomib; DLI, donor lymphocyte infusion; MAC, myeloablative conditioning; MDS, myelodysplastic syndrome; MUD, matched unrelated donor; NMA, nonmyeloablative conditioning; PMF, primary myelofibrosis; PML, progressive multifocal leukoencephalopathy; RIC, reduced intensity conditioning; SIB, matched related donor; T/nT, T cell/non-T-cell chimerism.

*For details of the conditioning regimen, see supplemental Table 1.

†Highest titer reported, for additional information about Ig subclass see supplemental Table 2.

‡In 3 patients the dose interval of daratumumab was 14 days.

§Reticulocytosis is defined as recovery of normal values of absolute reticulocyte count ($>25 \times 10^9/L$).

|| At time of death (day 191), ongoing response.

¶Hepatosplenic T-cell lymphoma.

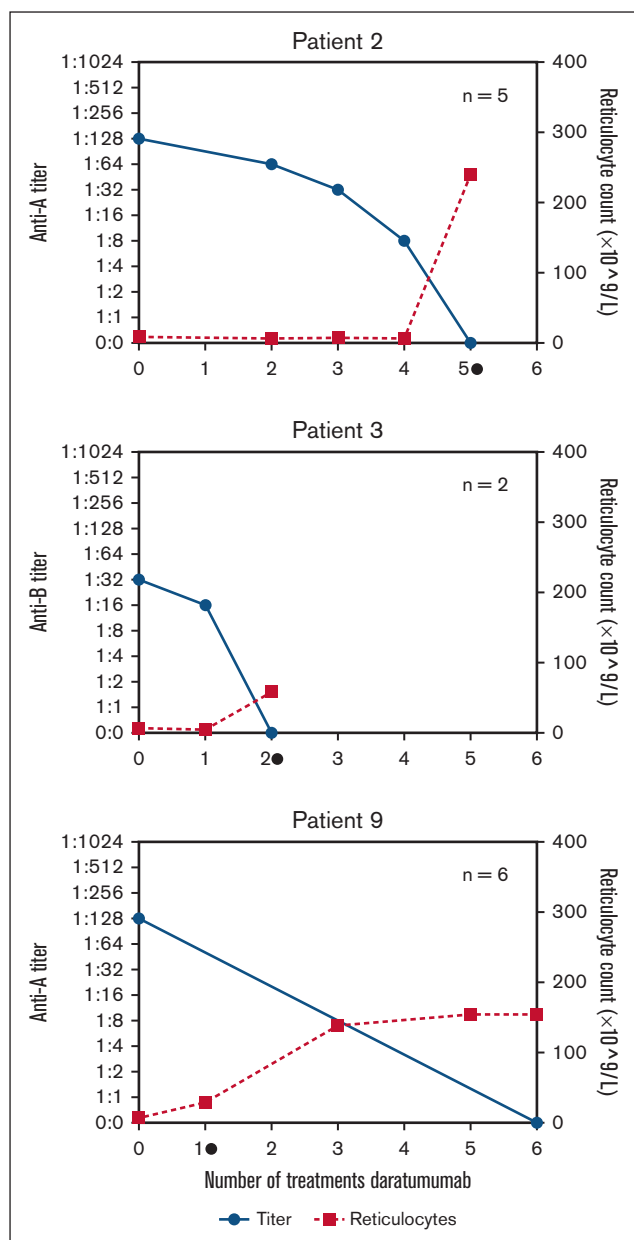


Figure 1. Development of ABO titer (blue, left axis) and reticulocytes (red, right axis) related to the number of daratumumab administrations.

Reticulocytosis was defined as reticulocyte count of $25 \times 10^9/L$. Please refer to supplemental Figure 1 for the development of ABO titer in all patients. ● = occurrence of reticulocytosis, n = total number of given daratumumab treatments.

daratumumab administration. In both patients, the disappearance of IsoHGs and development of reticulocytosis occurred simultaneously. Our data suggest that normalization of the ABO-titer and also the development of reticulocytosis can be used to determine the duration of daratumumab treatment. In this cohort, 1 patient (number 14) did not respond after 4 administrations of daratumumab. Potential explanations may be the very high titer of IsoHGs (1:1024) and/or other concomitant infections (the patient was febrile, a Parvo B19 infection was excluded) or that in some patients, >4 administrations of daratumumab are required (as

patient number 2). None of the patients with resolution of PRCA developed a relapse (median time of follow-up, 383 days, range 105-1045; Table 1).

We conclude that despite the retrospective nature of the study, we could report the largest real-world data cohort with an impressive overall response after a short treatment course. The importance of our observation is emphasized by the to date inconsistent results of other proposed treatment modalities such as rituximab or DLI.^{3,8} As PRCA can lead to long-lasting dependency on erythrocyte support and subsequent iron overload, it is evident that patients with severe and/or long-lasting PRCA might greatly benefit from a short course of daratumumab. Hereto, it is important to identify patients in whom PRCA will not resolve spontaneously and what is the optimal number of daratumumab administrations. Chimerism analysis of the lymphoid fraction could be used to demonstrate that the persistence of IsoHGs coincides with patient-derived plasma cells and that treatment with daratumumab results in elimination of these populations. In addition, standardization of methods to quantify and monitor IsoHGs is currently lacking,¹¹ as also reflected in this cohort. It is assumed that IgM IsoHGs are the main contributors to PRCA,⁹ as for patient 6 in this study, in which after normalization of the anti-A IgM, the PRCA resolved despite the persistence of anti-A IgG (supplemental Table 2).

In general, transplantation with a major ABO antagonism does not result in inferior overall survival.⁸ Recent publications have shown that most cases of PRCA resolve spontaneously within 3 to 9 months.^{3,8} However, high (>1:64) or increasing IsoHG titers, high frequency of erythrocyte support, and/or absence of graft-versus-host disease are associated with prolonged duration of PRCA. In addition, patients with PRCA and pancytopenia are at risk of developing poor graft function or secondary graft failure.⁸ These patients are likely to benefit from early treatment with daratumumab.

CD38 is not only expressed on plasma cells but also on T, B, and natural killer cells, as well as on erythrocytes, neutrophils, and other myeloid subsets.¹² Consequently, daratumumab treatment may lead to hypogammaglobulinemia, neutropenia, and lymphopenia, resulting in an increased susceptibility to infections.¹³ Experience with daratumumab treatment after allo-SCT mainly comes from patients with multiple myeloma, in which studies have shown no remarkable increase in infections or graft-versus-host disease.^{14,15} Although these results are reassuring, important safety concerns with regard to the development of infections remain unanswered for patients with posttransplant PRCA. Eight out of 14 patients were screened for hypogammaglobulinemia, of which 3 patients had a total IgG <5.0 g/L (data not shown). These patients received pretreatment with rituximab for PRCA, making it likely that multiple factors contributed to hypogammaglobulinemia. None of the patients developed severe bacterial infection. Patient 2 developed progressive multifocal leukoencephalopathy (PML). The first signs of PML started 9 months after allo-SCT, 7 months after rituximab, and 4 months after daratumumab treatment. As PML is only rarely associated with daratumumab and rituximab treatment and the allo-SCT procedure itself contains more well-known risk factors for developing PML, this case cannot link daratumumab treatment directly to the development of PML but neither can exclude a correlation.¹³

In summary, with the currently available data (14 patients presented here and 10 previously published cases), we propose that there are sufficient data to strongly consider treatment with daratumumab as early as 3 months after allo-SCT for patients with posttransplant PRCA with persisting high IsoHG titers (defined as $\geq 1:64$) combined with a requirement of frequent erythrocyte support or PRCA with concomitant pancytopenia. In 9 of 14 patients, both the development of reticulocytosis and normalization of the ABO-titer were observed after 1 or 2 administrations of daratumumab, suggesting that most patients may only need a short course of daratumumab. However, patients without reticulocytosis and/or persisting IsoHGs are likely to require prolonged treatment. These assumptions need to be tested in larger ("real-world") cohorts, in which predictors of spontaneous resolution of PRCA as well as the long-term safety profile of daratumumab need to be addressed.

Acknowledgments: Funding for this study was provided by the Dutch Cancer Society 2021-13493 to M.A.d.W. and Stichting Leukemie to M.A.d.W. and J.K.

Contribution: F.W. and C.N. collected data; F.W. and M.A.d.W. analyzed data; M.R., A.E.C.B., E.D., A.v.R., G.v.S., C.L.E.H., P.v.B., M.T.K., and M.A.d.W. treated patients and provided data; F.W., E.N., J.K., and M.A.d.W. wrote the manuscript; M.R., A.E.C.B., K.M.K.d.V., and L.M. reviewed the data and manuscript; and all authors approved the final version of the manuscript.

Conflict-of-interest disclosure: The authors declare no competing financial interests.

ORCID profiles: F.W., [0009-0001-7429-0616](https://orcid.org/0009-0001-7429-0616); E.D., [0000-0003-0905-1907](https://orcid.org/0000-0003-0905-1907); L.M., [0000-0001-5408-5298](https://orcid.org/0000-0001-5408-5298); J.K., [0000-0002-3914-7806](https://orcid.org/0000-0002-3914-7806); E.N., [0000-0002-7069-930X](https://orcid.org/0000-0002-7069-930X); M.A.d.W., [0000-0001-7470-2994](https://orcid.org/0000-0001-7470-2994).

Correspondence: Moniek de Witte, Department of Hematology, Universitair Medisch Centrum Utrecht, Huispostnummer B02.226, PO Box 85500, 3508 GA Utrecht, The Netherlands; email: m.a.dewitte-7@umcutrecht.nl.

References

1. Worel N. ABO-mismatched allogeneic hematopoietic stem cell transplantation. *Transfus Med Hemother*. 2016;43(1):3-12.
2. Aung FM, Lichtiger B, Bassett R, et al. Incidence and natural history of pure red cell aplasia in major ABO-mismatched haematopoietic cell transplantation. *British journal of haematology*. Mar 2013;160(6):798-805.
3. Marco-Ayala J, Gomez-Segui I, Sanz G, Solves P. Pure red cell aplasia after major or bidirectional ABO incompatible hematopoietic stem cell transplantation: to treat or not to treat, that is the question. *Bone Marrow Transplant*. 2021;56(4):769-778.
4. Zhu P, Wu Y, Cui D, et al. Prevalence of pure red cell aplasia following major abo-incompatible hematopoietic stem cell transplantation. *Front Immunol*. 2022;13:1-11.
5. D'Souza A, Fretham C, Lee SJ, et al. Current use of and trends in hematopoietic cell transplantation in the United States. *Biol Blood Marrow Transplant*. 2020;26(8):e177-e182.
6. Passweg JR, Baldomero H, Chabannon C, et al. Hematopoietic cell transplantation and cellular therapy survey of the EBMT: monitoring of activities and trends over 30 years. *Bone Marrow Transplant*. 2021;56(7):1651-1664.
7. Migdady Y, Pang Y, Kalsi SS, Childs R, Arai S. Post-hematopoietic stem cell transplantation immune-mediated anemia: a literature review and novel therapeutics. *Blood Adv*. 2022;6(8):2707-2721.
8. Longval T, Galimard JE, Lepretre AC, et al. Treatment for pure red cell aplasia after major ABO-incompatible allogeneic stem cell transplantation: a multicentre study. *Br J Haematol*. 2021;193(4):814-826.
9. Chapuy CI, Kaufman RM, Alyea EP, Connors JM. Daratumumab for delayed red-cell engraftment after allogeneic transplantation. *N Engl J Med*. 2018;379(19):1846-1850.
10. Martino R, Garcia-Cadenas I, Esquirol A. Daratumumab may be the most effective treatment for post-engraftment pure red cell aplasia due to persistent anti-donor isohemagglutinins after major ABO-mismatched allogeneic transplantation. *Bone Marrow Transplant*. 2022;57(2):282-285.
11. Booth GS, Gehrie EA, Bolan CD, Savani BN. Clinical guide to ABO-incompatible allogeneic stem cell transplantation. *Biol Blood Marrow Transplant*. 2013;19(8):1152-1158.
12. Piedra-Quintero ZL, Wilson Z, Nava P, Guerau-de-Arellano M. CD38: an immunomodulatory molecule in inflammation and autoimmunity. *Front Immunol*. 2020;11:597959.
13. EMA Europe. Summary of Product Characteristics / Daratumumab. Accessed 12 February 2024. https://www.ema.europa.eu/en/documents/product-information/darzaalex-epar-product-information_n1.pdf
14. Nikolaenko L, Chhabra S, Biran N, et al. Graft-versus-host disease in multiple myeloma patients treated with daratumumab after allogeneic transplantation. *Clin Lymphoma Myeloma Leuk*. 2020;20(6):407-414.
15. Vincent L, Gras L, Ceballos P, et al. Daratumumab after allogeneic hematopoietic cell transplantation for multiple myeloma is safe and synergies with pre-existing chronic graft versus host disease. A retrospective study from the CMWP EBMT. *Bone Marrow Transplant*. 2022;57(3):499-501.