

Case Report

Liposomal bupivacaine for ultrasound-guided rectus sheath blocks after midline laparotomy

M. S. Vereen,¹  F. Harms,¹ R. J. Stolker² and M. Dirckx¹

¹ Consultant, ² Professor Emeritus, Department of Anaesthesia, Erasmus Medical Centre, Rotterdam, The Netherlands

Summary

Optimal pain management after open abdominal surgery is essential but can be difficult to achieve. The effects of inadequate analgesia go beyond the first few postoperative days; severe acute postoperative pain may contribute to the development of chronic postsurgical pain. Thoracic epidural analgesia is a traditional approach to the management of acute pain after open abdominal surgery but has multiple possible contraindications and can be technically challenging. In our hospital, we typically offer ultrasound-guided rectus sheath blocks with catheters when epidural analgesia is not feasible. However, the recent registration of long-acting liposomal bupivacaine in the Netherlands as well as logistical and equipment-related issues have led us to consider liposomal bupivacaine as an alternative to the use of catheters. Here, we present a short case series to describe our first clinical experiences with the use of liposomal bupivacaine in ultrasound-guided rectus sheath blocks after midline laparotomy for three patients in whom epidural insertion was contraindicated.

Correspondence to: M. S. Vereen

Email: m.vereen@erasmusmc.nl

Accepted: 6 February 2024

Keywords: anaesthetics; bupivacaine; laparotomy; local; pain; postoperative

Introduction

Optimal peri-operative pain management for patients undergoing open abdominal surgery is essential as it reduces the surgical stress response, protects the myocardium, improves postoperative pulmonary function and results in earlier mobilisation [1]. Additionally, severe acute postoperative pain is an important predictor for the development of chronic postsurgical pain [2]. Thoracic epidural analgesia is a traditional approach for optimal pain management after open abdominal surgery. Its use has declined in recent years due to the development and widespread adoption of minimally invasive laparoscopic surgical techniques and enhanced recovery goals such as early ambulation, which may be delayed by epidural use. Thoracic epidurals can contribute to postoperative hypotension, and patient factors such as anticoagulation therapies may preclude their use [3].

At our hospital, ultrasound-guided bilateral rectus sheath blocks with 22G catheters are the standard regional technique for analgesia after midline laparotomy when epidural analgesia is contraindicated. One catheter is placed either side of the midline, remaining in situ for three postoperative days, depending on the type of surgery and the clinical condition of the patient. Before the COVID-19 pandemic, bolus injections down the catheters were delivered manually three times daily by the acute pain service staff, using 20 ml of 0.2% ropivacaine on each side. This is a resource-heavy process, and staff shortages since the pandemic have resulted in instances of delayed boluses and inadequate pain management. Our nursing staff have also reported hand pain due to the need to deliver repeated bolus injections through the catheters. To address these issues, we transitioned to the use of elastomeric pumps (ON-Q NRFit®, B. Braun Medical B.V., Oss, The Netherlands). Since then, we have observed a number of catheter-related problems including displacement, leakage and adverse effects on patient mobility. This

prompted us to consider the use of liposomal bupivacaine, a long-acting local anaesthetic, registered for use in the European Union since 2020 [4].

Liposomal bupivacaine (Fig. 1) is a compound consisting of multivesicular liposomes encapsulating bupivacaine within aqueous chambers [5]. The liposomes allow the slow release of bupivacaine. It was introduced in the United States in 2011 and produces consistent concentrations of bupivacaine for up to 72 h after injection [6]. The expected extension of analgesia is promising and may enable us to avoid siting catheters.

Report

Three patients scheduled for elective midline laparotomy for oncology surgery with contraindications for the use of epidural analgesia were identified. They all gave informed consent for the use of rectus sheath blocks for postoperative analgesia. All patients scored ASA III based on prior myocardial infarction (patient 1), atrial fibrillation and prior malignancy (patient 2) and hypertension with decreased renal function (patient 3). All were opioid naïve, without a history of chronic pain. Patients 1 and 3 underwent resection of a gastrointestinal stromal tumour (GIST), and patient 2 required a metastasectomy of a synovial sarcoma from the small bowel.

Each patient received standard monitoring before induction and maintenance of general anaesthesia with a propofol and remifentanyl-based intravenous technique. Each patient received intravenous paracetamol 1 g and morphine 0.1 mg.kg⁻¹ before wound closure. Before emergence from anaesthesia, bilateral ultrasound-guided in-plane rectus sheath blocks were performed just proximal to the umbilicus (Sonosite Edge II, Fujifilm Holdings, Bothell, WA, USA). The rectus sheath was approached laterally to the rectus abdominis muscle with the needle tip constantly in ultrasonic view until it reached the posterior rectus sheath. Once correct positioning was confirmed with 2 ml of saline, the local anaesthetic solution was injected. We used 10 ml liposomal bupivacaine 1.33%, 20 ml bupivacaine 0.25% plus 20 ml of saline. All patients emerged from general anaesthesia uneventfully.

Our standard multimodal postoperative analgesia regime was prescribed. This comprised paracetamol 1 g four times daily and an intravenous patient-controlled analgesia (PCA) pump containing morphine, with 1 mg available every 6 min without background infusion. On the second postoperative day, all patients tolerated oral intake. At that stage, the PCA was stopped, and all patients were prescribed 5 mg immediate-release oxycodone PRN. In addition to this, patient two required naproxen 250 mg three times daily as well as 10 mg oxycodone slow release twice daily to achieve effective analgesia. Pain scores were recorded three times daily and data on opioid consumption were collected by the acute pain service. We contacted patients by telephone 2 weeks postoperatively to ask them about their opioid use, pain and satisfaction regarding postoperative pain management.

Table 1 describes patient characteristics, opioid consumption and pain scores. The 11-point numeric rating scale (NRS) was used to assess patients' pain (0 = no pain, 1–3: mild pain, 4–6: moderate pain, 7–10: severe pain). Patients reported this score to staff verbally or with the aid of a double-sided ruler showing the numeric rating scale on one side and the revised faces pain scale on the other side. Patients 1 and 3 were comfortable on emergence from anaesthesia and were discharged to standard ward care without supplemental analgesics. After emergence from anaesthesia, patient 2 experienced severe discomfort from the urinary catheter which was successfully managed with paracetamol 1 g and oral oxybutynin 5 mg. On postoperative day 1, patient 2 required the least opioid and had the lowest pain score. On postoperative day 2, he required more opioid but still had the lowest pain score. On day 3, patient 2 required more opioid, while all patients had similar pain scores.

In general, all patients were satisfied with the management of their postoperative pain. They were all able to sleep, cough and mobilise on the first postoperative day, and were discharged home either on day 2 or 3 postoperatively. Two weeks after surgery, patient 1 still experienced mild visceral pain, but did not require any analgesics. The other two patients had no pain or analgesic requirement. All patients were satisfied with their overall postoperative pain experience.

Discussion

In three patients undergoing elective midline laparotomy, ultrasound-guided rectus sheath blocks with liposomal bupivacaine provided good analgesia in the immediate postoperative period and up to 2 weeks postoperatively.

Ultrasound-guided rectus sheath blocks are indicated for umbilical surgery or midline laparotomy [7]. Needle placement cranio-lateral to the umbilicus and injection of local anaesthetic between the rectus abdominis muscle and the posterior rectus sheath provides analgesia in the midline from thoracic levels 7–12 [7]. It is important to note that, unlike epidural analgesia, rectus sheath blocks do not cover the visceral component of pain.

Table 1 Patient characteristics, total postoperative opioid use per day expressed in oral morphine milligram equivalents (MME) and mean pain scores according to the numeric rating scale (NRS).

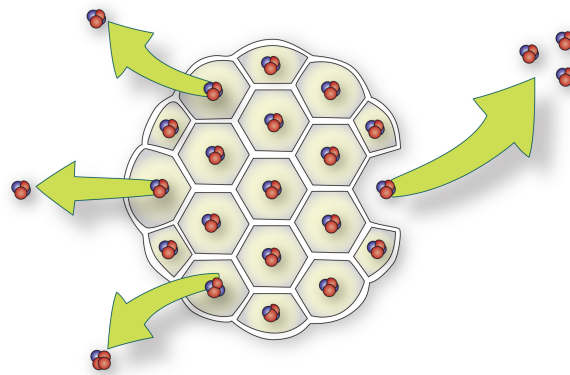
	Patient 1	Patient 2	Patient 3
Age	62	76	75
Sex	Male	Male	Female
ASA classification	3	3	3
Type of surgery	Wedge resection from stomach (GIST*)	Metastasectomy of synovial sarcoma from small bowel	Wedge resection from stomach (GIST*)
Pre-operative opioid use	None	None	None
MME day 1	81	9	84
NRS day 1	4	2	5
MME day 2	22.5	39	36
NRS day 2	4.5	2	4.5
MME day 3	7.5	30	7.5
NRS day 3	4	4	3
MME 72 h to 2 weeks postoperative	7.5	30	0
MME at 2 weeks	0	0	0
NRS at 2 weeks	2	0	0

*GIST – gastrointestinal stromal tumour.

Day 1 = up to 24 h postoperatively.

Day 2 = 24–48 h postoperatively.

Day 3 = 48–72 h postoperatively.

**Figure 1** Bupivacaine molecules within multi-vesicular liposomes. The arrows indicate the release of bupivacaine from vesicles at the outer layer of the molecule as the phospholipid bilayer deteriorates. Image courtesy of Pacira Pharmaceuticals Inc.

Liposomal bupivacaine has not been available for clinical use until recently. Availability is currently limited to the USA (since 2011), the European Union (since 2020) and the United Kingdom (since 2021). Each particle of liposomal bupivacaine consists of microscopic multivesicular liposomes (Fig. 1). The liposomes have a phospholipid bilayer and an aqueous core containing bupivacaine. Bupivacaine is loaded into these internal aqueous chambers using DepoFoam® technology (Pacira Pharmaceuticals Inc, San Diego, CA, USA). Each particle of liposomal bupivacaine has a honeycomb-like structure and this non-concentric nature leads to increased stability and longer duration of drug release. The external layer of the multivesicular liposome deteriorates over time, and once it is breached, the bupivacaine within is released. The remaining bupivacaine within other vesicles redistributes within the particle without being released because of vesicles being rearranged by internal fusion and division [5].

There is limited published data on the role of liposomal bupivacaine in analgesia using rectus sheath blocks after open abdominal surgery, and much of the research on its clinical use has focussed on orthopaedic surgery. We limited our literature search to rectus sheath blocks with liposomal bupivacaine in open abdominal surgery but we only identified a case report describing the use of liposomal bupivacaine in rectus sheath blocks after emergency midline laparotomy in the setting of abdominal sepsis [8].

Patients 1 and 3 reported higher pain scores and had greater opioid requirements on the first postoperative day. We think this could be attributed to the nature of the operations (both were wedge resections from the stomach of gastrointestinal stromal tumours, GIST) rather than a small bowel operation as in the case of patient 2, which are associated with a different source of visceral pain. Patient 2 had similar pain scores to the other patients on day 3 despite a higher opioid consumption. All recovered uneventfully without complications.

We used normal bupivacaine with its faster onset of action in combination with liposomal bupivacaine (which has a slower onset of action). Saline was used to dilute the solution to a volume of 50 ml per side which we considered sufficient to fill the potential space created by the rectus sheath block. A study describing the spread and effectiveness of levobupivacaine 0.375% used 20 ml of local anaesthetic for umbilical hernia repair surgery [9]. A recent study of seven cadavers suggests that at least 30 ml per side is needed for spread from xiphoid to pubis [10].

We acknowledge the limitations of our short case series comprising only three patients, all of whom were having elective abdominal oncological surgery. We performed our rectus sheath blocks after skin closure, and we did not record ultrasound images to verify the correct needle placement.

We considered the opioid requirement and corresponding pain scores to indicate good analgesic outcomes for all three patients. At two weeks postoperatively, none of the patients were still experiencing moderate or severe pain and did not require opioid or other analgesics. This is an important observation, as pain at two weeks postoperatively is a predictor for the development of chronic postsurgical pain [2]. Based on this experience, we consider liposomal bupivacaine a viable alternative which warrants further investigation in ultrasound-guided rectus sheath blocks after midline laparotomy with regard to opioid consumption, pain scores, incidence of chronic postsurgical pain and patient satisfaction.

Acknowledgements

This case report was published with the written consent of all three patients. The authors declare no conflicts of interest or external funding.

References

1. Nimmo SM, Harrington LS. What is the role of epidural analgesia in abdominal surgery? *Continuing Education in Anaesthesia Critical Care and Pain* 2014; **14**: 224–9.
2. van Driel MEC, van Dijk JFM, Baart SJ, Meissner W, Huygen FJPM, Rijdsdijk M. Development and validation of a multivariable prediction model for early prediction of chronic postsurgical pain in adults: a prospective cohort study. *British Journal of Anaesthesia* 2022; **129**: 407–15.
3. Chin KJ, McDonnell JG, Carvalho B, Sharkey A, Pawa A, Gadsden J. Essentials of our current understanding. *Regional Anesthesia and Pain Medicine* 2017; **42**: 133–83.
4. Ilfeld BM. Continuous peripheral nerve blocks. *Anesthesia and Analgesia* 2017; **124**: 308–35.
5. Chahar P, Cummings KC 3rd. Liposomal bupivacaine: a review of a new bupivacaine formulation. *Journal of Pain Research* 2012; **5**: 257–64.
6. Ranganath YS, Sondekoppam RV. Liposomal bupivacaine for prolonging analgesia with TAP blocks—two steps forward, one step back. La bupivacaine liposomale pour prolonger l'analgésie des blocs TAP — deux pas en avant, un pas en arrière. *Canadian Journal of Anaesthesia* 2021; **68**: 755–60.
7. Krige A, Scott M. Truncal Blocks: Rectus Sheath Catheters. In: Krige A, Scott MJP eds. *Analgesia in major abdominal surgery*. Cham, Switzerland: Springer; 2018. 193–213.
8. Patzkowski MS, Stevens G. Multimodal analgesia in abdominal sepsis: a case report of liposome bupivacaine in ultrasound-guided rectus sheath blocks after unexpected open hemi-colectomy. *Military Medicine* 2015; **180**: e728–31.
9. Manassero A, Bossolasco M, Meineri M, Ugues S, Liarou C, Bertolaccini L. Spread patterns and effectiveness for surgery after ultrasound-guided rectus sheath block in adult day-case patients scheduled for umbilical hernia repair. *Journal of Anaesthesiology Clinical Pharmacology* 2015; **31**: 349–53.
10. Rojas A, McMillan DT, Allan JD, et al. Evaluating patterns of injectate spread after rectus sheath block: a cadaveric dissection study. *Cureus* 2023; **15**: e34142.