

CXCR4-targeted Theranostics in Hematooncology: Opportunities and Challenges

CXCR4-gerichtete Theranostics in der Hämato-Onkologie: Möglichkeiten und Herausforderungen



Authors

Rudolf Werner¹, Alexander Haug², Christian Buske³, Simon Heidegger⁴, Anna L. Illert⁵, Florian Bassermann⁴, Peter Herhaus⁴, Andreas Buck¹, Johannes Duell⁶, Max S Topp⁶, Sabrina Kraus⁶, Hermann Einsele⁶, Constantin Lapa⁷, Markus Raderer⁸, Georg Lenz⁹, Stefan Habringer¹⁰, Bastian von Tresckow¹¹, Ulrich Keller¹⁰

Affiliations

- 1 Department of Nuclear Medicine, University Hospital Würzburg, Würzburg, Germany
- 2 Clinical Department of Nuclear Medicine, University Hospital AKH Vienna, Wien, Austria
- 3 Institute of Experimental Cancer Research, Ulm University Hospital, Ulm, Germany
- 4 Department of Medicine III, School of Medicine, Technical University of Munich, München, Germany
- 5 Department of Hematology and Oncology, Freiburg University Hospital, Freiburg, Germany
- 6 Internal Medicine II, University Hospital Würzburg, Würzburg, Germany
- 7 Nuclear Medicine, Faculty of Medicine, University of Augsburg, Augsburg, Germany
- 8 Department of Internal Medicine I, Medical University of Vienna, Vienna, Austria
- 9 Department of Medicine A - Hematology, Oncology and Pneumology, University Hospital Münster, Münster, Germany
- 10 Department of Hematology, Oncology and Cancer Immunology, corporate member of Freie Universität Berlin and Humboldt-Universität zu Berlin, Charité Universitätsmedizin Berlin, Berlin, Germany
- 11 Department of Hematology and Stem Cell Transplantation, West German Cancer Center, University Hospital Essen, Essen, Germany

Key words

CXCR4, chemokine receptor, theranostics, marginal zone lymphoma, T-cell lymphoma, [68Ga]Ga-PentixaFor

received 09.08.2023

accepted 18.09.2023

published online 08.01.2024

Bibliography

Nuklearmedizin 2024; 63: 57–61

DOI 10.1055/a-2194-9965

ISSN 0029-5566

© 2024. The Author(s).

This is an open access article published by Thieme under the terms of the Creative Commons Attribution License, permitting unrestricted use, distribution, and reproduction so long as the original work is properly cited. (<https://creativecommons.org/licenses/by/4.0/>).

Georg Thieme Verlag KG, Rüdigerstraße 14, 70469 Stuttgart, Germany

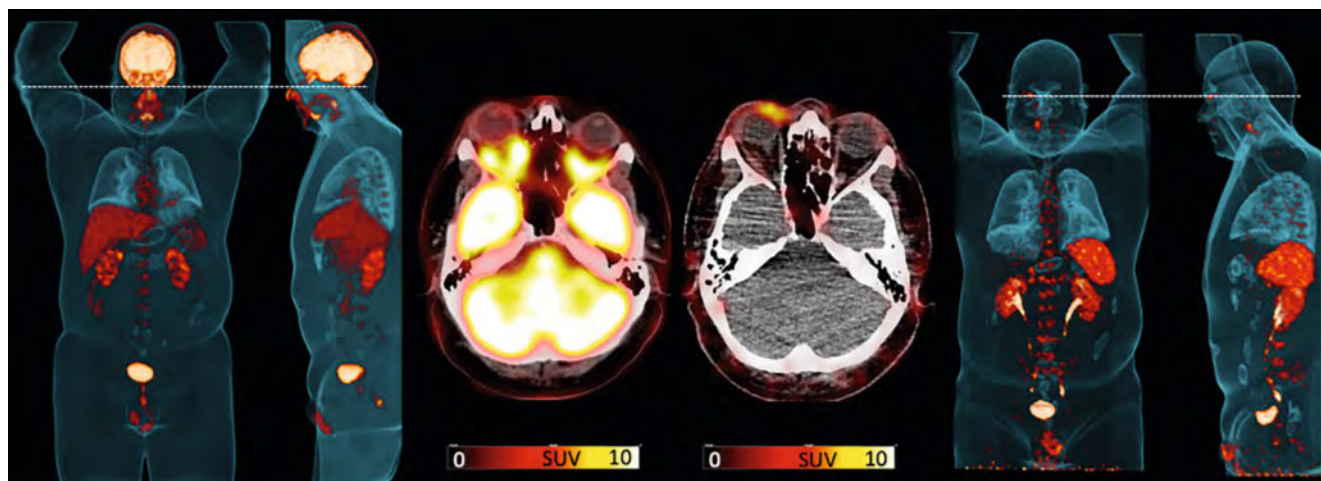
Correspondence

Dr. Rudolf Werner

Department of Nuclear Medicine, University Hospital Würzburg, Würzburg, Germany
werner_r1@ukw.de

ABSTRACT

C-X-C motif chemokine receptor 4 (CXCR4) is overexpressed in a multitude of cancers, including neoplasms of hematopoietic origin. This feature can be leveraged by a theranostic approach, which provides a read-out of the actual CXCR4 expression in vivo, followed by CXCR4-targeted radioligand therapy (RLT) exerting anti-cancer as well as myeloablative efficacy. In a recent meeting of hematooncology and nuclear medicine specialists, statements on the current clinical practice and future perspectives of this innovative concept were proposed and summarized in this opinion article. Experts concluded that i) CXCR4-directed [68Ga]Ga-PentixaFor PET/CT has the potential to improve imaging for patients with marginal zone lymphoma; ii) CXCR4-targeted RLT exerts anti-lymphoma efficacy and myeloablative effects in patients with advanced, treatment-refractory T-cell lymphomas; iii) prospective trials with CXCR4-based imaging and theranostics are warranted.



► **Fig. 1** Maximum intensity projections of PET/CTs using $[^{18}\text{F}]\text{FDG}$ (leftmost panels) and $[^{68}\text{Ga}]\text{Ga-PentixaFor}$ (rightmost panels) in a subject with orbital marginal zone lymphoma. The middle panels show PET/CT images of axial sections of lymphoma manifestation using $[^{18}\text{F}]\text{FDG}$ (bottom) and $[^{68}\text{Ga}]\text{Ga-PentixaFor}$ (top). On $[^{18}\text{F}]\text{FDG}$, MZL manifestation is not visible due to the physiological high uptake of the PET probe in brain tissue, whereas the $[^{68}\text{Ga}]\text{Ga-PentixaFor}$ -based images enables detection of the manifestation in the periorbital area. Data from same patient but different images as in Buck et al, *J Nucl Med* 2023 Jul;64(7):1009–1016 [4].

Introduction

Theranostics combines molecular imaging and therapy through applying identical or related radiolabelled molecules to specifically detect and damage cancerous tissues [1]. While such radiopharmaceuticals are now routinely applied for solid tumours [2, 3], recent years have witnessed an increasing use for hematopoietic malignancies, in particular by targeting C-X-C motif chemokine receptor 4 (CXCR4) [4]. In the course of the annual meeting of the German Society for Haematology and Medical Oncology held in October 2022, experts met to discuss recent developments in the field of CXCR4-based theranostics and to devise some basic statements on potential clinical applications and future perspectives of this concept.

In this manuscript, we present these statements in detail, along with a brief overview on CXCR4-directed molecular imaging and therapy.

Expert panel statement I: CXCR4-directed molecular imaging may be useful for marginal zone lymphoma patients

CXCR4-directed Molecular Imaging

CXCR4 upregulation in varying tumour entities render it as an attractive target to identify cancerous tissue [5], which can be exploited using CXCR4-directed radiotracers, including the cyclic ^{68}Ga -labelled CXCR4-binding pentapeptide CPC4.2 ($[^{68}\text{Ga}]\text{Ga-PentixaFor}$) [6]. Relative to the most widely used PET radiotracer 2-deoxy-2- $[^{18}\text{F}]\text{fuoro-D-glucose}$ ($[^{18}\text{F}]\text{FDG}$), $[^{68}\text{Ga}]\text{Ga-PentixaFor}$ often achieved equal, sometimes superior or at least complementary diagnostic performance in nuclear oncology [7, 8, 9, 10]. Accordingly, $[^{68}\text{Ga}]\text{Ga-PentixaFor}$ has been extensively tested to identify sites of disease in patients with solid tumours and haematological malignancies, providing promising results for marginal zone (MZL, ► **Fig. 1**) and T-cell lymphoma (TCL) [9, 11]. Beyond

an improved read-out relative to the reference radiotracer $[^{18}\text{F}]\text{FDG}$, however, $[^{68}\text{Ga}]\text{Ga-PentixaFor}$ also allows for quantification of CXCR4 expression in lymphoma manifestations *in vivo*, thereby identifying patients that could therefore be eligible for CXCR4-directed radioligand therapy (RLT) using the theranostic, β -emitting twin $[^{177}\text{Lu}]\text{Lu-}$ or $[^{90}\text{Y}]\text{Y-PentixaTher}$ [12].

CXCR4-directed PET/CT for Marginal Zone Lymphoma

The most comprehensive approach investigating the use of $[^{68}\text{Ga}]\text{Ga-PentixaFor}$ for imaging of solid and haematological neoplasms was conducted in a multi-centric retrospective analysis from Vienna and Würzburg Universities [10]. $[^{68}\text{Ga}]\text{Ga-PentixaFor}$ PET/CTs were conducted in 690 patients and almost 70 % showed radiotracer accumulation in sites of disease which were substantially higher than physiological background activity. In this regard, the highest uptake was observed for multiple myeloma (MM), mantle cell lymphoma (MCL) and MZL [10]. Duell et al. then imaged 22 newly diagnosed MZL patients with chemokine receptor PET/CT and compared those findings with conventional, guideline-compatible diagnostic work-up (including $[^{18}\text{F}]\text{FDG}$ PET/CT, bone marrow biopsy, and endoscopy) [9, 13]. In 16 of 18 PET-guided biopsy samples, imaging results could be confirmed upon CXCR4 immunohistochemistry. $[^{68}\text{Ga}]\text{Ga-PentixaFor}$ PET/CT had a significant impact on staging according to modified Ann Arbor classification in nearly 50 % (mostly upstaging) and, importantly, on treatment decision in one third of the patients [9]. A more comprehensive investigation involving 100 MZL patients recently reported comparable results [14]. $[^{68}\text{Ga}]\text{Ga-PentixaFor}$ uptake was observed in 78 % of the patients, and again, in almost half of the subjects, this led to an upstaging using Ann Arbor classification. In addition, an elevated CXCR4-PET signal showed a trend towards shorter progression-free survival, suggesting that $[^{68}\text{Ga}]\text{Ga-PentixaFor}$ may also represent a prognostic biomarker with regard to disease progression and need for improved/intensified treatment [14].

As a sub-form of MZL, mucosa-associated lymphoid tissue (MALT) lymphomas are diagnostically challenging as they often lack specific symptoms and are associated with multi-organ involvement [15], but also known to overexpress CXCR4 [16]. Haug and colleagues examined MALT lymphoma patients with a wide range of organs affected using [⁶⁸Ga]Ga-PentixaFor PET/magnetic resonance imaging (MRI) and found an intense uptake in 33/36 patients, while three negative cases having undergone surgery for their orbital MALT lymphomas prior to imaging [17]. Another prospective study used [⁶⁸Ga]Ga-PentixaFor PET/MRI to evaluate treatment responses after first-line *Helicobacter pylori* eradication in 26 gastric MALT lymphoma patients and compared CXCR4-based imaging findings with a control group of 20 subjects without lymphoma [18]. [⁶⁸Ga]Ga-PentixaFor PET/MRI yielded a 100% detection rate, as confirmed in time-matched gastric biopsies. Furthermore, neither false-positive nor false-negative results were obtained, and overall, between 93% and 100% accuracy, sensitivity, specificity, positive and negative predictive values for the detection of residual gastric disease were determined.

At present, diagnostics of MZL and MALT lymphoma are rather complex due to the heterogeneity of the disease and often cumbersome for the patients when multiple biopsies and possibly endoscopies are required [13]. This, together with the provided benefit of CXCR4-targeted PET/CT as summarized above, led the experts to suggest that [⁶⁸Ga]PentixaFor PET might serve as a valuable diagnostic tool for MZL including MALT lymphoma, and should be further developed in prospective clinical trials.

Expert panel statement II: CXCR4-based theranostics may be useful in advanced, treatment-refractory T-cell lymphoma

CXCR4-directed Radioligand Therapy

After having identified CXCR4 expression using [⁶⁸Ga]Ga-PentixaFor PET, the positron emitter can be exchanged with an α - or β -emitting radionuclide that exerts direct cell damaging effects, e. g., [¹⁷⁷Lu]Lu-/[⁹⁰Y]Y-PentixaTher [19]. Of note, this theranostic counterpart exhibits not only anti-lymphoma, but also myeloablative effects due to targeting the hematopoietic stem/progenitor/cell (HSPC) compartment, which may be desired for selected patients affected with hematopoietic neoplasms to prepare for hematopoietic stem cell transplantation (HSCT) [12]. As a biological rationale, expression of CXCR4 is not only pronounced in lymphoma sites, but also in cells of the bone marrow [20]. Thus, CXCR4-mediated RLT then also allows targeting of the HSPC niche beyond targeting manifestations of the underlying CXCR4-positive disease [12].

CXCR4-directed treatment for T-Cell Lymphoma

In peripheral TCL, a wide range of first-line treatment regimens exists, which are frequently not able to provide long-term disease control or cure. Targeted and more effective therapeutic regimens are available for patients with CD30 expressing TCLs [21]. However, CD30 is expressed only in approximately half of the patients [22]. In selected patients, which are refractory to standard therapeutic regimen (chemotherapy \pm CD30 antibody \pm high-

dose therapy and autologous HSCT), allogeneic HSCT involving cytotoxic bone marrow ablation (myeloablation) may be indicated [23]. In this regard, CXCR4-directed RLT using [⁹⁰Y]Y-PentixaTher may also provide relevant myeloablative efficacy [11]. For instance, in four TCL patients with advanced disease having exhausted all previous treatment options, a retrospective examination with CXCR4-PET/CT was followed by CXCR4-targeted RLT combined with conditioning regimen and HSCT. One of these patients developed tumour lysis syndrome and transient grade 3 kidney failure, while one patient died more than two weeks after RLT after developing septicaemia. Partial metabolic response was observed in one and complete metabolic response in the two other patients (with one subject also treated with additional radioimmunotherapy; ► Fig. 2) [11]. As such, CXCR4-mediated RLT may serve as an effective conditioning therapy for HSCT with concurrent anti-lymphoma activity in treatment-refractory TCL in advanced disease setting.

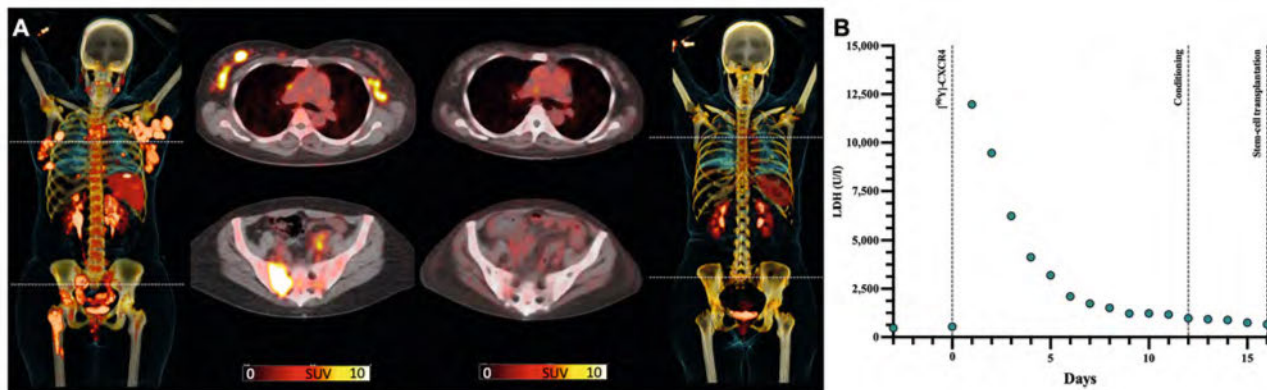
Expert panel statement III: Prospective trials are required to provide additional data and guidelines on CXCR4-directed imaging and therapy in malignancies of the hematopoietic origin

Considering the wide range of highly promising but often preliminary or only retrospectively assessed data, the experts concluded that there is a need for prospective studies investigating the use of CXCR4-directed radiopharmaceuticals for both imaging and therapy. At present, prospective trials for CXCR4-directed RLT are in preparation, aimed at investigating the activity, tolerable dose and side effects of [⁹⁰Y]Y-PentixaTher in patients with recurrent or refractory primary or isolated secondary central nervous system lymphoma, (PTT101, EudraCT No. 2021-002364-43), multiple myeloma (MM) and other lymphoma subtypes (COLPRIT trial, EudraCT No. 2022-002989-33) [24, 25]. Another registered study investigates [⁶⁸Ga]Ga-PentixaFor PET/CT for initial staging and therapeutic monitoring for MM (NCT04561492) [26]. In addition, a basket trial enrolling approximately 20 patients will also broaden the diagnostic experience on [⁶⁸Ga]Ga-PentixaFor in patients with varying hematopoietic (pre)neoplasms, including monoclonal gammopathy of undetermined significance, smoldering MM and Non-Hodgkin lymphoma (NCT05093335) [27]. Moreover, a phase III study in MZL patients will compare [⁶⁸Ga]Ga-PentixaFor with [¹⁸F]FDG PET/CT in 148 patients examined in 28 participating European centres [28]. ► Table 1 provides an overview of planned and currently recruiting studies on CXCR4-directed imaging and therapy in patients affected with malignancies of the hematopoietic system.

As agreed by the expert panel, these studies and others yet to be conceived should ultimately allow for assessing the most appropriate applications of the theranostic concept.

Conclusions

CXCR4-directed theranostics using the PET agent [⁶⁸Ga]Ga-PentixaFor and its therapeutic twin [¹⁷⁷Lu]Lu-/[⁹⁰Y]Y-PentixaTher has been extensively investigated in recent years. Based on these results, its diagnostic use appears to be promising in patients with



► **Fig. 2** Complete metabolic response after CXCR4-directed radioligand therapy (RLT) in a patient affected with advanced, treatment-refractory T-cell lymphoma. After RLT, conditioning therapy and allogeneic haematopoietic stem cell transplantation were conducted, leading to successful engraftment. (A) Maximum intensity projections of CXCR4-targeted [68Ga]PentixaFor PET/CTs before (leftmost panel) and 4 months after (rightmost panel) RLT with [90Y]PentixaTher. Prior to therapy, multiple CXCR4-positive foci on transaxial PET/CTs were visible, including lymphonodal, peritoneal and bone manifestations (middle panels, left), whereas imaging four months after RLT showed a complete response (middle panels, right). (B) Time course of lactate dehydrogenase (LDH, in U/l) serving as a surrogate marker of induced lymphoma damage. An initial peak of LDH was followed by a rapid decrease, indicating an immediate response to CXCR4-directed RLT independent of conditioning therapy. Data from same patient but different images as in Buck et al. J Nucl Med, 2023 Jan;64(1):34–39 [11].

► **Table 1** Overview of selected prospective clinical trials on CXCR4-directed Theranostics focusing on Haematological Malignancies.

Purpose	Study Ab- breviation*	Registration No.	Brief Description	Status
Diagnosis	PentiMyelo	NCT04561492	Phase I/II study using [68Ga]Ga-PentixaFor PET/CT for staging and therapeutic monitoring of multiple myeloma (MM) patients scheduled for first line treatment [26]	Recruiting
		NCT05093335	Phase I/II study using [68Ga]Ga-PentixaFor PET/CT in treatment-naïve, therapy-refractory or relapsed patients with proven monoclonal gammopathy of undetermined significance, smoldering MM, or Non-Hodgkin lymphoma [27]	Recruiting
	PTF301 (LYMFOR)	EU CT No 2022–500918–25	Phase III study using [68Ga]Ga-PentixaFor PET/CT relative to [18F]FDG PET/CT for staging of patients with marginal zone lymphoma [28]	Planned
	PENTI-MIDAS	NCT05321862	Phase I/II study using [68Ga]Ga-PentixaFor for staging and assessment of minimal residual disease in MM patients eligible for hematopoietic stem cell transplantation [29]	Not yet Recruiting
Therapy	COLPRIT	EudraCT No. 2022–002989–33	Phase I/II study evaluating CXCR4-directed radioligand therapy (RLT) in advanced lymphoproliferative disease [24]	Planned
	PENTILULA		Phase I/II study evaluating RLT with [177Lu]Lu-PentixaTher in patients with relapsed or refractory CXCR4+ acute leukemia	Planned
	PENTALLO		Phase I study testing RLT with [177Lu]Lu-PentixaTher prior to allograft transplantation in acute myeloid leukemia/acute lymphocytic leukemia patients	Planned
	PTT101	EudraCT No. 2021–002364–43	Phase I/II dose escalation study to evaluate safety, tolerability, biodistribution and efficacy of [90Y]Y-PentixaTher for recurrent or refractory primary or isolated secondary central nervous system lymphoma [25]	Planned

*if available.

MZL including MALT lymphoma. For therapeutic applications, anti-lymphoma efficacy exerted by CXCR4 RLT may be useful in advanced and treatment-refractory TCL. Nonetheless, data from prospective studies are required to allow for incorporation of this theranostic strategy into clinical practice.

Conflict of Interest

The authors received no honoraria for their authoring activities but have received honoraria (speaking and/or consulting activities) from PentixaPharm for the participation in the expert meeting. The authors have no other conflicts of interest in relation to this paper. This article was supported financially by PentixaPharm (medical writing support). No influence was exerted on the content of the article.

References

- [1] Aboagye EO, Barwick TD, Haberkorn U. Radiotheranostics in oncology: Making precision medicine possible. *CA Cancer J Clin* 2023; 73 (3): 255–274. doi:10.3322/caac.21768
- [2] Strosberg J, El-Haddad G, Wolin E et al. Phase 3 Trial of (177)Lu-Dotatate for Midgut Neuroendocrine Tumors. *N Engl J Med* 2017; 376 (2): 125–135. doi:10.1056/NEJMoa1607427
- [3] Sartor O, de Bono J, Chi KN et al. Lutetium-177-PSMA-617 for Metastatic Castration-Resistant Prostate Cancer. *N Engl J Med* 2021; 385 (12): 1091–1103. doi:10.1056/NEJMoa2107322
- [4] Buck AK, Serfling SE, Kraus S et al. Theranostics in Hematooncology. *J Nucl Med* 2023; 64 (7): 1009–1016. doi:10.2967/jnumed.122.265199
- [5] Chatterjee S, Behnam Azad B, Nimmagadda S. The intricate role of CXCR4 in cancer. *Adv Cancer Res* 2014; 124: 31–82. doi:10.1016/B978-0-12-411638-2.00002-1
- [6] Demmer O, Gourni E, Schumacher U et al. PET imaging of CXCR4 receptors in cancer by a new optimized ligand. *ChemMedChem* 2011; 6 (10): 1789–1791. doi:10.1002/cmdc.201100320
- [7] Shekhawat AS, Singh B, Malhotra P et al. Imaging CXCR4 receptors expression for staging multiple myeloma by using (68)Ga-Pentixafor PET/CT: comparison with (18)F-FDG PET/CT. *Br J Radiol* 2022; 95: 20211272
- [8] Chen Z, Yang A, Zhang J et al. CXCR4-Directed PET/CT with [(68)Ga]-Pentixafor in Central Nervous System Lymphoma: A Comparison with [(18)F]FDG PET/CT. *Mol Imaging Biol* 2022; 24 (3): 416–424
- [9] Duell J, Krummenast F, Schirbel A et al. Improved Primary Staging of Marginal-Zone Lymphoma by Addition of CXCR4-Directed PET/CT. *J Nucl Med* 2021; 62 (10): 1415–1421. doi:10.2967/jnumed.120.257279
- [10] Buck AK, Haug A, Dreher N et al. Imaging of C-X-C Motif Chemokine Receptor 4 Expression in 690 Patients with Solid or Hematologic Neoplasms Using (68)Ga-Pentixafor PET. *J Nucl Med* 2022; 63 (11): 1687–1692
- [11] Buck AK, Grigoleit GU, Kraus S et al. C-X-C Motif Chemokine Receptor 4-Targeted Radioligand Therapy in Patients with Advanced T-Cell Lymphoma. *J Nucl Med* 2023; 64 (1): 34–39
- [12] Buck AK, Serfling SE, Lindner T et al. CXCR4-targeted theranostics in oncology. *Eur J Nucl Med Mol Imaging* 2022; 49 (12): 4133–4144. doi:10.1007/s00259-022-05849-y
- [13] Zucca E, Arcaini L, Buske C et al. Marginal zone lymphomas: ESMO Clinical Practice Guidelines for diagnosis, treatment and follow-up. *Ann Oncol* 2020; 31 (1): 17–29. doi:10.1016/j.annonc.2019.10.010
- [14] Duell J, Schneid S, Kosmala A et al. CXCR4-gerichtete PET/CT in 100 Patient:innen mit Marginalzonenlymphom -Diagnostische Performance, Vorhersagepotenzial und Eignung für CXCR4-Endoradiotherapie. *Nuklearmedizin* 2023; 62: 95
- [15] Zucca E, Dreyling M, Group EGW. Gastric marginal zone lymphoma of MALT type: ESMO Clinical Practice Guidelines for diagnosis, treatment and follow-up. *Ann Oncol* 2010; 21: v175–176
- [16] Stollberg S, Kammerer D, Neubauer E et al. Differential somatostatin and CXCR4 chemokine receptor expression in MALT-type lymphoma of gastric and extragastric origin. *J Cancer Res Clin Oncol* 2016; 142 (11): 2239–2247. doi:10.1007/s00432-016-2220-6
- [17] Haug AR, Leisser A, Wadsak W et al. Prospective non-invasive evaluation of CXCR4 expression for the diagnosis of MALT lymphoma using [(68)Ga]Ga-Pentixafor-PET/MRI. *Theranostics* 2019; 9 (12): 3653–3658. doi:10.7150/thno.31032
- [18] Mayerhoefer ME, Raderer M, Lamm W et al. CXCR4 PET/MRI for follow-up of gastric mucosa-associated lymphoid tissue lymphoma after first-line *Helicobacter pylori* eradication. *Blood* 2022; 139 (2): 240–244. doi:10.1182/blood.2021013239
- [19] Herrmann K, Schottelius M, Lapa C et al. First-in-Human Experience of CXCR4-Directed Endoradiotherapy with 177Lu- and 90Y-Labeled Pentixafor in Advanced-Stage Multiple Myeloma with Extensive Intra- and Extramedullary Disease. *J Nucl Med* 2016; 57 (2): 248–251
- [20] Sugiyama T, Kohara H, Noda M et al. Maintenance of the hematopoietic stem cell pool by CXCL12-CXCR4 chemokine signaling in bone marrow stromal cell niches. *Immunity* 2006; 25 (6): 977–988. doi:10.1016/j.immuni.2006.10.016
- [21] Horwitz S, O'Connor OA, Pro B et al. Brentuximab vedotin with chemotherapy for CD30-positive peripheral T-cell lymphoma (ECHOLON-2): a global, double-blind, randomised, phase 3 trial. *Lancet* 2019; 393: 229–240
- [22] Sabattini E, Pizzi M, Tabanelli V et al. CD30 expression in peripheral T-cell lymphomas. *Haematologica* 2013; 98 (8): e81–82. doi:10.3324/haematol.2013.084913
- [23] Saleh K, Michot JM, Ribrag V. Updates in the Treatment of Peripheral T-Cell Lymphomas. *J Exp Pharmacol* 2021; 13: 577–591. doi:10.2147/JEP.S262344
- [24] Schottelius M, Herrmann K, Lapa C. In Vivo Targeting of CXCR4-New Horizons. *Cancers (Basel)* 2021; 13 (23): 5920. doi:10.3390/cancers13235920.
- [25] Accessed June 09, 2023 at: <https://pentixapharm.com/development-program.html>
- [26] Relevance of [68Ga]Ga -Pentixafor-PET for Initial Staging and Therapeutic Evaluation of Multiple Myeloma in First Line Treatment (Penti-Myelo). Accessed May 22, 2023 at: <https://clinicaltrials.gov/ct2/show/NCT04561492?term=pentimelo&draw=2&rank=1>
- [27] In-Human CXCR4 Imaging of Blood Cancers Using [68Ga]-Pentixafor-PET. Accessed May 22, 2023 at: <https://clinicaltrials.gov/ct2/show/NCT05093335>
- [28] Eckert & Ziegler Receives Green Light for Phase III Study with PENTIXA-FOR. Accessed May 22, 2023 at: <https://pentixapharm.com/news.html>