

## Panel 2.8 Technology and Design

### Designing footwear and braces for children with clubfoot deformity

GANESAN Balasankar, LUXIMON Ameersing\* & YIP Yiu Wan

Institute of Textiles and Clothing, The Hong Kong Polytechnic University, Hung Hom, Hong Kong,

\*Email: [tcshyam@polyu.edu.hk](mailto:tcshyam@polyu.edu.hk)

Clubfoot, footwear, orthosis, design, Kinect

#### Abstract

Congenital Talipes Equinovarus (CTEV) is a complex foot deformity characterized by the following four structural changes, which occur in the foot and ankle: ankle equinus, hind foot varus, forefoot adductus and cavus. It occurs one in 1000 live births and is more common in male than female children. For the healthy subjects, the three-dimensional foot shape can be obtained from a 3D foot scanner and this is useful for the design of footwear. In the last 10 years, most studies have focused on 3D laser scanning technology and digital imaging procedure to quantify the shape of the foot of healthy subjects. In the previous literature, quantification of foot shape, gender difference, foot shape classification, and plantar pressure studies have been carried for normal human feet. Although there are advanced developments in technology, the use of 3D scanning technology for clubfoot is still at its infancy status. Moreover, development of footwear and specification of footwear prescription is still in the early stage. The main correction method is the use of orthosis. Due to the use and design of hard orthosis, there are clubfoot recurrences, and other complications such as pressure sores and pain. Moreover, slippage of footwear with Dennis brown bar occurs due to unfitted wearing of clubfoot footwear with braces. The design of custom orthosis is also time consuming and requires a manual procedure that is sometimes expensive. Therefore, this novel study aims to develop a 3D clubfoot model and rapid prototyping orthosis by using cheaply commercially available 3D Kinect scanner. Also a conceptual footwear design is proposed to correct the foot.

#### 1. Introduction

Congenital Talipes Equinovarus (CTEV) is a complex foot deformity in children. It is characterized by the following four structural changes occur in the foot and ankle: ankle equinus, hindfoot varus, forefoot adductus and cavus (Houston et al. 2006). It occurs one in 1000 live births and is more common in male than female children (Foster & Davis, 2006; Dobbs & Gurnett, 2009). However, the incidence of clubfoot varies from 0.9 to 7 per live births (Matanovic et al., 2011). The club foot incidence rate is very low (0.6 %) in the Chinese population and is high (6.8%) among Polynesian population. Clubfoot can be easily recognized at birth but it differs from the mild to extremely rigid type (Dobbs & Gurnett, 2009). These differences in severity can be evaluated by using the Pirani or Dimeglio et al. scoring system (Pirani et al. 1999; Dimeglio et al.,

1995). Children with untreated or neglected clubfoot experience severe limitation in wearing normal footwear and mobility. In addition, walking with the dorsal side of the neglected or untreated clubfoot will create other complications such as callus formation, skin injuries and infection of the foot (Dobbs & Gurnett, 2009).

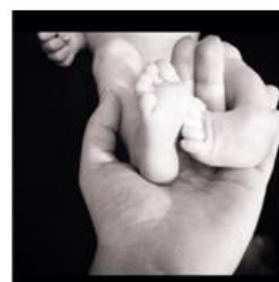

Figure 1. Unilateral clubfoot (2weeks baby)

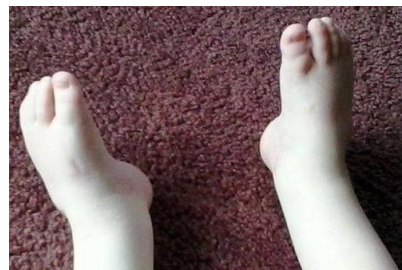

Figure 2. Bilateral clubfoot -2 years old child

#### 1.1 Management of clubfoot

Clubfoot management is usually determined by its primary etiology and it can be corrected by either conservative or surgical management (Matanovic et al., 2011). The conservative treatment for clubfoot, manipulation followed by immobilization, has been developed by Hippocrates in 400 BC. Nowadays, conservative corrective options include the French method, the Ponseti method (manipulation, casting, Achilles tendon tenotomy, a with foot abduction brace), physical procedures such as thermotherapy, kinesio therapy, electro therapy, splints, shoe modification and using orthotic devices (Kruse et al., 2009; Utrilla-Rodriguez et al. 2012). However, several authors reported that the Ponseti method is more effective than other methods, because it has a more long-term effective success rate. In the

Ponseti method, manipulation, casting, Achilles tendon tenotomy, and a foot abduction brace, have been used to correct the deformity. The Ponseti method alleviates the stiffness and pain, avoids the surgical procedure and avoids overcorrection (Laaveg& Ponseti,1980).

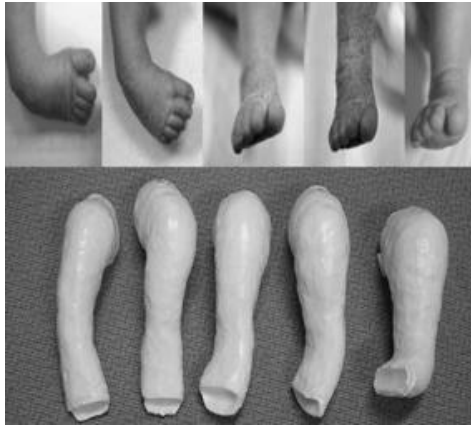

Figure 3. Serial casting method in a various weeks (Bergerault& Fournier, 2012)

### 1.2 Role of Footwear and abduction orthosis in clubfoot management

Generally, there are two conservative methods (The Ponseti method and the Kite method) that use footwear and the features of footwear described. Once the foot is fully corrected by the Ponseti method, the Dennis Brown splint with open toe tarso-pronator footwear is recommended; the splint should set the foot at a 70 degree external rotation to maintain the correction. If the child is affected by unilateral clubfoot, the unaffected side of the foot needs to be kept in a 30 to 45 degree external rotation to maintain the abduction of forefoot and calcaneus, and to stretch the medial side of the soft tissue. At the beginning, the child needs to wear the splint 24 hours a day, then only at night time with the open toe box, Thomas reverse heel, straight medial border and lateral flaring of the sole until age of four to 5 years (Kite, 1972).

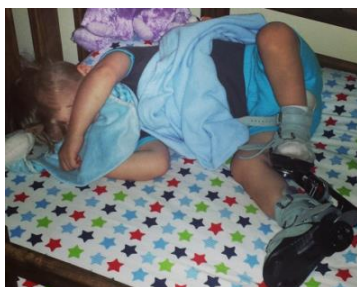

Figure 4. Boots and bar at night time

Another conservative method is called the Kite method. In this method, repeated manipulation and casting is used to correct the heel varus,

ankle equinus, and forefoot adduction. Manipulation is performed by using pressure over the calcaneo-cuboid joint followed by toe to groin casting for every seven to ten days until full correction. The next step is to wear the full time splint with heel lock to avoid the varus, and medial bar used to avoid the adduction. Patients may only require the splint at night if they are able to walk. Special footwear is typically required until the age of 4 to 5 years. The footwear should have the Thomas reverse heel, open toe box, lateral flaring of the sole, and straight medial border (Kite,1939; Changulani et al. 2006). Some of the clubfoot shoes are shown in the following figure.6

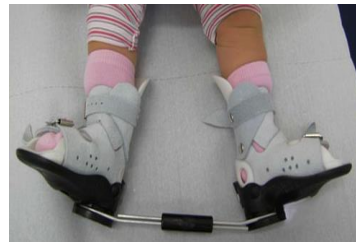
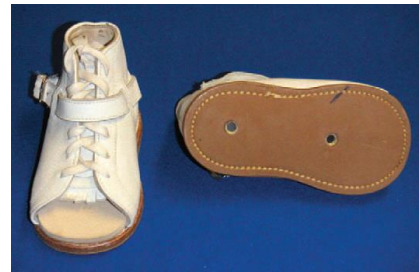
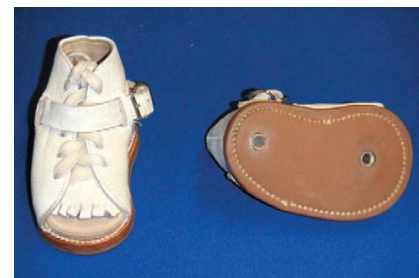Figure 5. Foot abduction orthosis- Dennis Brown bar (Source: Force & Davis, 2007; Westhoff&Krauspe, 2013).



Open toes straight shoes



Open toes abducted last shoes

Figure 6.club foot shoes (Source:Casell , 2004)

## 2. Methods

### 2.1 Participants

A two-year old boy with bilateral clubfoot was recruited from the Guangzhou rehabilitation hospital for this study. The parents were instructed to fill the consent form. Demographic data were collected such as age, gender and type of clubfoot. He was diagnosed with bilateral clubfoot since birth. In this study, the right side clubfoot of subject was selected to scan and develop the 3D clubfoot model.

### 2.1 Equipment

Generally, the 3D foot scanner is very expensive. In 2012, Microsoft introduced 3D scanner equipment called Kinect. The Kinect has several features such as LED, vision sensor, 3D depth sensor and microphone array (Figure.7). Recently, the Kinect scanner has been used in various applications such as clinical analysis tool, 3D scanner, and gesture based computer interaction tool. In addition, Kinect can be used to get the accurate anthropometric measurements of foot (Karol & Jeans, 2011). By manually using Kinect 3D scanner, we can get the 360 degree image of the club foot.

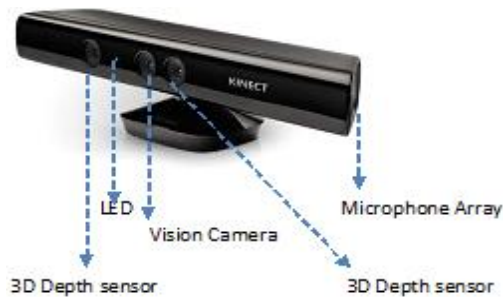


Figure 7. Kinect 3D Scanner

### 2.3 Experiment procedure 1

The subject was instructed to stand with the support of parent. Initially, the clubfoot photos were taken by examiner before starting the experiment (Figure. 8). After that, the investigator used the Kinect scanner manually around the clubfoot to get the 3D images.

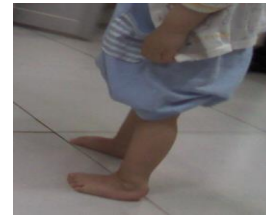
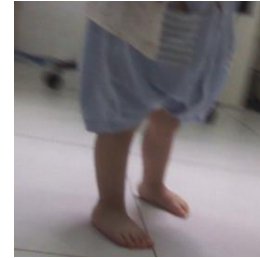
Figure 8. Images of bilateral clubfoot after two years of AFO management

## 3. Results

These scanned 3D images were stored into the computer and processed by the help of Artec Studio 9. After the process of images by the help of Artec studio 9 software, the results of 3D clubfoot model as shown in figure 8.

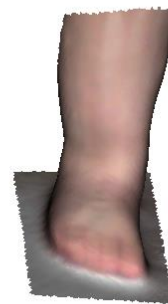

Figure 9. Right side 3D Clubfoot

### Development of modified footwear for clubfoot deformity

Newly designed clubfoot footwear was developed along with this 3D clubfoot model. The researchers of this study developed several features in the newly designed footwear to correct the clubfoot

deformity (Figure 10). The features are: increased thickness of outsole up to the level of ankle joint, moderate level of thickness of insole. Outsole thickness of footwear is increased up to the level of ankle joint to control the foot in the normal position. Heal counter developed with firm thickness and height increased above the level of ankle joint to maintain the stability and keep the ankle joint in a normal alignment position.



Figure 10. Newly designed clubfoot footwear

#### 4. Discussion and conclusion

The results of Kinect 3D data provide the accurate shape of clubfoot and a 3D clubfoot model. This low cost Kinect based 3D clubfoot model will be used to design the suitable footwear or splint with fit and comfort. In addition, this would also be helpful to various experts such as footwear designers, orthotists, surgeons and other health care professionals to better understand clubfoot, clubfoot evaluation and clubfoot management. In addition, further research will be conducted with a larger sample size, and newly designed clubfoot footwear effectiveness will be tested. In general future research is required for footwear modifications and management of clubfoot.

#### 5. Acknowledgements

This study is supported by Hong Kong polytechnic University research funds (G-UA2A).

#### 6. References

- Bergerault, F., Fournier, J., & Bonnard, C. (2013). Idiopathic congenital clubfoot: Initial treatment. *Orthopaedics & Traumatology: Surgery & Research*, 99, S150-159.
- Changulani, M., Garg, N.K., Rajagopal, T.S., Bass, A., Nayagam, S.N., Sampath, J., & Bruce, C.E.(2006) Treatment of idiopathic clubfoot using the Ponseti method. Initial experience. *The Journal of Bone & Joint Surgery (British Volume)*, 88, 1385-1387.
- Dimeglio, A., et al.(1995). Classification of clubfoot. *Journal of Pediatric Orthopedics B*, 4, 129-36.
- Dobbs, M.B., &Gurnett, C.A.(2009). Update on Clubfoot: Etiology and Treatment. *Clinical Orthopedics and Related Research*, 467, 1146-1153.
- Foster, A. & Davis, N. (2006). Congenital talipesquinovarus (clubfoot). *Surgery, Surgery*, 25, 171-175.
- Houston, V.L., Luo, G., Mason, C.P., Mussman, M., Garbarini, M.,& Beattie, A.C.(2006). Changes in Male Foot Shape and Size with Weight bearing. *Journal of the American Podiatric Medical Association*, 96,330-343.
- Karol, L.A., & Jeans, K.A.(2011). Assessment of Clubfoot Treatment Using Movement Analysis. *Journal of Experimental & Clinical Medicine*, 3, 228-232.
- Kite, J.H.(1972). Nonoperative treatment of congenital clubfoot. *Clinical Orthopedics and Related Research*,84,29-38.
- Kite, J.H.(1939). Principles involved in treatment of clubfoot. *The Journal of Bone and Joint Surgery*. 21(3):595-606.
- Kruse, L., Gurnett, C.A., Hootnick, D.,& Dobbs, M.B.(2009). Magnetic Resonance Angiography in Clubfoot and Vertical Talus Feasibility Study. *Clinical Orthopedics and Related Research*,467, 1250-1255.
- Laaveg, S.J., Ponseti, IV.(1980). Long-term results of treatment of congenital clubfoot. *The Journal of Bone and Joint Surgery*, 62, 23-31.
- Matanovic, D.D., Vukasinovic, Z.S., Zivkovic, Z.M., SPasovski, D.V., Bascarevic, Z.L., & Slavkovic, N.S. (2011). Physical treatment of of foot deformities in childhood, *Actachirlugosl*, 58,113-116.
- Pirani, S., Outerbridge, H.K., Sawatzky, B., Stothers, K. (1999).A reliable method of clinically evaluating a virgin clubfoot evaluation. *21st SICOT Congress 1999*.

Utrilla-Rodriguez, E.M., Martinez, C.A., navete MG, ConejeroCasares PA.(2012). Conservative Treatment of Clubfoot Using Modified Copenhagen Method.*Pediatric physical therapy*, 24, 51-56.

## 6. Authors



Mr. Balasankar GANESAN, a PhD student under supervision of Dr. Ameersing Luximon, in the Institute of Textiles and Clothing, The Hong Kong Polytechnic University, Hung Hom, Kowloon, Hong Kong. His research includes clubfoot and its management.



Dr. Ameersing LUXIMON is currently an Assistant Professor in the Institute of Textiles and Clothing, The Hong Kong Polytechnic University, Hung Hom, Kowloon, Hong Kong. His research includes foot and footwear, digital human modeling and ergonomics.



Dr Joanne Yiu Wan YIP is currently a Lecturer in the Institute of Textiles and Clothing, The Hong Kong Polytechnic University, Hung Hom, Kowloon, Hong Kong. Her research includes textile material science; intimate garment design; and scoliosis and motion control.