

**Title:** Ultrasound Palpation Sensor for Tissue Thickness and Elasticity Measurement - Assessment of Transverse Carpal Ligament

**Authors:** Y. P. Zheng<sup>a</sup>, Z.M<sup>b</sup>. Li, A. P. C. Choi<sup>a</sup>, M. H. Lu, X<sup>a</sup>. Chen, Q.H. Huang<sup>a</sup>

**Address:** <sup>a</sup> Department of Health Technology and Informatics, The Hong Kong Polytechnic University, Kowloon, Hong Kong SAR, China

<sup>b</sup> Hand Research Laboratory, Department of Orthopaedics, University of Pittsburgh, United States

**Abstract:** Palpation is a traditional diagnostic procedure for health care professionals to use their fingers to touch and feel the body soft tissues. It is a common clinical approach, though it is rather subjective and qualitative and the palpation results may vary among different people. Tissue ultrasound palpation sensor (TUPS) provides a feasible solution that makes the palpation of soft tissues not subjective feeling any more. It is comprised of an ultrasound transducer together with a load cell to form the finger-sized probe. The probe is used to push against the soft tissue surface to measure the thickness and elasticity of the soft tissues. TUPS has been successfully applied to the assessment of various human tissues. Recently, we have improved TUPS, which can now be linked to personal computer (PC) via universal serial bus (USB) and provide a better user-interface. The information of ultrasound signal and indentation force is displayed on PC in real time during measurement. In this paper, we introduce the recent application of TUPS for the assessment of the transverse carpal ligament. The tissues at the carpal tunnel regions of five normal male subjects were tested using TUPS. The results showed that the average thickness of the tissues covering the carpal tunnel ligament and the tunnel region was  $7.98 \pm 1.05\text{mm}$  and  $9.59 \pm 1.12\text{mm}$ , respectively. Under a compression force of 20N applied by a cylindrical ultrasound indenter with a diameter of 9mm, the stiffness of the soft tissue layer and the tunnel region was  $6.72 \pm 2.10\text{ N/mm}$  and  $15.63 \pm 8.42\text{ N/mm}$ , respectively. It is expected that TUPS can be a potential tool for non-invasive assessment of carpal tunnel syndrome.

**Keywords:** Palpation, ultrasound, ultrasound palpation, tissue elasticity, soft tissue, carpal tunnel syndrome

**Corresponding author:**

Yong-Ping Zheng, PhD.

Department of Health Technology and Informatics,

The Hong Kong Polytechnic University,

Hung Hom, Kowloon, Hong Kong SAR, P.R.China

Tel: 852-27667664

Fax: 852-23624365

Email: [ypzheng@ieee.org](mailto:ypzheng@ieee.org)

1 **1. Introduction**

2 Carpal tunnel syndrome (CTS) is a common musculoskeletal disease caused by the  
3 compression to the median nerve in the carpal tunnel. As median nerve is a mixed motor  
4 and sensory peripheral nerve, compression of it may cause losing of sensation, clumsy  
5 and even powerless of the palm sides from the medial half of thumb to the lateral half of  
6 the ring finger [1]. There are several clinical tests for CTS to check the sensory and  
7 mobility of the hand including provocative tests, Phalen’s test and Tinel percussion test  
8 [1]. However, the appearance of these clinical symptoms of CTS means that the patient  
9 may suffer from CTS severely. If we can develop a non-invasive approach to test the  
10 thickness and elasticity at the carpal tunnel region, it might be feasible to be a tool for  
11 diagnosing of CTS in the early states. So, health care professionals may apply non-  
12 surgical management such as anti-inflammatory drugs injection or hand support for  
13 neutral position to release the carpal tunnel pressure [1, 2]. It is because surgical  
14 management, which cuts the transverse carpal ligament (TCL), can help to release the  
15 carpal tunnel pressure (CTP) but it may cause the weakness of finger flexion [3].

16 TCL forms the volar aspect of the carpal tunnel at the wrist. The increase of CTP  
17 may be due to fluid retention, infection and excessive use of the fingers, which may cause  
18 swelling of the tendons or their synovial sheaths [4]. In pervious studies, TCL was found  
19 to be thickened with the increase of the CTP and it is relevance to CTS [5, 6]. In this  
20 study, the newly developed version of ultrasound palpation sensor (TUPS) was used to  
21 examine the thickness and the stiffness of the carpal tunnel in-vivo.

22 TUPS has been used to determine different kinds of soft tissues including residual  
23 limb tissues [7], burn and surgical scars [8], fibrotic tissues induced by radiotherapy [9]

1 and plantar foot tissues with diabetes [10]. The studies mentioned above considered the  
2 soft tissue and measured the tissue thickness and elasticity in whole. In this CTS study,  
3 an improved version of TUPS and its software were used in order to consider the soft  
4 tissues in the wrist region into two layers which are the soft tissues superior and interior  
5 to the TCL. Therefore, we are able to estimate the effects of the TCL to CTP.

6

## 7 **2. Methods**

8 TUPS is an ultrasound indentation with a finger size probe which consists of 5MHz  
9 ultrasound transducer with a diameter of 9mm and an in series load cell [11]. Fig 1  
10 shows the block diagram of the TUPS system. Ultrasound was emitted from the  
11 ultrasound transducer to measure the thickness and deformation of different layers in the  
12 wrist region during indentation using the information of the time-of-flight and the sound  
13 speed. The average sound speed in soft tissues of human body was assumed to be 1540  
14 m/s [12]. The load cell was used to record the indentation force. In this study, 20N force  
15 was applied to the subject's palm via the measuring probe within 3 second.

16 Fig 2 shows the user interface of the custom-developed program for the TUPS  
17 system. It can show the ultrasound and force signals during indentation in real time.  
18 The ultrasound signal can also be shown in M-mode to present the overall displacement  
19 profile of the ultrasound echoes reflected or scattered from the tissues at different depths.  
20 As we introduced in earlier papers [9, 11], signal peak or cross-correlation tracking  
21 approaches could be used to track the shift of a selected echo, which corresponded to a  
22 tissue interface, such as tunnel-bone interface. However, these methods could not be  
23 well used for the ultrasound signals collected in this study. Since the applied load was

1 very large and tissues were deformed significantly, the tracking using signal peak or  
2 cross-correlation for a segment of signals did not work very well for the interfaces of  
3 TCL due to the obvious change of the interface echoes (de-correlation). In this study, we  
4 used the M-mode image to trace the shift of echoes quasi-automatically by selecting a  
5 number of critical points in the M-mode image for each interface echo under different  
6 loading levels. As an example, two groups of manually selected points were shown in  
7 the M-mode image of Fig 2. The software then automatically links the points together to  
8 form a deformation profile under different loads using a linear interpolation. Normally,  
9 at least 10 points were manually selected for tracking of each interested interface echo.  
10 The obtained deformation-time data were then further analyzed together with load-time  
11 data to obtain the stiffness information.

12 Five normal male subjects were recruited in this study with an average age of 29.8  
13  $\pm$  5.1 years old. They have no neuro-musculoskeletal disorders in their upper limbs. The  
14 location for the indentation of the palm is on the skin overlying the TCL. A line was  
15 firstly drawn to connect the palpable pisiform and scaphoid and a point 10mm distal from  
16 the mid-point of this line was marked as the centre of indentation. During the testing, the  
17 hand was supinated on a testing table with the palm side facing upward. 10 trails were  
18 recorded for each subject.

19

### 20 **3. Results**

21 The ultrasound echoes reflected from the carpal bone surfaces were obviously  
22 identified (Fig 2 and Fig 3). The original thickness of the tissues between the skin and the  
23 TCL and between the TCL and bone surface were  $7.98 \pm 1.05\text{mm}$  and  $9.59 \pm 1.12\text{mm}$ ,

1 respectively, for the 5 subjects. We applied about 5N to compress the soft tissue between  
2 the skin surface and TCL, it is because the stiffness of that layer was assumed to be softer.  
3 In the M-mode display of ultrasound signals as shown in Fig 2, we can observe that the  
4 level of deformation is different between the layer of skin-TCL and TCL-Carpal bone.  
5 Figs 3a, 3b and 3c show the ultrasound echo trains and different tissue interfaces obtained  
6 with the applied load of 0 N, 5 N and 20 N, respectively. In Table 1, the total  
7 deformations in skin-TCL layer and TCL-carpal bone layer are  $3.18 \pm 0.75\text{mm}$  and  $1.16$   
8  $\pm 0.42\text{mm}$ , which are 38.1% and 13.7% respectively when the indentation force is up to  
9 20N. When the indentation is less than 5N, the deformation of skin-TCL layer is  $2.2\text{mm}$   
10  $\pm 0.8\text{mm}$  as the deformation of TCL-carpal bone layer is  $0.65\text{mm} \pm 0.25\text{mm}$  only, which  
11 is 4 times larger. When the indentation force is between 5N to 20N, the deformation of  
12 skin-TCL layer is  $0.98 \pm 0.51\text{mm}$  as the deformation of TCL-carpal bone layer is  $0.50 \pm$   
13  $0.20\text{ mm}$ , which is 2 times larger. Therefore, the stiffness of TCL-carpal bone layer is  
14 much larger than the skin-TCL layer and it is deformation dependent.

15 The stiffness of soft tissues and carpal tunnel layer under different indentation load  
16 were shown in Table 2. We found that the difference of stiffness between two layers  
17 keeps reducing when the indentation force increases. The overall stiffness of skin-TCL  
18 layer and TCL-carpal bone layer are  $6.72 \pm 2.10\text{ N/mm}$  and  $15.63 \pm 8.42\text{ N/mm}$ ,  
19 respectively.

20

#### 21 **4. Discussion**

22 In this study, we developed the TUPS system together with the program to perform  
23 the indentation on the wrist region. The new developments of TUPS system and its

1 program not only provide the real time information of ultrasound and force signal to the  
2 operator during indentation, but also provide a feasible solution to distinguish different  
3 tissue layers rather than overall information of tissue thickness and elasticity. By the help  
4 of M-mode display of ultrasound in the user-interface of the program, we tried to  
5 distinguish TCL in the wrist region so as to study the deformation and the elasticity of  
6 skin-TCL (soft tissues) layer and TCL-carpal bone (Carpal Tunnel) layer. The results  
7 from Table 2 show that the stiffness of skin-TCL layer is 2.60 times less than TCL-carpal  
8 bone layer when the indentation force is below 5N. The results proved the assumption  
9 that the stiffness of the skin-TCL layer should be less than that of TCL-carpal bone layer.

10 However, when the indentation force is larger than 15N, the stiffness of skin-TCL  
11 and TCL-carpal bone layer become similar (1.15 times larger), so the deformation of the  
12 whole thickness is contributed relatively closer by both two layers. Therefore, we may try  
13 to study the stiffness and deformation of TCL-carpal bone layer during the indentation  
14 when the force is between 5N to 20N. The stiffness of TCL-carpal bone layer in this  
15 study is  $21.76 \pm 10.00\text{N/mm}$ .

16 Since a relative large load was required to deform the carpal tunnel, the profile of  
17 the ultrasound echo from a certain interface could significantly change, particularly that  
18 from TCL. Automatic tracking methods using signal peak or cross-correlation that we  
19 earlier developed could not work well in this study. We developed a quasi-automatic  
20 measurement method to trace the shift of echoes by manually selecting critical points in  
21 the M-mode display of ultrasound images. The manual selection of the points involved  
22 subjective judgements. Therefore, inter- and intra-operator variations of the measurement  
23 should be further documented in future studies. In addition, these manual operation also

1 limited the option to obtain the tissue deformation data in real-time during the test. We  
2 plan to develop more robust automatic tracking algorithms to precisely tracking the echo  
3 movement of tissue interface using the ultrasound signals. The ultrasound signals were  
4 digitized in 100 MHz, which corresponds to a displacement measurement resolution of  
5 approximately 8  $\mu\text{m}$  if the echo did change its profile during the compression and could  
6 be automatically tracked, such as the echo reflected from the bone surface. However,  
7 manual selection for the points in this study could significantly affect the measurement  
8 accuracy. Further study will be required to systematically investigate the measurement  
9 accuracy under various conditions of the echo.

10 Another limitation of the reported method is that the measured stiffness value could  
11 be affected by the boundary condition of the carpal tunnel region. When a certain load  
12 was applied at the carpal tunnel region, the deformations of different tissue components  
13 might not only be controlled by the tissue elasticity, but also affected by the surrounding  
14 boundary conditions. Therefore, the stiffness value measured from different subjects  
15 could be affected by the dimension of the carpal tunnel region. The boundary conditions  
16 should be taken into account in the extraction of the stiffness from the load-deformation  
17 data in the future studies.

18 In spite of the above limitations, this study demonstrate the feasibility of the novel  
19 approach of using TUPS to measure the tissue thickness and elasticity of TCL which is  
20 very relevant to CTS. In future study, a higher frequency ultrasound (such as 20 MHz  
21 focused ultrasound) should be used to detect the TCL layer. It is because the resolution of  
22 the 5 MHz ultrasound may not be enough to distinguish the TCL easily. Afterward,

1 subjects with CTS should be recruited to perform the indentation to compare the  
2 difference of tissue thickness and stiffness between normal subjects and CTS patients.

3

#### 4 **Acknowledgements**

5 This work was partially supported by The Hong Kong Polytechnic University (G-  
6 YE22) and the Research Grants Council of Hong Kong (PolyU 5245/03E).

7

#### 8 **References**

- 9 [1] C. Love, Carpal tunnel syndrome, *Journal of Orthopaedic Nursing* 7 (2003) 33-42.
- 10 [2] T. Armstrong, W. Devor, L. Borschel, R. Contreras, Intracarpal steroid injection is  
11 safe and effective for short term management of carpal tunnel syndrome, *Muscle &*  
12 *Nerve* 29 (2004) 82-88.
- 13 [3] D. Netscher, A. Mosharrafa, M. Lee, C. Polsen, H. Choi, A. K. Steadman, J.  
14 Thornby, Transverse carpal ligament: Its effect on flexor tendon excursion  
15 morphologic changes of the carpal canal, and on pinch and grip strengths after open  
16 carpal tunnel release, *Plastic and Reconstructive Surgery*, 100 (1997), 636-642.
- 17 [4] K. L. Moore, A. F. Dalley, *Clinical Oriented Anatomy*, Lippincott Williams and  
18 Wilkins, Philadelphia, 1999.
- 19 [5] V. John, H. E. Nau, H. C. Nahser, V. Reinhardt, K. Venjakob, CT of carpal tunnel  
20 syndrome, *American Journal of neuroradiology*, 4 (1983), 770-772.
- 21 [6] B. M. Sucher, R. N. Hinrichs, Manipulative treatment of carpal tunnel syndrome:  
22 biomechanical and osteopathic intervention to increase the length of the transverse



1       carpal ligament, *Journal of the American Osteopathic Association*, 98 (1998) 679-  
2       679.

3 [7] Y. P. Zheng, A. F. T. Mak, Effective elastic properties for lower limb soft tissues  
4       from manual indentation experiment, *IEEE Transactions on rehabilitation*  
5       *Engineering*, 7 (1999) 257-267.

6 [8] J. C. M. Lau, C. W. P. Li-Tsang, Y. P. Zheng, Application of tissue ultrasound  
7       palpation system (TUPS) in objective scar evaluation, *Burns*, 31 (2005) 445-452.

8 [9] Y. P. Huang, Y. P. Zheng, S. F. Leung, Quasi-linear viscoelastic properties of  
9       fibrotic neck tissues obtained from ultrasound indentation tests in vivo, *Clinical*  
10       *Biomechanics* 20 (2005) 145-154.

11 [10] Y. P. Zheng, Y. K. C. Choi, K. Wong, S. Chan, A. F. T. Mak, Biomechanical  
12       assessment of plantar foot tissue in diabetic patients using an ultrasound indentation  
13       system, *Ultrasound in Medicine and Biology*, 26 (2000) 451-456.

14 [11] Y. P. Zheng, A. F. T. Mak, An ultrasound indentation system for biomechanical  
15       properties assessment of soft tissues in-vivo, *IEEE Transactions of Biomedical*  
16       *Engineering*, 43 (1996) 912-918.

17 [12] S. A. Goss, R. L. Johnston, F. Dunn, Compilation of empirical ultrasonic properties  
18       of mammalian tissues, *Journal of the Acoustical Society of America*, 68 (1980) 93-  
19       108.

20  
21  
22

1 **Table 1** Deformation (mm) of the skin-TCL layer and TCL-carpal bone layer under  
 2 different indentation load (5N and 20N).

Force	Skin-TCL layer	TCL-carpal bone layer
0 - 5N	2.20 ± 0.80	0.65 ± 0.25
5 - 20N	0.98 ± 0.51	0.50 ± 0.20
Overall	3.18 ± 0.75	1.16 ± 0.42

3

4

5

6 **Table 2** Stiffness (N/mm) of the skin-TCL layer and TCL-carpal bone layer under  
 7 different indentation load (5N and 20N).

Force	Skin-TCL layer	TCL-carpal bone layer
0 - 5N	3.51 ± 1.69	9.11 ± 5.83
5 - 20N	18.98 ± 7.73	21.76 ± 10.00
Overall	6.72 ± 2.10	15.63 ± 8.42

8

9

## 10 **Figure Captions**

11 **Fig. 1** Schematic of the TUPS system including the finger size probe together with other  
 12 electronic parts as a control system of the load cell and ultrasound transducer. The control  
 13 unit can be directly linked with personal computer via USB to have fast transmission of  
 14 signals as real time measurement.

15

1 **Fig. 2** User program which was used during indentation. In this interface, TUPS connects  
2 to PC via USB to transmit the ultrasound signal (the bottom window) and force signal  
3 (the top right window). The top left window was used in the signal processing for  
4 showing the displacement curve or global view for the whole tissue (M-mode). **The**  
5 **points in the M-mode display were manually selected to represent the shifts of the echoes**  
6 **during the loading process.**

7  
8 **Fig. 3** A sample result of ultrasound signals of a carpal tunnel. (a) Echoes obtained with  
9 no compression, (b) echoes obtained during indentation when about 5N was applied, (c)  
10 echoes obtained during indentation when totally 20N was applied.

11  
12  
13

1

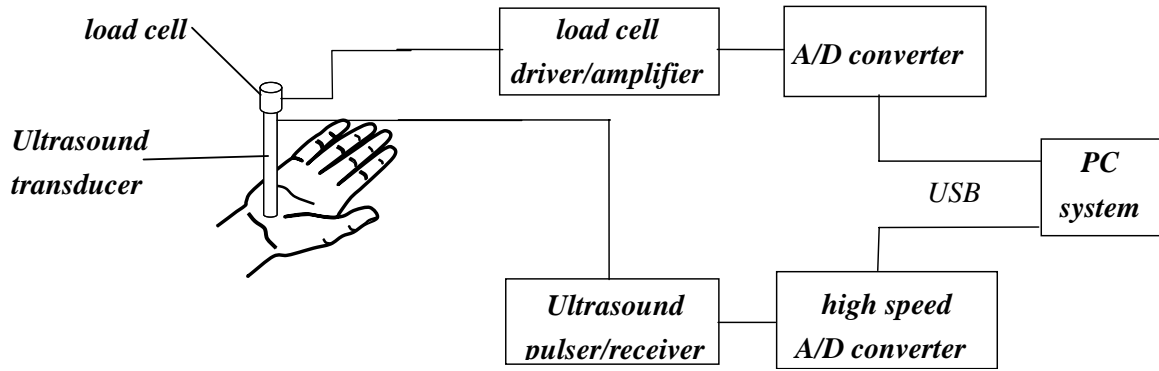


Fig. 1

2

3

4

5

6

7

8

9

10

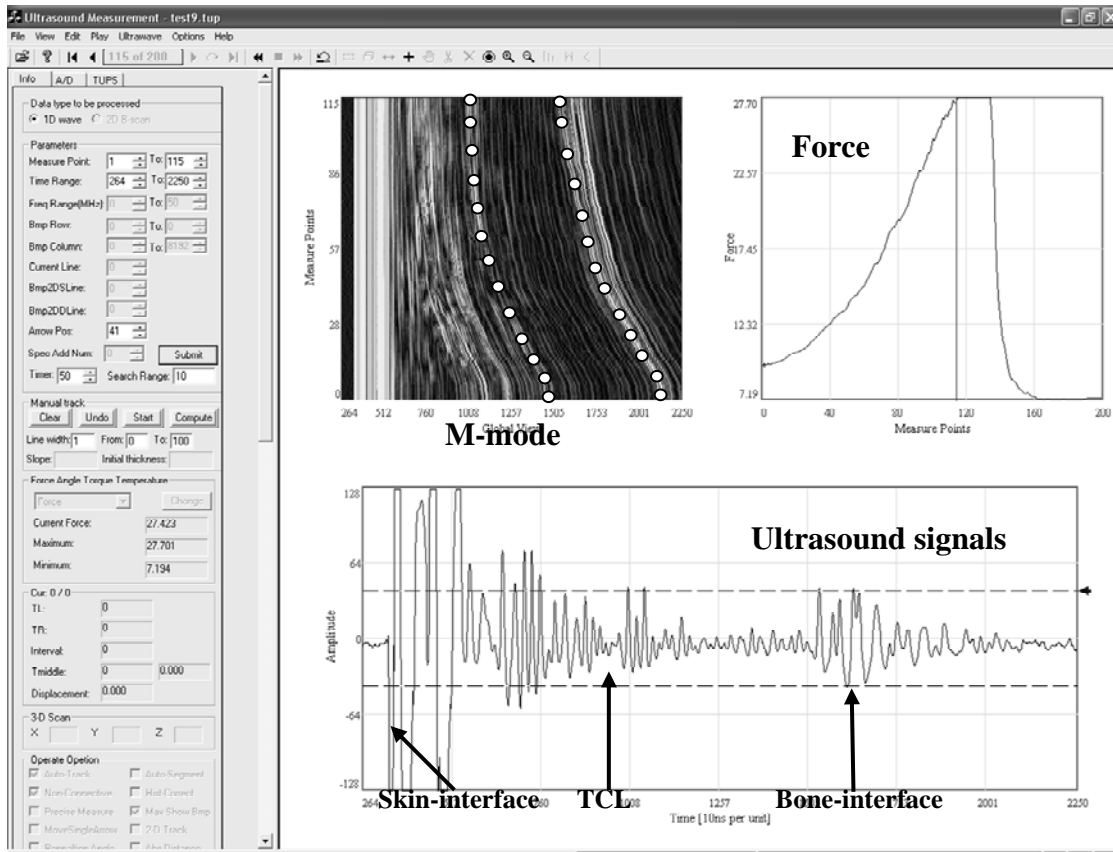
11

12

13

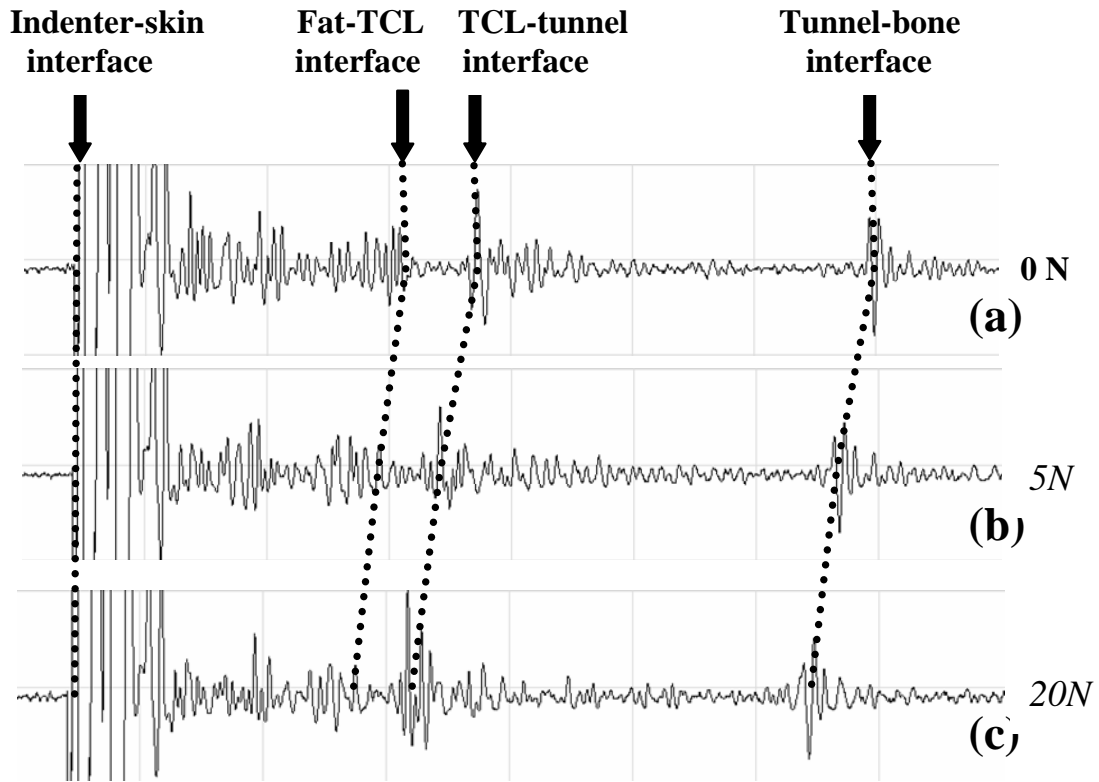
14

15



13  
14  
15  
16  
17  
18  
19  
20  
21  
22

Fig. 2



1  
2  
3

Fig. 3