



A CASE OF AMYLOID GOITRE IN HEAVY CHAIN AMYLOIDOSIS: DIAGNOSTIC CHALLENGES AND CLINICAL IMPLICATIONS

Francisco Laranjeira¹, Bernardo Neves¹, Paulo Bernardo², Francisco do Rosário³, Otília Fernandes⁴, Evelina Mendonça⁵, Ana Catarino⁵

¹ Department of Internal Medicine, Hospital da Luz, Lisbon, Portugal

² Department of Hematology, Hospital da Luz, Lisbon, Portugal

³ Department of Endocrinology, Hospital da Luz, Lisbon, Portugal

⁴ Department of Radiology, Hospital da Luz, Lisbon, Portugal

⁵ Department of Clinical Pathology, Hospital da Luz, Lisbon, Portugal

Corresponding author: Francisco Laranjeira **e-mail:** francisco.soares.laranjeira@hospitadaluz.pt

Received: 03/01/2024 Accepted: 11/01/2024 Published: 01/02/2024

Conflicts of Interests: The Authors declare that there are no competing interests.

Patient Consent: The authors declare that patient's written informed consent was obtained prior to the submission of the manuscript.

This article is licensed under a [Commons Attribution Non-Commercial 4.0 License](#)

How to cite this article: Laranjeira F, Neves B, Bernardo P, do Rosário F, Fernandes O, Mendonça E, Catarino A. A case of amyloid goitre in heavy chain amyloidosis: diagnostic challenges and clinical implications. *EJCRIM* 2024;11:doi:10.12890/2024_004286.

ABSTRACT

Immunoglobulin heavy chain amyloidosis (AH amyloidosis) is an extremely rare subtype of immunoglobulin-derived amyloidosis and there is limited literature on how to diagnose and manage this disorder. We describe a rare case of AH amyloidosis with amyloid goitre and the importance of mass spectrometry in the identification of the different types of amyloids. While additional studies are needed, several observations suggest important practical implications, including differences in clinical picture, prognosis, and pathologic diagnosis.

KEYWORDS

Heavy chain amyloidosis, amyloid goitre, Tru-Cut biopsy, mass spectrometry

LEARNING POINTS

- Immunoglobulin heavy chain amyloidosis is an extremely rare subtype of immunoglobulin-derived amyloidosis and amyloid goitre is even rarer.
- There is limited literature on how to diagnose and manage this disorder.
- This case portrays one of these cases – one of the few existing in the literature – and reinforces the diagnostic complexity of this entity.

INTRODUCTION

Immunoglobulin-related amyloidosis is the most common type of systemic amyloidosis in developed countries, primarily comprising monoclonal light chain amyloidosis.

Heavy chain amyloidosis (AH amyloidosis) is exceptionally rare and is characterised by the aggregation and deposit of amyloid fibrils composed of monoclonal immunoglobulin heavy chain fragments, usually produced by an underlying



plasma cell dyscrasia^[1]. To date, there have been only a few reported cases of AH amyloidosis, all published in the format of single case reports. Therefore, there is limited literature on how to diagnose and manage this disorder^[2].

Amyloid fibrils deposit in various organs, which results in a variety of symptoms or signs. Involvement of the thyroid gland by amyloid is a relatively common phenomenon, however clinically significant enlargement of the thyroid – amyloid goitre – is an extremely rare occurrence^[3]. Ultrasound and ultrasound-guided fine-needle aspiration cytology are the main methods for diagnosing thyroid disease^[4]. Once the histologic diagnosis is made, it is important to distinguish primary amyloidosis from other forms of amyloidosis on tissue specimens. Mass spectrometry is the preferred method, although it is not widely available, and appropriate tissue samples need to be sent to referral centres for such testing^[5].

CASE DESCRIPTION

We present a 75-year-old female patient, with a known medical history of type 2 diabetes mellitus, who attended a medical appointment due to a constitutional condition of 6 months duration characterised by asthenia, tiredness, anorexia, and weight loss (of approximately 10 kg over 3 months). She also reported experiencing transient episodes of dysphagia for liquids, macroscopic haematuria and periorbital oedema that resolved spontaneously. No other symptoms were noted in the systematic inquiry. On physical examination, the patient appeared asthenic, there was macroglossia, mild hepatomegaly and an enlarged thyroid with hard stony consistency (Fig. 1).

She had already undergone some examinations previously,

which include a transthoracic echocardiogram and cardiac magnetic resonance imaging, showing a hypertrophic cardiomyopathy with thickness of the basal segment of the anterior septum suggestive of infiltrative disease, and a thyroid ultrasound which was compatible with multinodular goitre (largest nodules with 11 mm).

Blood tests showed normocytic normochromic anaemia (Hb 8.9 g/dl), kidney injury with serum creatinine 1.49 mg/dl, cholestasis with normal total bilirubin (GGT 348 U/l, FA 174 U/l) and slight elevation of inflammatory parameters (erythrocyte sedimentation rate 32 mm/hr and C-reactive protein 0.4 mg/dl). Additionally, thyroid function was normal and NT-proBNP was markedly elevated (45,699 pg/ml). Urinary analysis revealed non-nephrotic proteinuria and haemoglobinuria.

Discussions with Endocrinology led to the decision to perform a thyroid biopsy to exclude neoplastic disease. The ultrasound-guided cytological evaluation showed low cellularity and resulted in the diagnoses of benign cyst and follicular lesion of undetermined significance. In view of these results, taking into account the presence of multisystem involvement with macroglossia, hepatomegaly, infiltrative cardiomyopathy and renal injury, systemic infiltrative disease was suspected. Tissue collection was repeated, this time with the Tru-Cut® biopsy technique. The result was an amorphous substance which, after staining with Congo red, was confirmed as an amyloid substance (Fig. 2). The main markers for neoplastic disease were negative (TTF-1, calcitonin and thyroglobulin) (Fig. 3). The presence of amyloid goitre confirmed the diagnosis of systemic amyloidosis.

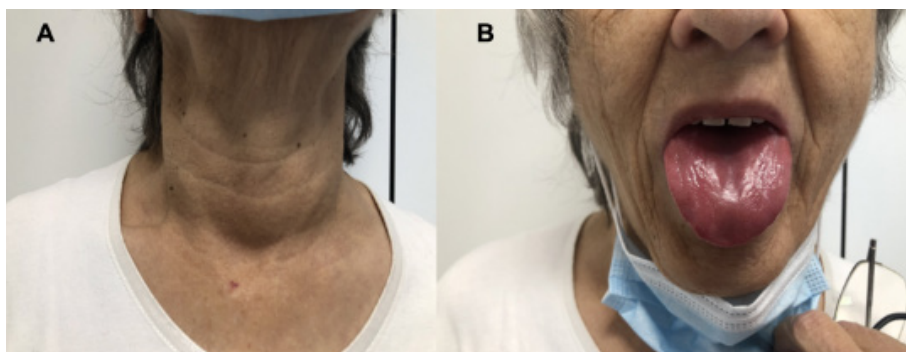


Figure 1. Findings in physical examination: (A) enlarged thyroid with hard stony consistency and (B) macroglossia.

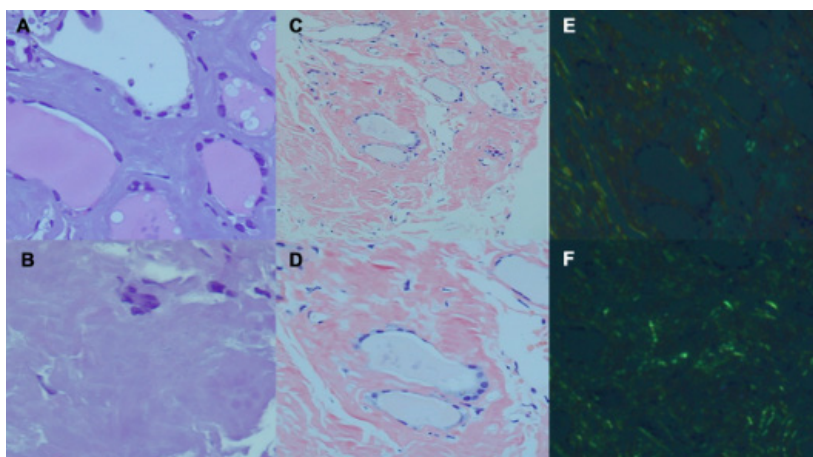


Figure 2. Thyroid biopsy: (A, B) sample of tissue that concerned thyroid parenchyma was composed of a small number of follicular structures atrophic, among which extracellular deposits of amorphous, eosinophilic and hyaline-fibrillar material can be identified. In extracellular location, (C, D) a substance is identified that, after being applied to Congo red, has a green refringence when observed under polarised light, consistent with amyloid (E, F).

In the complementary study, monoclonal gammopathies were not found either in the blood or the urine, and the myelogram showed no excess of plasma cells or lymphocytes. To identify the type of amyloid substance, mass spectrometry of the thyroid tissue was performed. Heavy H chains were identified in high abundance, and light chains in an insignificant amount, suggesting AH/AL type amyloidosis. Other proteins were tested but not identified, suggesting the absence of ATTR and AApoA/AApoC amyloidosis. The osteomedullary biopsy later confirmed plasma cell neoplasia with restriction of kappa light chains and amyloid deposits (Fig. 4).

The case was discussed in a multidisciplinary Haematology meeting, and treatment with D-VCd (daratumumab and bortezomib with cyclophosphamide and dexamethasone) was implemented. Despite the beginning of treatment, the patient evolved unfavourably and died 4 months after diagnosis.

DISCUSSION

AH amyloidosis is quite a rare disorder compared to AL amyloidosis, and due to its clinical similarity to AL amyloidosis it may often be misdiagnosed. AH amyloidosis is commonly associated with plasma cell dyscrasia. The literature regarding AH is scarce, and while additional studies are needed to shed light on heavy amyloidosis, data presented to date suggest important practical implications, including differences in clinical picture, prognosis and pathologic diagnosis^[6].

Clinically significant enlargement of the thyroid due to amyloid depositions unrelated to calcitonin is an extremely rare condition. This condition was first defined by Beckman in the mid-1800s and later by Eisenberg in 1904. These

authors conceived the term ‘amyloid goitre’, a disorder that has been associated in the majority of cases with secondary amyloidosis^[7]. Amyloid deposits can also be seen in other conditions such as medullary thyroid carcinoma, which is a very important diagnostic consideration. Calcitonin staining is helpful in establishing or excluding its presence^[8]. In patients with amyloid goitre, thyroid function tests are often normal, and patients are clinically euthyroid, as seen in our case.

In the literature, there are conflicting reports regarding the effectiveness of fine-needle aspiration cytology (FNAC) as a diagnostic method in the amyloid goitre^[9]. In the case we presented, where the stony consistency of the gland aroused high suspicion, both ultrasound images and cytological aspects did not enlighten about the diagnosis. The option for a Tru-Cut biopsy allowed the diagnosis of this rare systemic disease with manifestation even rarer in the thyroid. The reason FNAC is often non-diagnostic is probably due to the thyroid’s heterogeneous involvement with cystic changes. However, a Tru-Cut biopsy is an alternative option that can be performed in selected cases based on clinical suspicion of a systemic infiltrative disease.

Mass spectrometry, as described here for the diagnosis of heavy-chains amyloidosis, is a powerful clinical tool. The assay provides unprecedented sensitivity and specificity for the diagnosis and typing of amyloidosis, including rare hereditary and iatrogenic variants. In addition to specific diagnostic information, the assay provides information that may be important for downstream clinical decisions^[9].

Beyond the involvement of the thyroid, our patient undeniably had significant cardiac involvement. Although clinically asymptomatic, the cardiac MRI did show signs of amyloid infiltration, and the BNP levels were very high

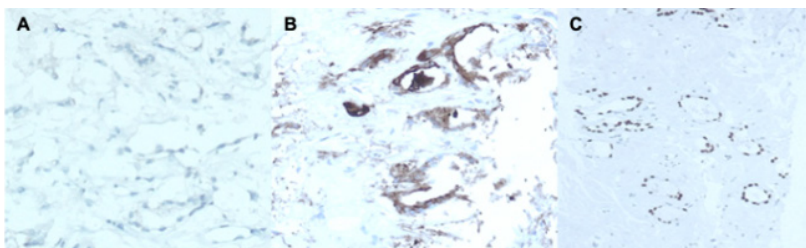


Figure 3. Thyroid biopsy: the ICQ study with (A) negative calcitonin and positive (B) thyroglobulin and (C) TTF-1.

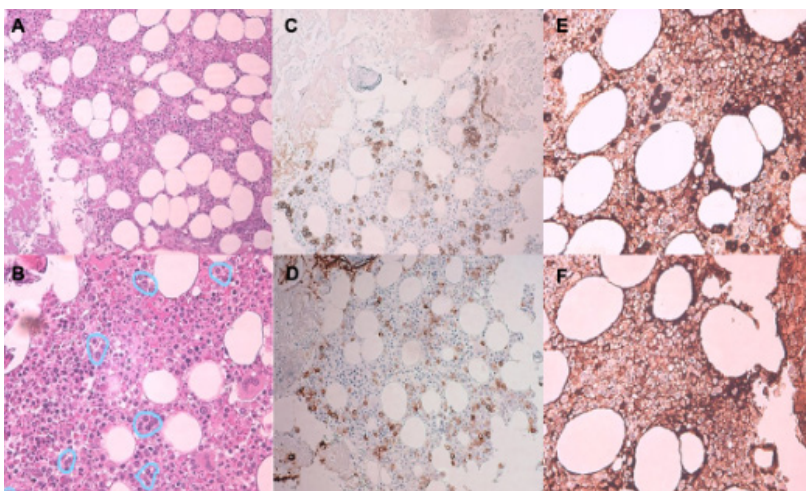


Figure 4. Osteomedullary biopsy: (A) slightly hypercellular bone marrow for age with trilinear haematopoiesis with maturation and no significant dysplasia; (B) Increased plasma cell population, (C) CD138+ (D) and CD56+, constituting around 20% of nucleated cellularity and with apparent restriction of kappa light chains (E, F).

(around 45,000 pg/ml)^[10]. According to data from the Andromeda trial, the D-VCd protocol has become the standard treatment for AL/AH amyloidosis. The addition of an anti-CD38 antibody to the D-VCd protocol was associated with improved haematologic, cardiac and renal responses, and better free survival of major organ deterioration or haematologic progression^[11]. In this trial, patients with evidence of serious cardiovascular conditions were excluded as our patient would have been; hence, as expected, the clinical benefit reported with the D-VCd protocol was not observed in this patient. Despite advances in treatment in recent years, the prognosis for AL/AH amyloidosis remains poor, particularly for patients with severe cardiac dysfunction where survival is often less than 6 months^[12]. The report of this case also reinforces the need for new treatment approaches, especially for patients with severe cardiac involvement.

CONCLUSION

This report highlights a rare instance of AH amyloidosis presenting with amyloid goitre. The intricate diagnostic of this patient, involving ultrasound-guided biopsies and mass spectrometry, underscores the diagnostic complexity of AH amyloidosis. Given the poor prognosis despite targeted treatment, there is a critical need for enhanced diagnostic tools and increased clinician awareness. Future research should focus on refining diagnostic criteria, exploring new therapeutic approaches and accumulating more case studies for a deeper understanding of AH amyloidosis's clinical manifestations and treatment responses, ultimately aiming to improve patient management and outcomes.

REFERENCES

1. Kyle RA, Gertz MA. Primary systemic amyloidosis: clinical and laboratory features in 474 cases. *Semin Hematol* 1995;**32**:45–59.
2. Nasr SH, Said SM, Valeri AM, Sethi S, Fidler ME, Cornell LD, et al. The diagnosis and characteristics of renal heavy-chain and heavy/light-chain amyloidosis and their comparison with renal light-chain amyloidosis. *Kidney Int* 2013;**83**:463–470.
3. Lari E, Burhamah W, Lari A, Alsafran S, Ismail A. Amyloid goiter – a rare case report and literature review. *Ann Med Surg (Lond)* 2020;**57**:295–298.
4. Yildiz L, Kefeli M, Kose B, Baris S. Amyloid goiter: two cases and a review of the literature. *Ann Saudi Med* 2009;**29**:138–141.
5. Sethi S, Theis JD, Leung N, Dispenzieri A, Nasr SH, Fidler ME, et al. Mass spectrometry-based proteomic diagnosis of renal immunoglobulin heavy chain amyloidosis. *Clin J Am Soc Nephrol* 2010;**5**:2180–2187.
6. Chaulagain CP, Herlitz LC, Fu J, Bilani N, Lucitt C, Comenzo RL. How we manage systemic immunoglobulin heavy chain amyloidosis (AH amyloidosis) and immunoglobulin heavy-and-light-chain amyloidosis (AL amyloidosis). *Clin Lymphoma Myeloma Leuk* 2020;**20**:e826–e831.
7. Orrego JJ, Chorny JA. Amyloid goiter as the first recognizable manifestation of immunoglobulin light chain amyloidosis. *AACE Clin Case Rep* 2019;**5**:e326–e329.
8. Coca-Pelaz A, Vivanco-Allende B, Alvarez-Marcos C, Suarez-Nieto C. Multifocal papillary thyroid carcinoma associated with primary amyloid goiter. *Auris Nasus Larynx* 2012;**39**:549–551.
9. Shimamoto Y, Takahashi N, Katoh N, Matsui Y, Mochizuki Y, Ito M, et al. Light and heavy chain deposition disease with focal amyloid deposition diagnosed with mass spectrometry: a case report. *BMC Nephrol* 2023;**24**:187.
10. Otaka Y, Nakazato Y, Tsutsui T, Tamura J. Cardiac involvement in heavy and light chain amyloidosis: a case report and literature review. *Medicine (Baltimore)* 2019;**98**:e17999.
11. Kastritis E, Palladini G, Minnema MC, Wechalekar AD, Jaccard A, Lee HC, et al. Daratumumab-based treatment for immunoglobulin light-chain amyloidosis. *N Engl J Med* 2021;**385**:46–58.
12. Wechalekar AD, Schonland SO, Kastritis E, Gillmore JD, Dimopoulos MA, Lane T, et al. A European collaborative study of treatment outcomes in 346 patients with cardiac stage III AL amyloidosis. *Blood* 2013;**121**:3420–3427.