



AALBORG UNIVERSITY
DENMARK

Aalborg Universitet

A novel mitochondrial mutation m.8989G>C associated with neuropathy, ataxia, retinitis pigmentosa - the NARP syndrome

Duno, Morten; Wibrand, Flemming; Baggesen, Kirsten; Rosenberg, Niels Thomas; Olsen, Niels Kjær; Frederiksen, Anja Lisbeth

Published in:
Gene

DOI (link to publication from Publisher):
[10.1016/j.gene.2012.12.066](https://doi.org/10.1016/j.gene.2012.12.066)

Publication date:
2013

Document Version
Publisher's PDF, also known as Version of record

[Link to publication from Aalborg University](#)

Citation for published version (APA):

Duno, M., Wibrand, F., Baggesen, K., Rosenberg, N. T., Olsen, N. K., & Frederiksen, A. L. (2013). A novel mitochondrial mutation m.8989G>C associated with neuropathy, ataxia, retinitis pigmentosa - the NARP syndrome. *Gene*, 515(2), 372-5. <https://doi.org/10.1016/j.gene.2012.12.066>

General rights

Copyright and moral rights for the publications made accessible in the public portal are retained by the authors and/or other copyright owners and it is a condition of accessing publications that users recognise and abide by the legal requirements associated with these rights.

- ? Users may download and print one copy of any publication from the public portal for the purpose of private study or research.
- ? You may not further distribute the material or use it for any profit-making activity or commercial gain
- ? You may freely distribute the URL identifying the publication in the public portal ?

Take down policy

If you believe that this document breaches copyright please contact us at vbn@aub.aau.dk providing details, and we will remove access to the work immediately and investigate your claim.



Short Communication

A novel mitochondrial mutation m.8989G>C associated with neuropathy, ataxia, retinitis pigmentosa – The NARP syndrome

Morten Duno ^{a,*}, Flemming Wibrand ^a, Kirsten Baggesen ^b, Thomas Rosenberg ^c, Niels Kjaer ^d, Anja L. Frederiksen ^e

^a Dept. of Clinical Genetics, University Hospital, Rigshospitalet, Copenhagen, Denmark

^b Dept. of Ophthalmology, Aalborg Hospital, Denmark

^c National Eye Clinic for the Visually Impaired, Kennedy Center, University Hospital, Rigshospitalet, Copenhagen, Denmark

^d Dept. of Neurology, Aalborg Hospital, Aalborg, Denmark

^e Dept. of Clinical Genetics, Vejle and Aalborg Hospital, Vejle, Denmark

ARTICLE INFO

Article history:

Accepted 3 December 2012

Available online 20 December 2012

Keywords:

NARP

Mitochondria

Ataxia

Retinitis pigmentosa

Neuropathy

m.8989G>C

ABSTRACT

The archetypal NARP syndrome is almost exclusively associated with the m.8993T>C/G mutation in the sixth subunit of the mitochondrial ATP synthase, whereas other mutations in the *MT-ATP6* gene primarily associate with Leigh syndrome or Leber's hereditary optic neuropathy (LHON). We report a novel mitochondrial point mutation, m.8989G>C, in a patient presenting with neuropathy, ataxia and retinitis pigmentosa constituting the classical NARP phenotype. This mutation alters the amino acid right next to canonical NARP mutation. We suggest that classic NARP syndrome relates to a defined dysfunction of p.MT-ATP6.

© 2012 Elsevier B.V. All rights reserved.

1. Introduction

Mitochondrial disorders (MID) encompass a heterogeneous group of multi organ diseases caused by mutations in both the nuclear and mitochondrial genomes. Mutations in the mtDNA primarily impair the oxidative phosphorylation processes of the mitochondrial respiratory chain thereby reducing the ATP production. Tissues with high energy demands i.e. cerebrum, optic nerve, retina, muscle, heart and endocrine glands are consequently often affected in MID, however virtually every tissue can be affected, and clinical phenotypes range from mild late-onset muscle weakness to perinatal death (Taylor and Turnbull, 2005).

mtDNA mutations can either be maternally inherited, both from asymptomatic or clinically affected mothers, or arise de novo in the proband. A central feature of MID is the heterogeneity of the symptoms with phenotypic overlap between defined syndromes. The same mutation may present highly variable phenotypes both within and between families. This variation is attributed to the concept of heteroplasmy,

Abbreviations: ffERG, full-field electroretinogram; LHON, Leber's hereditary optic neuropathy; MELAS, mitochondrial encephalomyopathy, lactic acidosis, and stroke-like episodes; MERRF, myoclonic epilepsy with ragged red fibers; MID, mitochondrial disorders; mtDNA, mitochondrial DNA; NARP, neuropathy, ataxia, retinitis pigmentosa; RRF, ragged red fibers.

* Corresponding author at: Dept of Clinical Genetics, University Hospital Copenhagen 4062, Blegdamsvej 9, KD-2100 Copenhagen O, Denmark. Tel.: +45 3545 4066; fax: +45 3545 4072.

E-mail address: mdunoe@rh.dk (M. Duno).

combined with the specific mtDNA haplotype background (D'Aurelio et al., 2010), where high mutation loads associate with more severe phenotypes.

One of the first mitochondrial mutations was identified by Harding and colleagues (Holt et al., 1990) who described a combination of neuropathy, ataxia and retinitis pigmentosa in a family heteroplasmic for the m.8993T>G mutation in the *MT-ATP6* gene. This syndrome was subsequently coined NARP after the primary clinical features, however patients with a high mutation load of m.8993T>G present with Leigh syndrome (Tatuch et al., 1992); a lethal subacute necrotizing encephalomyelopathy. Several mutations throughout *MT-ATP6* have been associated with Leigh syndrome, whereas only mt.8993T>G and the related mt.8993T>C, associate with the classical NARP phenotype. Two other mutations, m.8618insT and m.9185T>C have been associated with a NARP-like phenotype (Childs et al., 2007; Lopez-Gallardo et al., 2009), but the clinical spectrum appears to be quite variable.

Here we describe a patient with a canonical NARP phenotype heteroplasmic for a novel m.8989G>C mutation in *MT-ATP6*. This mutation leads to a p.A155P substitution, located right next to the traditional NARP mutation p.L156R, indicating that the archetypal NARP phenotype is linked to a defined dysfunction of p.MT-ATP6.

2. Patient

A now fifty-three year old male patient with uneventful birth and early development. At age six an ophthalmological examination

noted a congenital left unilateral iris coloboma and normal visual acuity without glasses. He attended primary and secondary school for 10 years followed by 18 month military duty without any health symptoms or complaints. He had vocational training in a men's wear shop. Later he was appointed in a warehouse security service and in airport security. Retrospectively, problems in the dark were noticed in his late twenties and subjective mild symptoms of unsteady gait and poor balance were encountered from the early forties. Additionally, a bilateral sensorineural hearing loss for low frequencies (2000–8000 Hz) has progressed during the last decade. The individual symptoms presented initially were vague with very slow progression thus a common etiology was not previously suspected.

Due to gradually blurred vision an ophthalmological examination was performed at age 45 and a diagnosis retinitis pigmentosa (RP) was made. Fundus examination showed a typical late-stage RP with severely constricted retinal vessels, diffuse retinal pigment epithelium atrophy and a few irregular pigment aggregations peripherally. Dark adaptation revealed an absent rod phase and the full-field electroretinogram (ffERG) response was extinct. In addition a mild subcapsular cataract was present. At present he has concentric visual field reduction and almost total loss of vision in the right eye, but is still able to read large print with the left eye. At age fifty-two the patient was referred for neurological assessment due to progressive unsteadiness and tendency of falls when walking. The neurological examination revealed a slight dysarthria, moderate gait ataxia, and brisk patellar reflexes. Romberg's test was negative. MRI showed moderate cerebellar atrophy but no other focal changes. Cognitive functions are normal. There was no family history of any neurological or ophthalmic disorders. Plasma lactate and creatine kinase levels were normal. Neurophysiological examination showed severe sensory neurogen affection with axonal loss in the lower extremities. In the upper extremities there was a minor degree of sensory neurogen loss. There was pronounced motor nerve affection with a reduced response from posterior tibial nerve and with no signal from the left deep peroneal nerve.

Histological examination of a biopsy from the musculus vastus lateralis showed the majority of muscle fibers with normal polygonal form and diameter with scattered pattern of single hypertrophic fibers and a minor proportion of small atrophic angular fibers with a vague sporadic CD56 positive staining. There was some minor fat infiltration and type-grouping consistent with a chronic process of de- and re-innervation. No ragged red fibers (RRF) or other morphological signs of mitochondrial myopathy were observed. Electron microscopy showed normal number and form of the mitochondria.

3. Genetic and metabolic analysis

PCR and direct analysis for the three common mtDNA mutation m.3243A>G (MELAS), m.8344A>G (MERRF) and c.8993T>G/C (NARP) showed normal sequences but revealed heteroplasmic presence of a novel mutation m.8989G>C in mtDNA isolated from blood. This mutation predicts a substitution of alanine at position 155 to proline (p.A155P) in the *MT-ATP6*. Subsequent analysis detected the mutation in DNA isolated from muscle tissue, urine sediment and buccal mucosa from the proband (Fig. 1). The mutation loads in the different tissues were estimated using the quantification algorithm of the Mutation Surveyor detection software. The 80 year old mother of the proband was examined clinically, and she presented no obvious signs of NARP or NARP-related disorder. DNA was isolated from a standard blood sample from the mother, and assessed for the c.8989G>C mutation, which was not detected (Fig. 1). The proband has a healthy elder sister who declined to be investigated genetically. There was no medical history of mitochondria related symptoms.

Measurement of complex V (F_1 -ATPase) and complex II activity in a mitochondria-enriched fraction from muscle tissue showed a

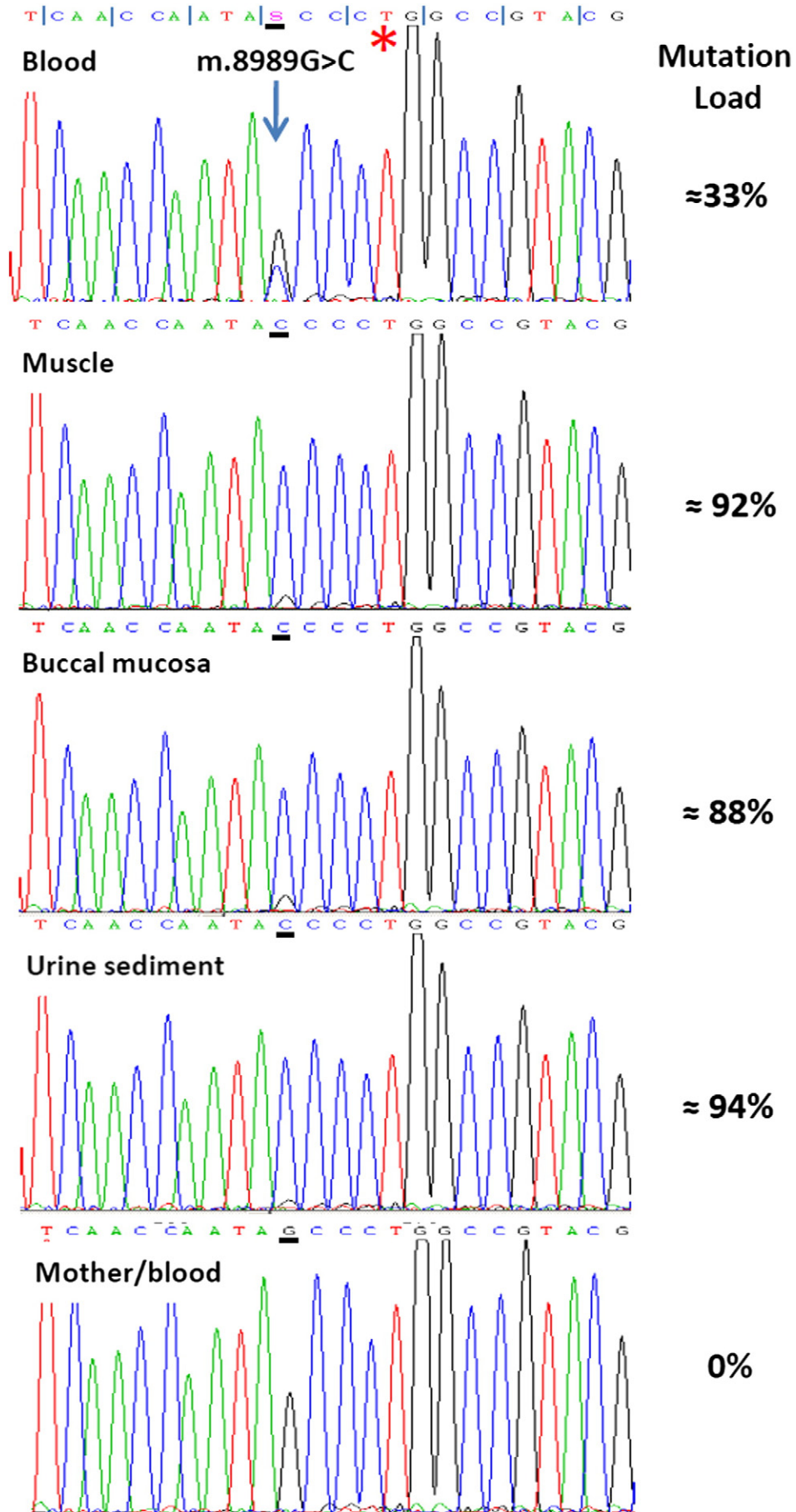
decreased complex V/II activity ratio (1.0; control range: 1.5–3.4, $n = 18$) equivalent to 38% of the control median and 67% of the lowest control value. The finding of decreased complex V activity, which is similar in magnitude to that found in 11 patients with c.8993T>G/C mutations (32–78% of the lowest control value; (Morava et al., 2006)), supports a pathogenic effect of the c.8989G>C mutation.

4. Discussion

The identification of a heteroplasmic de novo c.8989G>C mutation in a patient with classic NARP syndrome has several implications. The classic NARP phenotype has traditionally only been associated with the m.8993T>G/C mutations where m.8993T>C, leading to p.L156P, has a milder phenotypic expression than the original and more common m.8993T>G resulting in a p.L156R substitution (Rantamaki et al., 2005; Santorelli et al., 1997). m.8993T>C is tolerated at a higher heteroplasmic level than m.8993T>G, and symptomatic individuals show mutation levels of >90% (Debray et al., 2007; Thorburn and Rahman, 2011). These differences have been attributed to diversities in the haplotype background, and assembly of the ATP-synthase complex with the mitochondrial membrane (Kara et al., in press; Vazquez-Memije et al., 2009). The novel m.8989G>C mutation alters the highly conserved alanine residue to proline at position 155 (p.A155P) right next to p.L156. The clinical expression, the high level of heteroplasmy and the introduction of an abnormal proline residue all resembles the m.8993T>C mutation. Thus, the NARP phenotype might relate to a fairly specific alteration of the MT-ATP6 protein. Approx. 1% of Japanese are homoplasmic for the neutral polymorphism m.8989G>A resulting in p.A155T, underscoring the specific effect of the p.A155P substitution (www.LOVD.org). It has been suggested that the NARP phenotype can be caused by loss-of-function mutations in MT-ATP6, however, the index patient heteroplasmic for the truncating MT-ATP6 mutation m.8618insT, p.Thr33Hisfs*32 (Lopez-Gallardo et al., 2009), presented with developmental delay at age four and developed a severe phenotype by the age of 12, which are atypical features for classic NARP. The two closest located mutations, m.8950G>A and m.9035T>C only partly associates with the NARP phenotype giving rise to LHON combined with dystonia and progressive ataxia, respectively (Abu-Amero and Bosley, 2005; Sikorska et al., 2009), further emphasizing the specificity of NARP mutations.

The heteroplasmic level of c.8993T>G/C is believed to be fairly similar in different tissues from the same individual, although tissue variation can occur (Enns et al., 2006; White et al., 1999). Our patient shows a clinically significant mutation level in DNA isolated from muscle, buccal mucosa and urine sediment, whereas the mutation level in mDNA isolated from blood, was considerably lower. Whether this is due to an age dependent drift towards wild type in the hematopoietic lineage, or reflects a stable distribution is unknown. The high mutation level in muscle, buccal mucosa and urine sediment, suggests that m.8989G>C arose very early in the embryonic development, or was inherited. Although the mother of the proband did not harbor the mutation in DNA isolated from blood, the possibility exist that she could be heteroplasmic for m.8989G>C in other tissues, and that the mutation has cleared from her hematopoietic cell line due to age dependent drift. Such a progression has been observed for other mDNA mutations (Rahman et al., 2001).

Neuropathy, ataxia and retinitis pigmentosa are all prevalent multi etiologic conditions, which can develop independently over several years and thus escape being recognized as NARP. In the present case, symptoms were slowly progressing with nearly two decades between the initial symptoms of RP (night blindness) and the development of ataxia. The confluent clinical presentation exposes the challenges of recognizing NARP thereby potentially postponing or even missing the diagnosis. The exact proportion of patients with a NARP phenotype being heteroplasmic for a mutation of m.8993T, is not exactly



known, but has been estimated to be in the range of 10% to >50% (Santorelli et al., 1997; Sikorska et al., 2009; Thorburn and Rahman, 2011). As the m.8993T>C/G mutation was one of the first pathogenic mtDNA mutation to be discovered, a wide range of methodologies have been established to detect the specific mutation. Several of these (e.g. RFLP, ARMS, TaqMan) will not necessarily detect a potential c.8989G>T mutation. Thus, c.8989G>C might very well account for more cases than the single patient described here. We therefore suggest that patient referred for NARP should be assessed for c.8989G>C.

Acknowledgments

We thank the patient for his kind cooperation. Used equipment was partly obtained through a research grant from the Toyota Fond, Denmark.

References

- Abu-Amero, K.K., Bosley, T.M., 2005. Detection of mitochondrial respiratory dysfunction in circulating lymphocytes using resazurin. *Arch. Pathol. Lab. Med.* 129, 1295–1298.
- Childs, A.M., et al., 2007. Variable phenotype including Leigh syndrome with a 9185T>C mutation in the MTATP6 gene. *Neuropediatrics* 38, 313–316.
- D'Aurelio, M., Vives-Bauza, C., Davidson, M.M., Manfredi, G., 2010. Mitochondrial DNA background modifies the bioenergetics of NARP/MILS ATP6 mutant cells. *Hum. Mol. Genet.* 19, 374–386.
- Debray, F.G., Lambert, M., Lortie, A., Vanasse, M., Mitchell, G.A., 2007. Long-term outcome of Leigh syndrome caused by the NARP-T8993C mtDNA mutation. *Am. J. Med. Genet. A* 143A, 2046–2051.
- Enns, G.M., Bai, R.K., Beck, A.E., Wong, L.J., 2006. Molecular–clinical correlations in a family with variable tissue mitochondrial DNA T8993G mutant load. *Mol. Genet. Metab.* 88, 364–371.
- Holt, I.J., Harding, A.E., Petty, R.K., Morgan-Hughes, J.A., 1990. A new mitochondrial disease associated with mitochondrial DNA heteroplasmy. *Am. J. Hum. Genet.* 46, 428–433.
- Kara, B., Arikian, M., Maras, H., Abaci, N., Cakiris, A., Ustek, D., in press. Whole mitochondrial genome analysis of a family with NARP/MILS caused by m.8993T>C mutation in the MT-ATP6 gene. *Mol. Genet. Metab.* <http://dx.doi.org/10.1016/j.ymgme.2012.06.013>.
- Lopez-Gallardo, E., et al., 2009. NARP syndrome in a patient harbouring an insertion in the MT-ATP6 gene that results in a truncated protein. *J. Med. Genet.* 46, 64–67.
- Morava, E., et al., 2006. Clinical and biochemical characteristics in patients with a high mutant load of the mitochondrial T8993G/C mutations 21. *Am. J. Med. Genet. A* 140, 863–868.
- Rahman, S., Poulton, J., Marchington, D., Suomalainen, A., 2001. Decrease of 3243 A->G mtDNA mutation from blood in MELAS syndrome: a longitudinal study. *Am. J. Hum. Genet.* 68, 238–240.
- Rantamaki, M.T., Soini, H.K., Finnila, S.M., Majamaa, K., Udd, B., 2005. Adult-onset ataxia and polyneuropathy caused by mitochondrial 8993T->C mutation. *Ann. Neurol.* 58, 337–340.
- Santorelli, F.M., Tanji, K., Shanske, S., DiMauro, S., 1997. Heterogeneous clinical presentation of the mtDNA NARP/T8993G mutation. *Neurology* 49, 270–273.
- Sikorska, M., et al., 2009. Identification of ataxia-associated mtDNA mutations (m.4052T>C and m.9035T>C) and evaluation of their pathogenicity in transmitochondrial cybrids. *Muscle Nerve* 40, 381–394.
- Tatuch, Y., et al., 1992. Heteroplasmic mtDNA mutation (T-G) at 8993 can cause Leigh disease when the percentage of abnormal mtDNA is high. *Am. J. Hum. Genet.* 50, 852–858.
- Taylor, R.W., Turnbull, D.M., 2005. Mitochondrial DNA mutations in human disease. *Nat. Rev. Genet.* 6, 389–402.
- Thorburn, D.R., Rahman, S., 1981. Mitochondrial DNA-associated Leigh syndrome and NARP. In: Pagon, R.A., Bird, T.D., Dolan, C.R., et al. (Eds.), *GeneReviews™* [Internet]. Seattle (WA): University of Washington, Seattle; 1993-. Available from: <http://www.ncbi.nlm.nih.gov/books/NBK1173/>.
- Vazquez-Memije, M.E., Rizza, T., Meschini, M.C., Nesti, C., Santorelli, F.M., Carrozzo, R., 2009. Cellular and functional analysis of four mutations located in the mitochondrial ATPase6 gene. *J. Cell. Biochem.* 106, 878–886.
- White, S.L., et al., 1999. Mitochondrial DNA mutations at nucleotide 8993 show a lack of tissue- or age-related variation. *J. Inherit. Metab. Dis.* 22, 899–914.

Fig. 1. Sequence traces of the novel c.8989G>C in DNA isolated for various tissues of the proband (panel 1–4) and his healthy mother (lower panel 5). The asterisk * denotes the site of the classic NARP mutation c.8993T>G/C. The reading frame is indicated in first panel. There was no indication of a C nucleotide at c.8989 in sequence from the mother, even upon enlargement of the electropherogram.