

Southern Illinois University Carbondale
OpenSIUC

Publications

Fisheries and Illinois Aquaculture Center

2-2004

Use of Ultrasound Imaging to Determine Sex of Shovelnose Sturgeon

Robert E. Colombo

Southern Illinois University Carbondale

Paul S. Wills

Southern Illinois University Carbondale

James E. Garvey

Southern Illinois University Carbondale

Follow this and additional works at: http://opensiuc.lib.siu.edu/fiaq_pubs

© by the American Fisheries Society 2004

Published in *North American Journal of Fisheries Management*, Vol. 24, Issue 1 (February 2004) at doi:

[10.1577/M03-016](https://doi.org/10.1577/M03-016)

Recommended Citation

Colombo, Robert E., Wills, Paul S. and Garvey, James E. "Use of Ultrasound Imaging to Determine Sex of Shovelnose Sturgeon." (Feb 2004).

This Article is brought to you for free and open access by the Fisheries and Illinois Aquaculture Center at OpenSIUC. It has been accepted for inclusion in Publications by an authorized administrator of OpenSIUC. For more information, please contact opensiuc@lib.siu.edu.

Use of Ultrasound Imaging to Determine Sex of Shovelnose Sturgeon

ROBERT E. COLOMBO,* PAUL S. WILLS, AND JAMES E. GARVEY

Fisheries and Illinois Aquaculture Center, Department of Zoology,
Southern Illinois University, Carbondale, Illinois 62901-6511, USA

Abstract.—During November 2002, 51 shovelnose sturgeon *Scaphirhynchus platyrhynchus* were sexed by ultrasound imaging using a portable ultrasonograph. We identified males with 96% accuracy ($N = 25$) and females with 80% accuracy ($N = 25$); one hermaphroditic individual was misidentified as a male. Overall, ultrasound imaging was 86% accurate. Sex in postspawned females was difficult to determine, 60% being misidentified as males ($N = 5$). Ultrasonography is an effective noninvasive method for sex determination that can be applied to other species of Acipenseriformes. Modern portable equipment expands its utility to field studies.

The shovelnose sturgeon *Scaphirhynchus platyrhynchus* is commercially exploited in 7 of 24 states where it occurs in the Mississippi River basin (Keenlyne 1997). Throughout much of its range, its status is unknown or has declined (Keenlyne 1997). Various species of sturgeon have been harvested in the USA since the 1800s primarily to harvest roe for caviar production (Boreman 1997). The reduction of historical sturgeon fisheries in the Caspian Sea and Volga River (Khodorevskaya et al. 1997) and the restrictions on importation of caviar into the USA (Gnam 1998) will undoubtedly lead to increased exploitation and possibly poaching of domestic sturgeons (Secor et al. 2002).

Conservation of shovelnose sturgeon populations under increased exploitation will require increased information about life history and population status from the current condition. Management of sturgeon stocks will be particularly difficult because females are likely to be harvested preferentially for their roe. Given this, females within an exploited population should be considered the effective management unit (i.e., stock). In general, information on the sex ratio of a species in which females are preferentially harvested is essential to effective fisheries management (Fabrizio and Richards 1996). Therefore, effective methods for determining sex in the field would

greatly improve a fisheries manager's ability to collect vital population data.

Shovelnose sturgeon, as with other acipenserids, have no apparent external sexually dimorphic traits, thereby making field identification of sex difficult (Conte et al. 1988). Two methods for determining the sex in sturgeon do exist. In the first, a small incision is made in the ventral body wall of the fish and sex is determined by directly inspecting the gonads (Conte et al. 1988). This method is highly invasive and difficult under field conditions. The second method uses blood plasma indicators and has only been verified for the white sturgeon *Acipenser transmontanus* (Webb et al. 2002). Although this method is accurate, it is expensive and species-specific, requiring baseline data for each species examined. Another potential tool is ultrasound, which been used effectively for sex determination in other fishes: Pacific herring *Clupea pallasii* (Bonar et al. 1989), striped bass *Morone saxatilis* (Blythe et al. 1994), and benthic marine fishes (Martin-Robichaud and Rommens 2001). Although, portable ultrasonographic equipment is initially expensive (US\$7,000 to \$12,000) the equipment can be used on numerous species and provides immediate, noninvasive results.

Ultrasound imaging has been shown to be effective for determining the sex of the stellate sturgeon *A. stellatus* (Moghim et al. 2002). This study focused exclusively on shovelnose sturgeon sampled during a spawning migration; therefore, all stages of gonadal development were not available. Ultrasonography was 97.2% accurate in sexing stellate sturgeon, suggesting that this technique should be robust for shovelnose sturgeon.

We sought to determine whether ultrasonography can be used to determine sex of shovelnose sturgeon. If effective, ultrasound imaging would provide a quick method for determining the sex of shovelnose sturgeon and potentially other species of Acipenseriformes in the field.

Methods

Fifty-one shovelnose sturgeon ranging in size from 444 to 714 mm fork length (mean 618.4 mm;

* Corresponding author: rcolombo@siu.edu

Received January 24, 2003; accepted May 29, 2003

TABLE 1.—Percent agreement of ultrasound sex determination by stage of gonadal development for the shovelnose sturgeon. Stages are based on Bruch et al. (2001).

Sex	Stage	Description	Number correctly identified with ultrasound (<i>N</i>)	Total number (<i>N</i>)	Percent agreement
Female	F _v	Virgin female; small ovarian folds	3	4	75
	F ₁	Ovarian folds	9	10	90
	F ₂	Small white oocytes	2	2	100
	F ₃	Yellow eggs	1	1	100
	F ₄	Black eggs	3	3	100
	F ₅	Spawning female	0	0	
	F ₆	Postspawn; translucent ovary	2	5	40
	Total		20	25	80
Male	M _v	Virgin male; ribbon-like testis in fat	1	1	100
	M ₁	Tubular testis in testicular fat	16	17	94
	M ₂	Large testis with small amount of fat	7	7	100
	Total		24	25	96
Overall total			44	51 ^a	86

^a Includes one hermaphroditic individual misidentified as a male.

SD = 56.0) were collected by gill nets (90 m long, 5-cm bar mesh) set overnight between river miles 117 and 142 of the Mississippi River during November 4 through 7, 2002. Before examination, fish were euthanized with quinaldine sulfate. Gonads were imaged using a Sonosite 180Plus portable ultrasonograph with a 38-mm, 5-MHz linear transducer (L38 probe). Its durability and portability made this unit suitable for field use. The transducer was placed on the left side of the fish above the third and fourth ventral scutes anterior to the pelvic fins to produce an image in partial transverse section. This location provided reliable images with easily identifiable landmark organs (e.g., the posterior end of the swim bladder). Ultrasound transmission jelly was used between the probe surface and the fish's skin to improve imaging. A consensus sex determination was obtained by four observers for each fish. Accuracy of ultrasound derived sex determinations were verified by visual examination of gonads. Eviscerated fish were assigned a stage of gonad development using the criteria developed by Bruch et al. (2001) for lake sturgeon *A. fulvescens*. A digital picture and an ultrasound image of the gonads were captured for each fish. We used a Student's *t*-test ($\alpha = 0.05$) to compare differences in length between sexes.

Results and Discussion

This portable ultrasound equipment produced easily captured high resolution images that enabled easy recognition of internal landmark organs and gonads. These images could be readily identified by any reader who had some prior knowledge

of sturgeon gonad anatomy. Female shovelnose sturgeon were identified by having discernable ovarian folds (Figure 1a, b) or by the presence of readily discernable oocytes (Figure 1c, d). The testes of shovelnose sturgeon imaged as a smooth gray region that varied in lightness, depending on relative maturity, more mature gonad images being lighter (Figure 1e, f).

Overall, the accuracy of sex determination using ultrasound was 86% ($N = 51$) correctly identified, or 96% for males ($N = 25$) and 80% for females ($N = 25$; Table 1). Mean fork lengths of males (mean = 608.9 mm; SD = 51.5) and females (mean = 624.1 mm; SD = 59.4) did not differ (Student's *t*-test; $P = 0.149$). We were able to identify immature and mature shovelnose sturgeon gonads of both female (stages F_v to F₄) and male (stages M_v to M₂) individuals (Table 1). One individual identified as a male was grossly determined to be a hermaphrodite (710 mm; 1,420 g). The presence of a hermaphrodite is not particularly surprising because the frequency of hermaphroditic shovelnose sturgeon in the middle Mississippi River was previously reported to be 3% (Carlson et al. 1985).

Although ultrasound was effective in determining the sex of both immature (F_v to F₃) and mature (F₄) female shovelnose sturgeon, those that were postspawned (i.e., having recrudescing ovaries) were difficult to discern from males (Figure 1g, h). Three of the five postspawned females (F₆) examined were misidentified as males, primarily because of the overall lack of defined tissue structure (Table 1). This effect was also noted in Atlantic cod *Gadus morhua* (Karlsen and Holm 1994) and

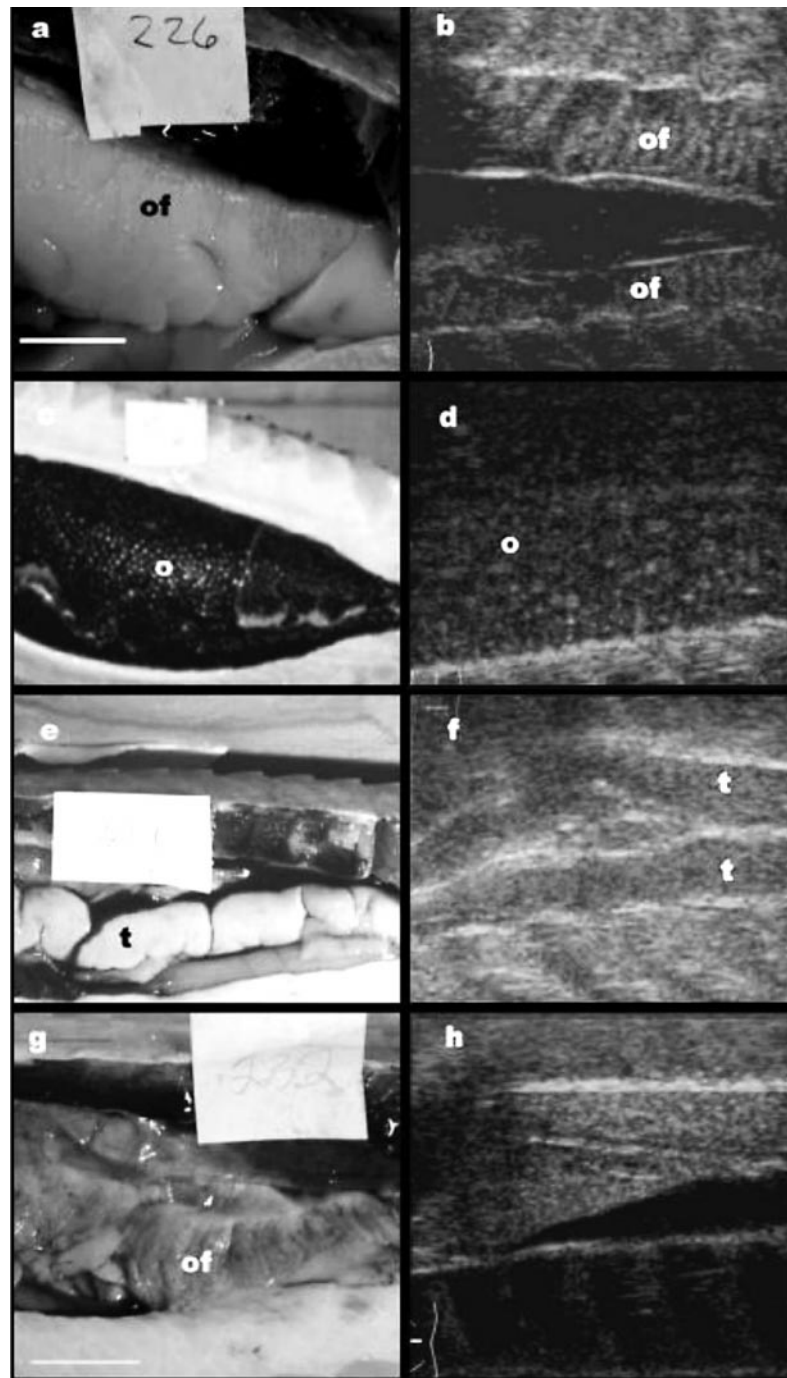


FIGURE 1.—Ultrasound (UL) and eviscerated (EV) images of shovelnose sturgeon gonads: (a) EV, undeveloped female; (b) UL, undeveloped ovary (note ovarian folds); (c) EV, mature ovary (note black eggs); (d) UL, mature ovary (note oocytes; about 2 mm); (e) EV, mature testis; (f) UL, mature testis; (g) EV, postspawned ovary; and (h) UL, postspawned ovary (where, of = ovarian fold, t = testis, o = oocyte).

in striped bass (Blythe et al. 1994). Shovelnose sturgeon are believed to spawn in the late spring (Keenlyne 1997), accounting for the large number of postspawned females in our fall sample. Because postspawned females were the most difficult to identify, the accuracy of ultrasound for sexing shovelnose sturgeon would increase at times of the year when this stage of fish is less likely to be present (i.e., spring).

Ultrasound imaging of shovelnose sturgeon gonads is a viable technique for sex determination. With further study, the technique could be refined such that morphological differences between stages of gonadal development, similar to those used for lake sturgeon (Bruch et al. 2001), could be detected and then used to evaluate temporal patterns of gonadal development at the population level. Our results were similar to those presented by Moghim et al. (2002) for stellate sturgeon. Because of the similarity of gonadal structure in various species of Acipenseriformes (Dadswell 1979; Conte et al. 1988; Dettlaff et al. 1993; Van Eenennaam and Doroshov 1998; Bruch et al. 2001), this noninvasive technique could be directly applied to endangered sturgeons such as the pallid sturgeon *S. albus*.

Acknowledgments

We thank Martin Greenwell and William Hanna of the Shedd Aquarium, Chicago, Illinois, for their expertise in evaluating ultrasound images and the use of their ultrasound equipment. Ed Heist, Brian Koch, Neal Jackson, Eve Poynter, Aaron Schrey, Timothy Spier, and Christopher Williamson provided help with data and specimen collection.

References

- Bonar, S. A., G. L. Thomas, G. B. Pauly, and R. W. Martin. 1989. Use of ultrasonic images for rapid nonlethal determination of sex and maturity of pacific herring. *North American Journal of Fisheries Management* 9:364–366.
- Blythe, B., L. A. Helfrich, W. E. Beal, B. Bosworth, and G. S. Libey. 1994. Determination of maturational status of striped bass (*Morone saxatilis*) using ultrasonic imaging. *Aquaculture* 125:175–184.
- Boreman, J. 1997. Sensitivity of North American sturgeons and paddlefish to fishing mortality. Pages 399–405 in V. J. Birstein, J. R. Waldman, and W. E. Bemis, editors. *Sturgeon biodiversity and conservation*. Kluwer, Dordrecht, the Netherlands.
- Bruch, R. M., T. A. Dick, and A. Choudhury. 2001. A field guide to the identification of stages of gonad development in lake sturgeon (*Acipenser fulvescens*: Rafinesque): with notes on lake sturgeon reproductive biology and management implications. *Sturgeon for Tomorrow*, Fond Du Lac, Wisconsin.
- Carlson, D. M., W. L. Pflieger, L. Trial, and P. S. Haverland. 1985. Distribution, biology and hybridization of *Scaphirynchus albus* and *Scaphirynchus platyrhynchus* in the Missouri and Mississippi rivers. *Environmental Biology of Fishes* 14:51–59.
- Conte, F. S., S. I. Doroshov, P. B. Lutes, and E. M. Strange. 1988. Hatchery manual for the white sturgeon (*Acipenser transmontanus*). University of California Press, Publication 322, Oakland.
- Dadswell, M. J. 1979. Biology and population characteristics of the shortnose sturgeon *Acipenser brevirostrum* LeSuer, 1818 (Osteichthyes: Acipenseridae), in the Saint John River estuary, New Brunswick. *Canadian Journal of Zoology* 57:2186–2210.
- Dettlaff, T. A., A. S. Ginsburg, and O. I. Schmalhausen. 1993. *Sturgeon fishes: developmental biology and aquaculture*. Springer-Verlag, New York.
- Fabrizio, M. C., and R. A. Richards. 1996. Commercial fisheries surveys. Pages 625–646 in B. R. Murphy and D. W. Willis, editors. *Fisheries techniques*, 2nd edition. American Fisheries Society, Bethesda, Maryland.
- Gnam, R. 1998. Implementation of 1997 CITES listing made effective April 1, 1998. Pages 192–214 in D. F. Williamson, G. W. Benz, and C. M. Hoover, editors. *Proceedings of the symposium on the harvest, trade and conservation of North American paddlefish and sturgeon*. TRAFFIC North America/World Wildlife Fund, Washington, DC.
- Karlsen, O., and J. C. Holm. 1994. Ultrasonography, a non-invasive method for sex determination in cod (*Gadus morhua*). *Journal of Fish Biology* 44:965–971.
- Keenlyne, K. D. 1997. Life history and status of the shovelnose sturgeon *Scaphirynchus platyrhynchus*. Pages 291–298 in V. J. Birstein, J. R. Waldman, and W. E. Bemis, editors. *Sturgeon biodiversity and conservation*. Kluwer, Dordrecht, the Netherlands.
- Khodorevskaya, R. P., G. F. Dovgopol, O. L. Zhuravleva, and A. D. Vlasenko. 1997. Present status of commercial stocks of sturgeon in the Caspian Sea basin. Pages 209–219 in V. J. Birstein, J. R. Waldman, and W. E. Bemis, editors. *Sturgeon biodiversity and conservation*. Kluwer, Dordrecht, the Netherlands.
- Martin-Robichaud, D. J., and M. Rommens. 2001. Assessment of sex and evaluation of ovarian maturation of fish using ultrasonography. *Aquaculture Research* 32:113–120.
- Moghim, M., A. R. Vajhi, A. Veshkini, and M. Masoudifard. 2002. Determination of sex and maturity in *Acipenser stellatus* by using ultrasonography. *Journal of Applied Ichthyology* 18:325–328.
- Secor, D. H., P. J. Anders, W. Van Winkle, and D. A. Dixon. 2002. Can we study sturgeons to extinction? What we do and don't know about the conservation of North American Sturgeons. Pages 3–10 in W. Van Winkle, P. J. Anders, D. H. Secor, and D. A. Dixon, editors. *Biology, management, and protection of North American sturgeon*. American Fisheries Society, Symposium 28, Bethesda, Maryland.
- Van Eenennaam, J. P., and S. I. Doroshov. 1998. Effects of age and body size on gonadal development in

Atlantic sturgeon. *Journal of Fish Biology* 53:624–637.
Webb, M. A. H., G. W. Feist, E. P. Foster, C. B. Schreck, and M. S. Fitzpatrick. 2002. Potential classification

of sex and stage of gonadal maturity of wild white sturgeon using blood plasma indicators. *Transactions of the American Fisheries Society* 131:132–142.

North American Journal of Fisheries Management 24:326, 2004
© Copyright by the American Fisheries Society 2004

ERRATA

Please note the following correction in a recent issue of this journal.

Volume 21(4), November 2001: “Effective Population Size and Genetic Conservation Criteria for Bull Trout,” by B. E. Rieman and F. W. Allendorf, pages 756–764.

Page 760. Equation 2 was printed incorrectly. The correct equation appears below.

$$N_e = \frac{1}{2(1 - e^{[\log_e H]/t})}$$