

# Tirotoksična struma jajčnika po ablaciji ščitnice: prikaz primera laparoskopskega zdravljenja

## Thyrotoxic struma ovarii after thyroid ablation: a case report of laparoscopic management

### Avtor / Author

### Ustanova / Institute

Iztok Takač<sup>1</sup>, Darja Arko<sup>1</sup>, Ludvik Puklavec<sup>2</sup>, Rajko Kavalar<sup>3</sup> and Anton Crnjac<sup>4</sup>

<sup>1</sup>Oddelek za ginekološko onkologijo in onkologijo dojk, Klinika za ginekologijo in perinatologijo, Univerzitetni klinični center Maribor, Slovenija, <sup>2</sup>Oddelek za nuklearno medicino, Univerzitetni klinični center Maribor, Slovenija, <sup>3</sup>Oddelek za patologijo, Univerzitetni klinični center Maribor, Slovenija, <sup>4</sup>Oddelek za torakalno kirurgijo, Univerzitetni klinični center Maribor, Slovenija

<sup>1</sup>Department of Gynecologic and Breast Oncology, University Department of Gynecology and Perinatology, University Clinical Centre Maribor, Slovenia, <sup>2</sup>Department of Nuclear Medicine, University Clinical Centre Maribor, Slovenia, <sup>3</sup>Department of Pathology, University Clinical Centre Maribor, Slovenia, <sup>4</sup>Department of Thoracic Surgery, University Clinical Centre Maribor, Slovenia

### Ključne besede:

Struma jajčnika, hipertiroidizem, laparoskopska operacija.

### Key words:

Struma ovarii; hyperthyroidism; laparoscopic surgery

### Članek prispel / Received

11.03.2009

### Članek sprejet / Accepted

20.04.2009

### Naslov za dopisovanje /

### Correspondence

Prof. dr. Izток Takač

Oddelek za ginekološko onkologijo in onkologijo dojk, Klinika za ginekologijo in perinatologijo, Univerzitetni klinični center Maribor, Ljubljanska 5, 2000 Maribor, Slovenija  
Telefon: +386 2 32 12 445  
Fax: + 386 2 32 12 085  
E-pošta: iztok.takac@ukc-mb.si

### Izvleček

Struma jajčnika je redka oblika tumorja zarodnih celic, ki predstavlja redek vzrok ektopičnega izločanja ščitničnih hormonov. Poročamo o primeru laparoskopskega zdravljenja strume jajčnika. Pri 49-letni bolnici, ki je bila zaradi Gravesove bolezni predhodno zdravljena z ablativno operacijo in radioaktivnim jodom, se je nepričakovano pojavil hipertiroidizem. Scintigrafija telesa z <sup>131</sup>I je pokazala povečano aktivnost v medenici in s tem nakazovala na strumo jajčnika. Bolnico smo zdravili z laparoskopsko obojestransko adneksotomijo. V pooperativnem poteku ni bilo posebnosti. Histopatološka preiskava je pokazala prisotnost benigne strume jajčnika. Trenutno je bolnica brez znakov bolezni in prejema ščitnično nadomestno zdravljenje z levotiroksinom. V obravnavi

### Abstract

Struma ovarii is a rare type of germ cell tumor and a rare cause of ectopic thyroidal hormonal production. We report a case of laparoscopic management of a thyrotoxic struma ovarii. In a 49-year-old patient, previously treated by ablative surgery and radioactive iodine for Graves' disease, a new onset of hyperthyroidism occurred unexpectedly. A whole-body scan with <sup>131</sup>I detected increased pelvic uptake, suggesting struma ovarii. The patient was subsequently treated with laparoscopic bilateral salpingo-oophorectomy. The postoperative course was uneventful. Histopathologic examination revealed the presence of a benign struma ovarii. Three years after treatment the patient is disease free and is receiving thyroid replacement therapy with levothyroxine.

*nem primeru smo še pred operacijo ugotovili diagnozo tirotoksične strume jajčnika, laparoskopska operacija pa se je izkazala za koristno in zanesljivo metodo za odstranitev jajčnika.*

*In this case the thyrotoxic struma ovarii was diagnosed preoperatively and laparoscopic surgery proved to be a useful and reliable method for ovarian ablation.*

## INTRODUCTION

Struma ovarii accounts for only 2–4% of all mature ovarian teratomas, and malignant transformation has been reported in fewer than 5% of all cases (1). Most cases of struma ovarii are subclinical and the typical patient presents with pelvic pain (2). Only 5–15% of struma ovarii are complicated by hyperthyroidism (3). The mechanisms underlying the hyperthyroidism caused by struma ovarii are still largely unknown (4).

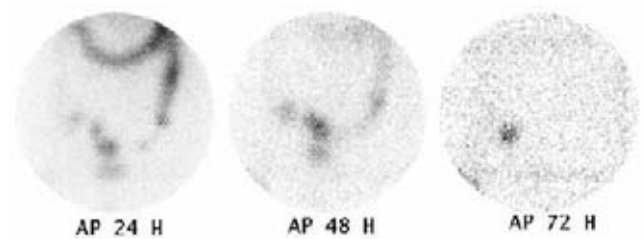
We report on a rare case of struma ovarii causing atypical hyperthyroidism, which was treated by laparoscopic surgery.

## Case Report

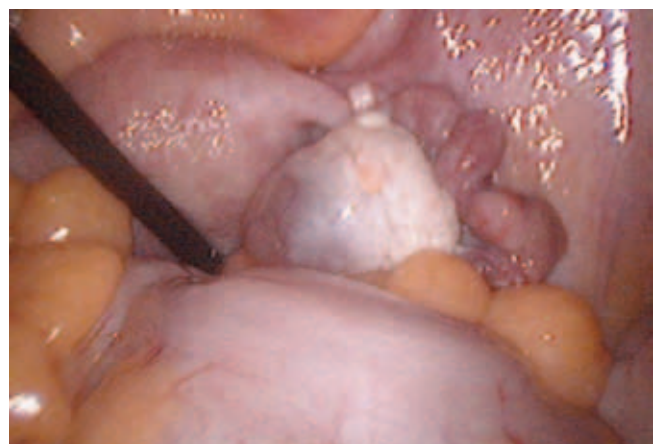S.K., a 49-year-old Caucasian woman, had undergone partial ablative surgery for Graves' disease in 1983 and again in 1991. Histopathologic examination of the specimen of the first procedure demonstrated the presence of thyroid nodal colloidal struma and that of the second procedure the presence of Graves' disease (primary hyperplasia). Despite both procedures, hyperthyroidism was still present and she was treated with thyroid suppressive therapy. She was also receiving antihypertensive therapy and her blood pressure was normal. In 1995 she underwent treatment with 370 MBq (megabecquerels) <sup>131</sup>I. Afterwards she was hypothyretic and received thyroid replacement therapy with levothyroxine. In 2006 symptoms of hyperthyroidism and elevation of thyroid hormones were recorded and ectopic production of hormones was postulated.

She had one child and had regular menstrual periods. She was 160 cm tall and weighed 75 kg.

A whole body scan with <sup>131</sup>I was performed to detect ectopic thyroid gland activity. Intense tracer uptake was detected in the right side of the pelvis (Figure 1). Preoperatively she was evaluated with transvagi-



**Figure 1.** Radioiodine <sup>131</sup>I whole body scan performed preoperatively (24, 48 and 72 h after injection).



**Figure 2.** Laparoscopic view of the right ovary with a small cyst.

nal ultrasound, which revealed a small cystic mass measuring 9 x 12 mm in the right ovary. This cystic mass did not change during menstrual cycles. No hypervascularization was found by color Doppler ultrasound. The patient had completed her childbearing and decided to proceed with bilateral adnexectomy, for which she gave informed consent.

At laparoscopy, a small cystic mass, measuring 2 cm in diameter, was seen in the right ovary (Figure 2). The left ovary appeared macroscopically normal. The remaining abdominal cavity appeared free of

disease. Peritoneal washing was obtained for cytological examination. Laparoscopic surgery was performed using bipolar coagulation and sharp dissection. The right ovary and the fallopian tube were extracted using an Endobag system (Endo Catch II, United States Surgical, Norwalk, Connecticut, USA), so no spilling of tissue occurred. After the right adnexa was removed, left salpingo-oophorectomy was performed in the same manner. The duration of the surgery was 50 minutes and the blood loss was 20 mL. The postoperative course was uneventful and she was discharged on postoperative day four.

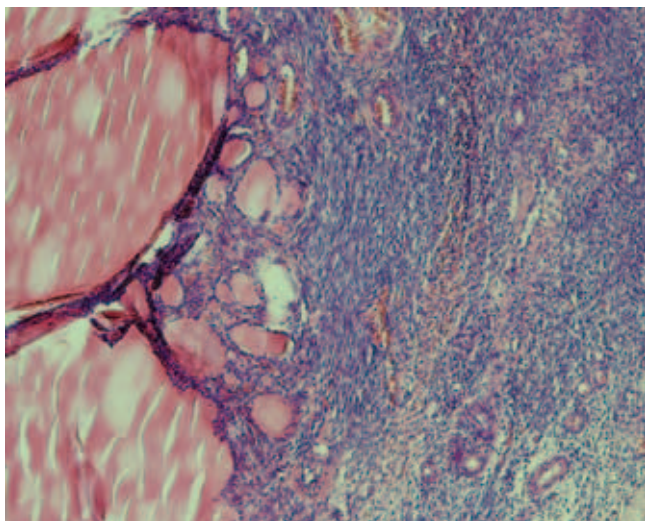


Figure 3. Thyroid tissue of struma ovarii (HE, 100x).

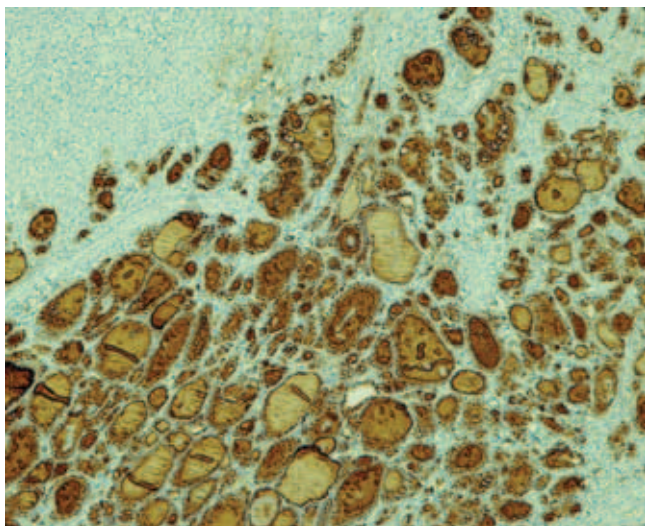


Figure 4. Strong positive thyroglobulin immunohistochemical reaction (thyroglobulin, 100x).

Histopathologic examination of the right ovary in serial sections revealed the presence of two theca lutein cysts, multiple white bodies, and a mature teratoma with elements of thyroid tissue (Figure 3). Immunohistochemistry staining for thyroglobulin was positive (Figure 4). The left ovary was normal and cytologic examination of the peritoneal washing was negative for malignant disease.

One month after surgery, the laboratory findings were as follows: thyroid stimulating hormone 5.13 mIU/L (normal values 0.27–4.2 mIU/L), free thyroxine 16.71 pmol/L (normal values 12.0–22.0 pmol/L), and free triiodothyronine 3.78 pmol/L (normal values 2.8–7.1 pmol/L).

She subsequently developed hot flushes and hormone replacement therapy was introduced. Four months after laparoscopic surgical treatment, a whole body scan with <sup>131</sup>I was repeated and no activity was detected (Figure 5).




Figure 5. Radioiodine <sup>131</sup>I whole body scan performed 4 months after laparoscopic surgery.

In May 2009 the patient is free of symptoms and is receiving thyroid replacement therapy with 125 µg of levothyroxine daily.

## DISCUSSION

Benign and malignant struma ovarii represent 0.3–1% of all ovarian neoplasms and 2–4% of all ovarian teratomas (3). A malignant struma ovarii arises within mature teratomas in 0.1% of cases (5). Hyperthyroidism is present in only 5–15% of cases. Teratomas appear to originate from a single germ cell after a defective meiosis, with a low incidence of numerical or structural chromosomal aberrations (6).

The preoperative diagnosis of struma ovarii consists of thyroglobulin measurement and radionuclide scintigraphy (7, 8). Some authors suggest adding struma ovarii to the differential diagnosis of any ovarian mass and to consider baseline thyroid function tests (9). Struma ovarii can also clinically mimic ovarian carcinoma, particularly in cystic lesions and in association with ascites and elevated cancer antigen 125 levels (10–12). In our case, no hypervascularization was detected by Doppler ultrasound. In a study of 31 patients, Savelli et al. found vascularization to be anywhere from absent to abundant and concluded that the sonographic features of struma ovarii varied (13).

To prevent radical surgery, struma ovarii should be included in the differential diagnosis when a mixed, multilocular, teratoma-like tumour of the ovary shows a well-vascularized, enhancing, central solid component (14). The coexistence of struma ovarii with a Brenner tumor is also possible (15, 16).

Interestingly, in our case new onset thyrotoxicosis occurred in a thyroidectomized patient and a whole-body scan with <sup>131</sup>I that clearly depicted pelvic uptake suggestive of an ectopic source of thyroid hormone production. Transvaginal ultrasonography detected a cystic mass measuring 9 x 12 mm.

Ciccarelli et al. found that hyperfunctioning struma ovarii can have a clinical presentation similar to that of thyroid toxic adenoma, (4) which is what occurred in our patient. On the basis of their clinical and genetic study these authors concluded that an unknown mutation or other pathophysiological mechanism could be implicated in the development of hyperthyroidism caused by struma ovarii. In contrast to our case, the patient in their study was primarily treated by radioiodine and subsequently by abdominal hysterectomy, bilateral adnexectomy, and partial resection of the sigmoid.

Volpi et al. recommend bilateral salpingo-oophorectomy, which was the procedure we used (17). They also used a plastic bag for the removal of suspicious tumors. Using an Endobag system is advisable to avoid tumor spillage in rare cases of malignancy of the ovarian struma. Furthermore, metastatic and disseminated forms of struma ovarii have been described (18, 19). In a patient treated with total thyroidectomy for papillary thyroid cancer, Lim et al. demonstrated a malignant struma ovarii on post-therapy radioiodine scanning (20).

Uncommon macroscopic and histological patterns in struma ovarii can cause difficulties in diagnosis. Cystic strumas are challenging to diagnose both macroscopically and histologically (21).

In malignant forms of struma ovarii, which are very rare malignant ovarian teratomas, long-term follow-up for the detection of metastases or tumor recurrence by serial serum thyroglobulin and <sup>131</sup>I scan or positron emission tomography/computed tomography (PET/CT) may be required in selected patients (22).

To our knowledge, this is the first report of thyrotoxic struma ovarii revealed after the treatment of Graves' disease by ablative surgery and successfully treated by laparoscopic surgery.

## References

- Kabukcuoglu F, Baksu A, Yilmaz B, Aktumen A, Evren I. Malignant struma ovarii. *Pathol Oncol Res* 2002; 8: 145-7.
- DeSimone CP, Lele SM, Modesitt SC. Malignant struma ovarii: a case report and analysis of cases reported in the literature with focus on survival and I131 therapy. *Gynecol Oncol* 2003; 89: 543-8.
- Ayhan A, Yanik F, Tuncer R, Tuncer ZS, Ruacan S. Struma ovarii. *Int J Gynaecol Obstet* 1993; 42: 143-6.
- Ciccarelli A, Valdes-Socin H, Parma J, Khoo SK, Schoumans J, Colao A, Hamoir E, Beckers A. Thyrotoxic adenoma followed by atypical hyperthyroidism due to struma ovarii: clinical and genetic studies. *Eur J Endocrinol* 2004; 150: 431-7.
- Kano H, Inoue M, Nishino T, Yoshimoto Y, Arima R. Malignant struma ovarii with Graves' disease. *Gynecol Oncol* 2000; 79: 508-10.
- Vortmeyer AO, Devouassoux-Shisheboran M, Li G, Mohr V, Tavassoli F, Zhuang Z. Microdissection-based analysis of mature ovarian teratoma. *Am J Pathol* 1999; 154: 987-91.
- Matsuda K, Maheema T, Kanazawa K. Malignant struma ovarii with thyrotoxicosis. *Gynecol Oncol* 2001; 82: 575-7.
- Joja I, Asakawa T, Mitsumori A, Nakagawa T, Hiraki Y, Kudo T, Ando M, Akamatsu N. Struma ovarii: appearance on MR images. *Abdom Imaging* 1998; 23: 652-6.
- Amareen VN, Haddad FH, Al-Kaisi NS. Hypothyroidism due to Hashimoto thyroiditis post struma ovarii excision. *Saudi Med J* 2004; 25: 948-50.
- Bokhari A, Rosenfeld GS, Cracchiolo B, Heller DS. Cystic struma ovarii presenting with ascites and elevated CA-125 level. *J Reprod Med* 2003; 48: 52-6.
- Mitrou S, Manek S, Kehoe S. Cystic struma ovarii presenting as pseudo-Meigs' syndrome with elevated CA125 levels. A case report and review of the literature. *Int J Gynecol Cancer* 2008; 18: 372-5.
- Paladini D, Vassallo M, Sglavo G, Nappi C. Struma ovarii associated with hyperthyroidism, elevated CA 125 and pseudo-Meigs syndrome may mimic advanced ovarian cancer. *Ultrasound Obstet Gynecol* 2008; 32: 236-8.
- Savelli L, Testa AC, Timmerman D, Paladini D, Ljungberg O, Valentin L. Imaging of gynecological disease (4): clinical and ultrasound characteristics of struma ovarii. *Ultrasound Obstet Gynecol* 2008; 32: 210-19.
- Van de Moortele K, Vanbeckevoort D, Hendickx S. Struma ovarii: US and CT findings. *JBR-BTR* 2003; 86: 209-10.
- Takeuchi K, Ohbayashi C, Kitazawa S, Ohara N, Maruo T. Coexistence of Brenner tumor and struma ovarii: case report. *Eur J Gynaec Oncol* 2005; 26: 109-10.
- Yoshida M, Obayashi C, Tachibana M, Minami R. Coexisting Brenner tumor and struma ovarii in the right ovary: Case report and review of the literature. *Pathol Int* 2004; 54: 793-7.
- Volpi E, Ferrero A, Nasi PG, Sismondi P. Malignant struma ovarii: a case report of laparoscopic management. *Gynecol Oncol* 2003; 90: 191-4.
- Salvatori M, Dambra DP, D'Angelo G, Conte LL, Locantore P, Zannoni G, Campo V, Campo S. A case of metastatic struma ovarii treated with 131I therapy: focus on preservation of fertility and selected review of the literature. *Gynecol Endocrinol* 2008; 24: 312-9.
- Roth LM, Karseladze AI. Highly differentiated follicular carcinoma arising from struma ovarii: a report of 3 cases, a review of the literature, and a reassessment of so-called peritoneal strumosis. *Int J Gynecol Pathol* 2008; 27: 213-22.
- Lim ST, Jeong HJ, Chung MJ, Yim CY, Sohn MH. Malignant struma ovarii demonstrated on post-therapy radioiodine scan after total thyroidectomy for papillary thyroid cancer. *Clin Nucl Med* 2008; 33: 429-31.
- Roth LM, Talerma A. The enigma of struma ovarii. *Pathology* 2007; 39: 139-46
- Hatami M, Breining D, Owers RL, Del Priore G, Goldberg GL. Malignant struma ovarii - a case report and review of the literature. *Gynecol Obstet Invest* 2008; 65: 104-7.