

# Henoch-Schönleinova purpura pri odraslem

## Henoch-Schönlein purpura in adulthood

**Avtor / Author**

**Ustanova / Institute**

**Helena Skačej, Iztok Holc, Artur Pahor**

Univerzitetni klinični center Maribor, Klinika za interno medicino,

Oddelek za revmatologijo, Maribor, Slovenija

University Medical Centre Maribor, Department of Rheumatology, Internal Medicine  
Clinic, Maribor, Slovenia

**Ključne besede:**

sistemski vaskulitis, Henoch-Schönleinova purpura, odrasli bolnik

**Key words:**

systemic vasculitis, Henoch-Schönlein purpura, adult patient

**Članek prispel / Received**

06.04.2008

**Članek sprejet / Accepted**

23.10.2009

**Naslov za dopisovanje /**

**Correspondence**

Doc. dr. Artur Pahor, dr. med.

Univerzitetni klinični center

Maribor, Klinika za interno

medicino, Oddelek za revmatologijo,

Ljubljanska 5, Maribor, Slovenija

Fax: 02 33 22 128

E-pošta: artur.pahor@ukc-mb.si

**Izvleček**

**Izhodišča:** Henoch-Schönleinova purpura (HSP) je sistemsko vnetje sten malih žil, ki najpogosteje prizadene otroke. Odrasli obolijo redko, potek bolezni pa je pri njih lahko življenjsko ogrožujoč. Za HSP je značilna tetrada kliničnih znakov, ki zrcali okvaro kože, sklepov, prebavnega trakta in ledvic. Pri postavitvi diagnoze je potrebno upoštevati zastavljena diagnostična merila. Učinkovito specifično zdravljenje bolezni pri otrocih in odraslih še ne obstaja. Kljub temu pa je pri težjem poteku z agresivnejšim terapevtskim pristopom možno doseči stabilno klinično sliko.

**Priказ primera:** Predstavljen je primer 59-letnega imunsko neprizadetega bolnika, pri katerem je bila potrjena izjemno težka oblika HSP. Razpravljamo o epidemiologiji, etiopatogenezi, klinični sliki, diagnostičnih postopkih, diferencialni diagnozi, zdravljenju in prognozi te bolezni.

**Abstract**

**Background:** Henoch-Schönlein purpura (HSP) is a systemic inflammation of small-vessel walls that predominantly affects children. In adults, on the other hand, it appears rarely, and can be more severe. The disease is characterised by a tetrad of clinical signs which manifest the skin, joint, gastrointestinal, and kidney involvement. HSP is diagnosed using internationally-accepted criteria. At present, there is no effective specific therapy for children and adults. However, in cases of severe organ involvement, aggressive treatment may stabilise the disease.

**Case report:** We present a case of a 59-year-old immunologically uncompromised patient with an extremely severe form of HSP. Epidemiology, etiopathogenesis, clinical features, diagnostic procedures, differential diagnosis, treatment, and prognosis of the disease are discussed.

**Zaključki:** Pri bolniku je bilo uvedeno zdravljenje s kortikosteroidi, humanimi polispecifičnimi imunoglobulini ter citostatiki. Doseženo je bilo zadovoljivo začasno izboljšanje bolezni.

**Conclusions:** The patient was treated with corticosteroids, human polyspecific immunoglobulins, and immunosuppressive agents. A satisfactory clinical remission has been achieved.

## INTRODUCTION

Henoch-Schönlein purpura (HSP) is a systemic inflammation of small-vessel walls that affects skin and internal organs (1). The first records of the disease come from the 19th century, when Schönlein noticed a link between arthralgia and purpura (2). A few decades later, Henoch, who was his student, noted the adverse effects on the digestive tract and kidneys. The disease may occur independently (primary form) or can be the result of other conditions (secondary form), for instance, malignant disease or infection (1).

HSP is the commonest systemic vasculitis in children, who represent 90 % of all patients (1). The condition occurs most frequently between the ages of 4 and 11. Nevertheless, this disease is one of the commonest forms of the adult systemic vasculitides. The annual incidence is approximately 135/1000000 in children and 14/1000000 in adults (3). According to some data, HSP affects males more frequently than females (4).

## Case report

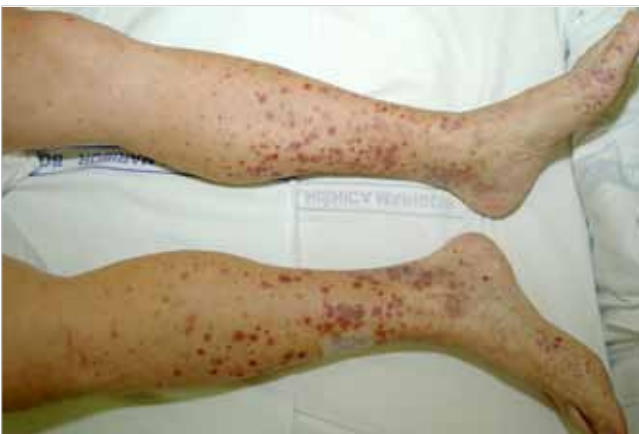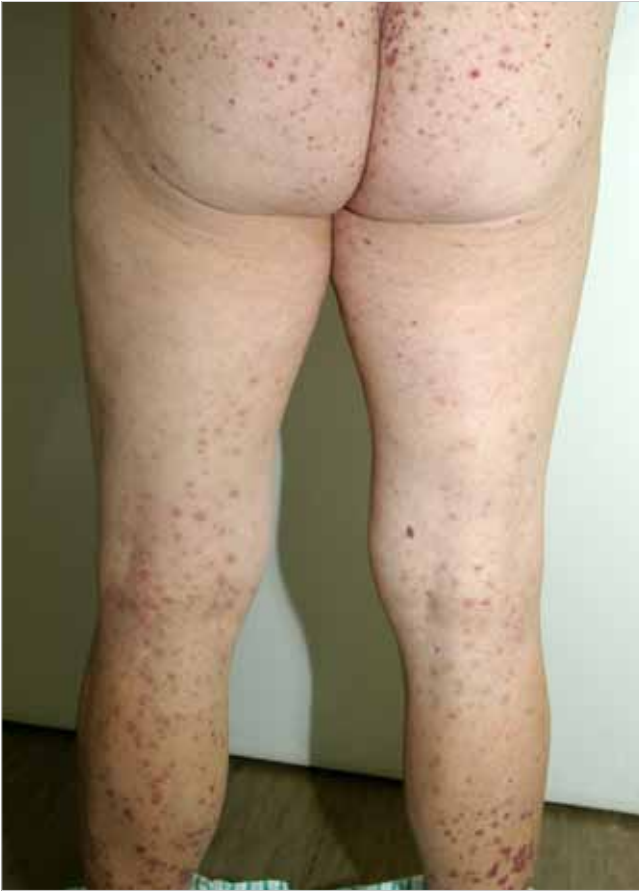In March 2007, a 59-year-old previously healthy man was on holiday in Turkey and Egypt. One month later, he had a sore throat. After few days, he noticed livid, red, target-shaped rashes of various sizes on his forearms and shanks. They gradually spread across his whole lower and upper extremities, the lower part of the abdomen, and the gluteal region.

He was admitted to the Department of Dermatology, Teaching Hospital Maribor. On the second day of

hospitalisation, he had convulsive abdominal pain. He vomited, excreted liquid feces with no traces of blood, but was hypertensive. Laboratory blood test results showed increased markers of inflammation and microhematuria. An exploratory skin excision was performed and histopathological examination revealed leukocytoclastic vasculitis. The patient was transferred to the Department of Rheumatology, Teaching Hospital Maribor, for further investigation.

After transfer, he was conscious and cardiovascularly stable. His blood pressure was 160/90 mm Hg. Physical examination of the lungs, heart and abdomen was normal. Swelling and reduced mobility were present in the knees and elbows, but no redness or heat. A palpable purpuric exanthema was visible on the skin of all four extremities, the gluteal region, the lower part of the abdomen, and the back (Figs. 1 and 2).

At the time of admission to the Department of Rheumatology, he had a leukocytosis of  $16.6 \times 10^9$  E/l (normal range  $4.0\text{--}10.0 \times 10^9$  E/l), increased C-reactive protein (CRP, 70 mg/l, normal range up to 5 mg/l), and normal erythrocyte sedimentation rate (ESR). Hemoglobin and thrombocyte values were within physiological limits. The concentration of bilirubin was increased (total bilirubin 30  $\mu\text{mol/l}$ , normal range up to 17  $\mu\text{mol/l}$ ; direct bilirubin 10  $\mu\text{mol/l}$ , normal range up to 5  $\mu\text{mol/l}$ ), but the remaining liver tests were normal. The fasting blood sugar level was high (13.6 mmol/l, normal range 3.6–6.1 mmol/l). Electrolyte concentrations were within normal values. The concentrations of urea and creatinine, however, were above normal (urea 16.2 mmol/l, normal range 2.8–7.5 mmol/l; creati-



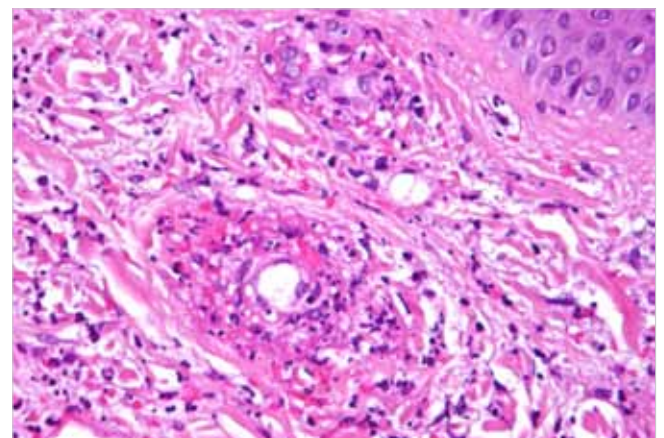
**Figures 1-2.** The appearance of the patient's skin on admission.

nine  $141 \mu\text{mol/l}$ , normal range  $44\text{--}97 \mu\text{mol/l}$ ). The results of the antistreptolysin test were increased (283 IU, normal range up to 200 IU). A throat smear confirmed the presence of group A streptococcus. Immunoglobulin A (IgA), G (IgG), and M (IgM)

levels were within normal limits. The concentration of immunoglobulin E (IgE), however, was increased (642 IU/ml, normal range up to 100 IU/ml). Antinuclear antibodies (ANA), anti-double stranded DNA antibodies (anti DNA), IgG anti-neutrophil cytoplasmic antibodies (ANCA), anti Jo-1 antibodies, anti-glomerular basement membrane antibodies (anti-GBM), and rheumatoid factor (RF) were within normal limits. Cryoglobulins and tumor markers were negative. There was glucosuria (1 IU, normal value 0 IU) and 5–10 erythrocytes in the urinary sediment. Urine cultures were negative.

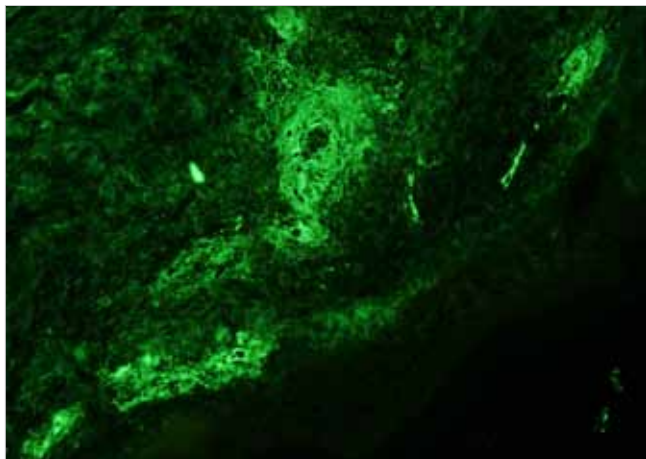
During the first days, the patient excreted liquid feces with admixtures of blood and he complained of abdominal pain. He was fasted and treated with intravenous infusions of physiological solution and glucose with insulin. Esomeprazole, trospium, tramadol with thiethylperazine, and ciprofloxacin were given parenterally. Abdominal and chest X-rays did not reveal any abnormalities. Amlodipine and fosiopril were introduced because of increased blood pressure. Methylprednisolone was also prescribed in a dose equivalent to  $0.5 \text{ mg/kg}$  of prednisolone perorally.

On the fourth day of hospitalisation, additional skin changes appeared in the form of red maculae, especially on the extremities, the lower part of the abdomen, and the gluteal region. The patient was



**Figure 3.** Histopathologic image of the patient's skin biopsy: small-vessel leukocytoclastic vasculitis (hematoxylin and eosin, original magnification  $\times 400$ ).





**Figure 4.** Immunofluorescent image of the patient's skin biopsy: granular IgA deposits in small-vessel walls (direct immunofluorescence, original magnification x400).

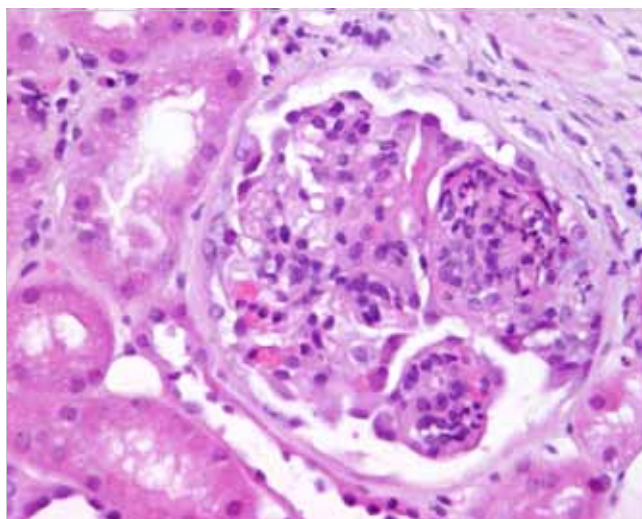
cardiovascularly unstable. The dose of methylprednisolone was increased to the equivalent to 1 mg/kg of prednisolone and a human polyspecific immunoglobulin was added parenterally in a dose of 25 g/day for four days. Ciprofloxacin was replaced by intravenous ceftriaxone. Hemocultures were negative. Thrombocyte and coagulation test values remained constantly within physiological limits. A second skin biopsy was performed. The histopathological examination again pointed to leukocytoclastic vasculitis (Figure 3) and immunofluorescence testing was characteristic for HSP (Figure 4).

Later on, anemia and blood in the stool were discovered and esophagogastroduodenoscopy was performed. There were circular hyperemic changes in the mucous membrane of the upper gastrointestinal tract but no signs of active or past bleeding. Esophageal candidiasis was visible and *Candida albicans* was detected in the feces. Histological examination of the mucous membrane of the stomach revealed a non-*Helicobacter pylori* chronic active gastritis and of the mucous membrane of the intestine suggested chronic colitis.

The patient was given blood transfusions and treated with fluconazole intravenously, miconazole in the

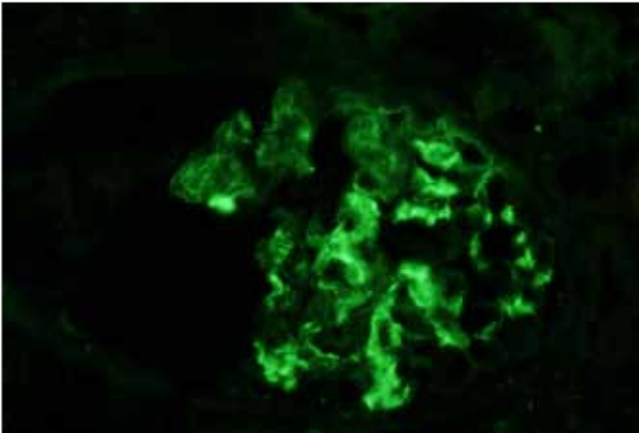
form of an oral gel, and moxifloxacin intravenously. After three weeks, intravenous methylprednisolone was replaced with oral steroids in a tapering dose. The infusions were gradually stopped. Abdominal ultrasound indicated some excess fluid around the liver and colonic flexures and in the Douglas space. Cytological examination of the aspirated fluid did not reveal malignant cells. Abdominal computed tomography did not show any major pathology. Liver function tests revealed increased liver enzymes and bilirubin and decreased synthetic liver function. The patient was examined by a gastroenterologist who concluded that there was an autoimmune activity in the liver as a part of a systemic disease or its treatment.

During hospitalisation, acute kidney failure with proteinuria and hypoalbuminemia occurred. A kidney ultrasound did not reveal any abnormalities. Peripheral edema emerged and the patient was given furosemide and underwent a kidney biopsy. Direct immunofluorescence and histopathological test results showed glomerulonephritis as a part of HSP. Histomorphologically, there was a very uneven, diffuse, segmented necrotizing (8/15), extracapillary crescentic (7/15), endocapillary proliferative (7/15), and exudative



**Figure 5.** Histopathologic image of the patient's venal biopsy: segmental endocapillary proliferation with exudation of granulocytes (hematoxylin and eosin, original magnification x400).

glomerulonephritis (2/17) with active inflammatory changes, focal global glomerulosclerosis (1/15), and glomerulae (5/15) with clearly uneven, moderate mesangial cell proliferation (Figs. 5 and 6).



**Figure 6.** Immunofluorescent image of the patient's renal biopsy: mesangial IgA deposits in a granular pattern (direct immunofluorescence, original magnification x400).

The patient was given the first pulse of cyclophosphamide, 15 mg/kg, intravenously. He also received a mesna substance, granisetron, and low-molecular-weight heparin at therapeutic dosages. A four-day treatment with human polyspecific immunoglobulin, 30 g/day, was reintroduced. The patient's clinical status gradually improved.

On the basis of diagnostic procedures performed, an extremely aggressive form of systemic vasculitis, evolving into the Henoch-Schönlein purpura type, was confirmed. After more than a month, the patient was discharged from the hospital. At that time, his hemoglobin was low and creatinine and urea concentrations were elevated. Proteinuria was still present (3.7 g protein/day). Treatment with prednisolone was gradually tapered to 20 mg/day.

During the following months, the patient received intravenous pulse therapy with cyclophosphamide once per month and underwent regular laboratory

check ups. After a few months, a satisfactory improvement in his condition was observed. Side effects of the treatment, however, did occur in the form of pronounced Cushing's syndrome. The patient had his last check up in January 2009. At that time, his clinical status was stable. A normalization of liver tests (aspartate aminotransferase 0.15  $\mu$ kat/l, normal range up to 0.58  $\mu$ kat/l; alanine aminotransferase 0.43  $\mu$ kat/l, normal range up to 0.74  $\mu$ kat/l; gamma-glutamyl transferase 0.88  $\mu$ kat/l, normal range up to 0.92  $\mu$ kat/l) and kidney functions tests (urea 7.1 mmol/l, normal range 2.8–7.5 mmol/l; creatinine 86  $\mu$ mol/l, normal range 44–97  $\mu$ mol/l) was detected. Semiquantitatively, no proteinuria was observed.

## DISCUSSION

This adult male patient had no past history of any serious disease. Because HSP is an illness that usually occurs during childhood (1), accounts of cases of adult patients are rare.

The etiology and pathogenesis of HSP have not yet been finally determined. It has been suggested that there is a genetic predisposition and a probable hypersensitivity reaction to certain trigger factors, and the latter are detected in around half of the patients. As a response to a trigger factor, immune complexes containing IgA are created. They are deposited in small vessel walls (1–3), where they cause a variety of pathological changes. Histopathologically, inflammation of small vessels is expressed as leucocytoclastic vasculitis (3).

The latter was detected in our patient. Sore throat, elevated value of the antistreptolysin test, and isolation of group A streptococcus from the throat smear pointed to a streptococcal infection as a possible trigger factor for the disease. Moreover, elevated concentrations of IgE suggested an allergic reaction to a specific antigen. However, there was no history of other trigger factors, such as of food or drug allergy, insect bites, or immunisation. The family history was negative for HSP.

HSP often begins acutely and develops during a period of days and weeks. HSP is characterised by the following four groups of clinical signs and symptoms (1):

1. nonthrombocytopenic symmetrical palpable purpura,
2. impairment of joints,
3. gastrointestinal disease,
4. kidney disease.

In our patient, symmetrical nonthrombocytopenic purpura, as well as the involvement of the joints, gastrointestinal tract, and kidneys, was observed. The patient thus experienced the four characteristic features of HSP.

In order to confirm the diagnosis, numerous laboratory tests were carried out. The elevated markers of inflammation could have been the result of an acute (i.e. streptococcal) infection or a chronic, systemic inflammation. In HSP patients, serum concentrations of IgA are elevated in 50–70 % of cases (5). In our patient, the concentration of IgA was within normal limits. If there is a possibility of a severe vasculitic activity, immunoserologic testing should also be carried out but the results were normal in our patient.

Histopathological tests of affected tissues are of major importance in the diagnosis of HSP. The patient's skin biopsy showed a characteristic image of leukocytoclastic vasculitis, which was especially evident in the postcapillary venules. However, this is a non-specific finding. In order to confirm HSP, an immunofluorescence test, revealing deposits of IgA in the small vessel walls, is also required (1), and our skin biopsy test duly confirmed HSP (Figure 3, 4).

A kidney biopsy is required if the diagnosis is uncertain or there is suspicion of severe organ involvement. Histopathological and immunofluorescence tests of an HSP patient's kidney samples can expose a specter of changes from isolated mesangial cell proliferation to severe crescentic glomerulonephritis (6). Mesangial IgA deposits, which are visible by the immunofluorescence, are a diagnostic finding

(2). Due to signs of kidney failure and nephrotic syndrome, a biopsy of our patient's kidneys was carried out, and showed severe involvement of this organ as a part of his HSP (Figure 5, 6).

In 1990, the American College of Rheumatology determined the following diagnostic criteria for HSP (7):

1. non-thrombocytopenic palpable purpura,
2. age not older than 20 years at the onset of the disease,
3. acute abdominal pain,
4. histologically visible granulocytes in the walls of arterioles or venules.

If at least two of these criteria are met, an HSP diagnosis can be made with approximately 90 % sensitivity and specificity (1, 3). The patient under discussion fulfilled all HSP criteria except age.

The differential diagnosis during his initial presentation included primary and secondary vasculitides. In the group of primary vasculitides, the following conditions were possible: mixed cryoglobulinemia, hypersensitivity vasculitis, and microscopic polyangiitis. For a diagnosis of mixed cryoglobulinemia, the presence of cryoglobulins (3) is of key importance. In our patient's case, however, these values were within the normal limits. In cases of hypersensitivity vasculitis, there are usually only skin involvement and general symptoms (1, 3, 6). Histopathologically, this is a leukocytoclastic vasculitis of postcapillary venules but without IgA deposits in vessel walls (3). Our patient, however, had IgA deposits in both the skin and kidneys and had severe systemic involvement. The presence of ANCA is characteristic of microscopic polyangiitis (3). Histopathologically, segmental necrosis of small vessel walls is visible in the affected tissue but there are very few or no immune deposits (3). Our patient was ANCA negative and his histopathologic or immunohistological test results also contradicted this thesis.

The patient's disease could also have emerged as a secondary vasculitis in response to an infection or

a malignancy (1). Consequently, serological tests were carried out for leptospirosis, rickettsia, coxiella, ehrlichiosis, *Borrelia burgdorferi*, *Mycoplasma pneumoniae*, Hantaan viruses, hepatitis, and human immunodeficiency virus. The results did not confirm the presence of any of these infections.

Palpable purpura can be a sign of paraneoplastic vasculitis, especially due to hematologic neoplasms or solid tumors (1). In our patient's case, these diseases were excluded with a high degree of certainty.

Although many drugs have been proposed as HSP treatments, their roles have not yet been fully established. Despite many reports on the benefits of various combinations of drugs, the prevailing belief is that there is no effective method for treating HSP patients (2). Nevertheless, in advanced forms of the disease, especially in cases of severe kidney involvement, an aggressive therapeutic approach is recommended (8). This includes, for instance, pulse treatment with methylprednisolone, immunomodulating drugs (e.g. azathioprine, cyclophosphamide, or cyclosporin), plasmapheresis, and high dosages of parenteral immunoglobulins.

Other treatment options for HSP patients, as suggested by the literature, include heparin or warfarin, dipyridamole (9), recombinant interferon alpha or natural interferon beta, danazol, thalidomide (10), and tonsillectomy (8). In cases of chronic kidney failure, a kidney transplantation is indicated.

If the disease expresses itself in a milder form, supportive treatment is sufficient. This includes appropriate hydration, rest, and pain alleviation.

Initially, our patient received supportive treatment and corticosteroids perorally. After skin changes re-emerged and he became more severely ill, a decision was made to introduce more aggressive treatment with parenteral corticosteroids and human polyclonal immunoglobulins. On the basis of abnormal histopathologic and immunofluorescence kidney biopsy results, the patient was prescribed intravenous

pulse treatment with cyclophosphamide. He is still receiving intravenous pulses of cyclophosphamide, tapering doses of corticosteroids, and supportive treatment.

In terms of prognosis, in children HSP falls into the category of relatively easily-managed systemic vasculitides. In this population, it is a benign and spontaneously curable disease (1, 3, 11). Adults, however, can be more severely affected (4); internal organ damage is more frequent (11) and can threaten the patient's life.

Kidney involvement is the main cause of morbidity and mortality in HSP patients (8). The long-term prognosis is thus directly linked to the kidney disease (3). 10–30 % of adult patients have chronic kidney failure in the 15 years after developing HSP (11). Prospects in terms of kidney function are even worse for patients with the following features: age over 50 years (11); crescentic glomerulonephritis, especially in more than 50 % of glomeruli (12); tubulointerstitial nephritis with kidney failure in the initial stages of the disease; proteinuria above 1.5 g/day; hypertension (12); macroscopic hematuria (11); and recurrences of the disease. In our patient, many of these criteria were present.

## CONCLUSION

The article describes an adult patient with no previous history of serious disease who developed a systemic vasculitis of the Henoch Schönlein purpura type. Many factors pointed to a poor disease prognosis. Treatment involved corticosteroids, human polyclonal immunoglobulins, and cytostatics. A satisfactory temporary improvement of the patient's clinical status has been achieved.

## ACKNOWLEDGEMENTS

The authors express gratitude to the following colleagues: Prof. Dušan Ferluga, MD, PhD, Ass. Prof.



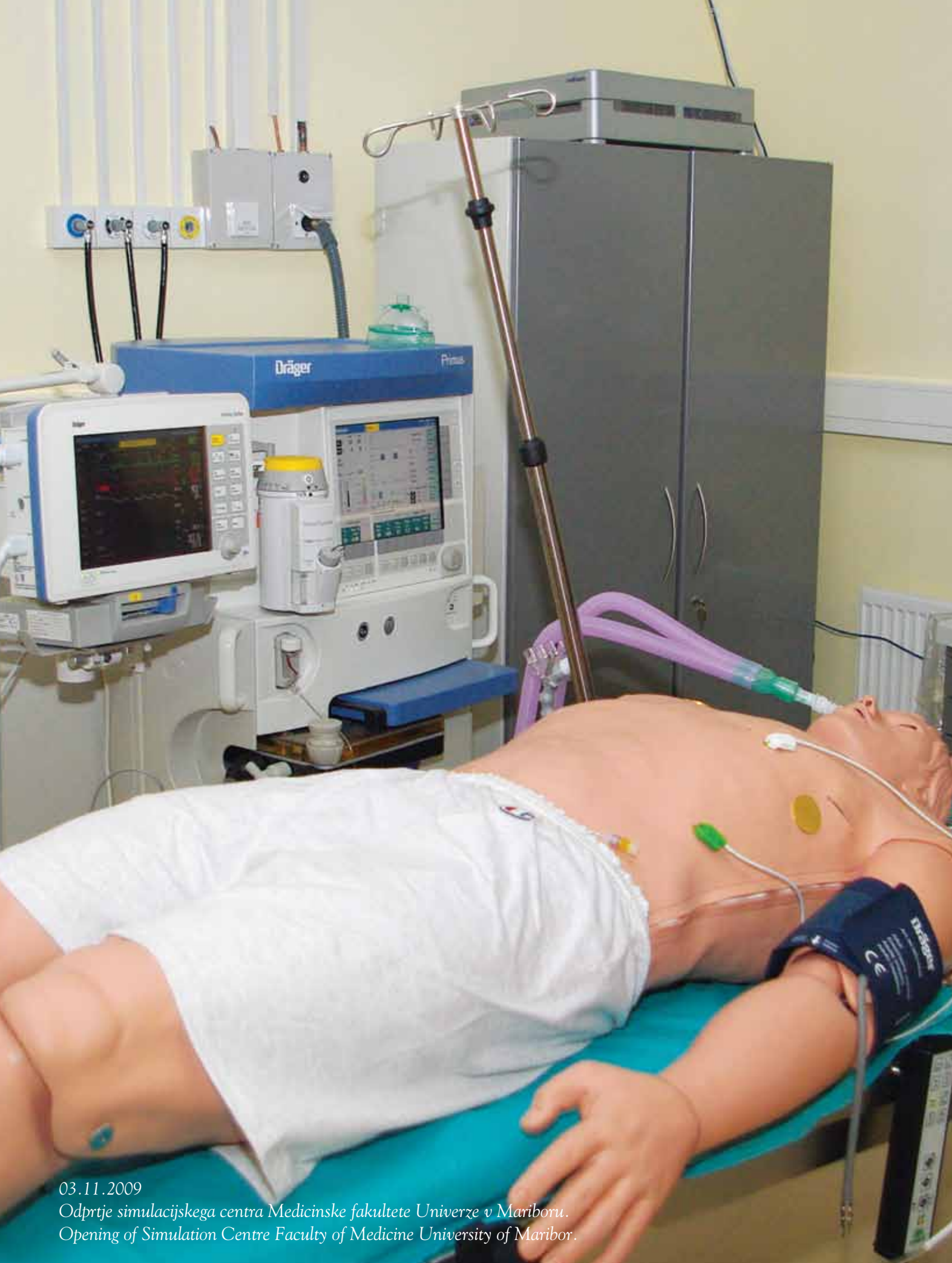Vesna Jurčić, MD, PhD, and senior scientist Alenka Vizjak, biologist, PhD, from the Institute of Pathol-

ogy, Faculty of Medicine, University of Ljubljana, for the images used in the article.

## REFERENCES

1. Stone JH. The Classification and Epidemiology of Systemic Vasculitis. In: Harris ED, Budd RC, Firestein GS, Genovese MC, Sergent JS, Ruddy S, et al. *Kelley's Textbook of Rheumatology*. 7th ed. Philadelphia: Elsevier Saunders; 2005. p. 1336-42.
2. Kellerman PS. Henoch-Schönlein purpura in adults. *Am J Kidney Dis* 2006; 48 (6): 1009-16.
3. Tomšič M. Revmatične bolezni. In: Kocijančič A, Mrevlje F, Štajer D. *Interna medicina*. 3. izd. Ljubljana: Littera Picta 2005; p. 1315-442.
4. Garcia-Porrua C, Calvino MC, Llorca J, Couselo JM, Gonzalez-Gay MA. Henoch-Schönlein purpura in children and adults: Clinical differences in defined populations. *Semin Arthritis Rheum* 2002; 32 (3): 149-56.
5. Davin JC, Ten Berge IJ, Weening JJ. What is the difference between IgA nephropathy and Henoch-Schönlein purpura nephritis? *Kidney Int* 2001; 59: 823-4.
6. Rott KT, Gonzalez EB, Conn DL. Cutaneous Small-Vessel Vasculitis. In: Harris ED, Budd RC, Firestein GS, Genovese MC, Sergent JS, Ruddy S, et al. *Kelley's Textbook of Rheumatology*. 7th ed. Philadelphia: Elsevier Saunders 2005; p. 1388-95.
7. Mills JA, Michel BA, Bloch DA, Calabrese LH, Hunder GG, Arend WP, et al. The American College of Rheumatology 1990 criteria for the classification of Henoch-Schönlein purpura. *Arthritis Rheum* 1990; 33 (8): 1114-21.
8. Sugiyama H, Watanabe N, Onoda T, Kikumoto Y, Yamamoto M, Maeta M, et al. Successful treatment of progressive henoch-schönlein purpura nephritis with tonsillectomy and steroid pulse therapy. *Int Med* 2005; 44 (6): 611-5.
9. Oner A, Tinaztepe K, Erdogan O. The effect of triple therapy on rapidly progressive type of Henoch-Schönlein nephritis. *Pediatr Nephrol* 1995; 9: 6-10.
10. Choi SJ, Park SK, Uhm WS, Hong DS, Park HS, Park YL et al. A case of refractory Henoch-Schönlein purpura treated with thalidomide. *Korean J Intern Med* 2002; 17: 270-3.
11. Pillebout E, Thervet E, Hill G, Alberti C, Vanhille P, Nochy D. Henoch-Schönlein purpura in adults: outcome and prognostic factors. *J Am Soc Nephrol* 2002; 13: 1271-8.
12. Coppo R, Mazzucco G, Cagnoli L, Lupo A, Schena FP. Long-term prognosis of Henoch-Schönlein nephritis in adults and children. *Nephrol Dial Transplant* 1997; 12: 2277-83.





03.11.2009

*Odprije simulacijskega centra Medicinske fakultete Univerze v Mariboru.  
Opening of Simulation Centre Faculty of Medicine University of Maribor.*