

# Nekrozantni fasciitis v obliki Fourniejeve gangrene pri 70 let staremu pacientu

## Necrotizing fasciitis in the form of Fournier gangrene in a 70 year old patient

**Avtor / Author**

**Ustanova / Institute**

**Nuhi Arslani<sup>1</sup>, Timotej Mikuljan<sup>1</sup>**

<sup>1</sup>Univerzitetni klinični center Maribor, Klinika za kirurgijo, Oddelek za abdominalno in splošno kirurgijo, Maribor, Slovenija

<sup>1</sup>University Medical Centre, Division of Surgery, Department of Abdominal and General Surgery, Maribor, Slovenia

**Ključne besede:**

dekompenziran adhezijski ileus, nekrozantni fasciitis, nekrektomija, eksplorativna laparotomija, dekompresija preko nazograstične sonde

**Key words:**

decompensated adhesive ileus, necrotizing fasciitis, necrectomy, exploratory laparotomy

**Članek prispel / Received**

17.11.2014

**Članek sprejet / Accepted**

03.03.2015

**Naslov za dopisovanje /  
Correspondence**

Asist. dr. Nuhi Arslani dr. med, Klinika za kirurgijo, Oddelek za abdominalno kirurgijo, Univerzitetni klinični center Maribor, Ljubljanska 5, SI-2000 Maribor, Slovenija.  
Telefon +386 70643119  
Fax +386 23211417  
E-pošta: arslani.nuhi@gmail.com

**Izvleček**

**Namen:** Namen tega članka je opisati primer obolelega pacienta s Fournierjevo gangreno in prikazati proces njegovega zdravljenja in razreševanja zapletov, ki so pri tem nastali.

**Poročilo o primeru:** Pacient je 70. let stari moški, ki je bil hospitaliziran zaradi nekrozantnega fasciitisa perianalno. Narejena je bila radikalna nekrektomija mehkih tkiv, drenaža perianalnega abscesa, in transverzostoma. Na podlagi antibiogramov sta bila predpisana antibiotika Amoksiklav in Ciprobay. Kasneje je prišlo do dekompenziranega adhezijskega ileusa, kar je terjalo ponoven operativen poseg.

**Zaključek:** Fournierjeva gangrena je redka bolezen, ki navadno prizadene moške. Bolezen se začne z otekanjem, celulitisom, višjo temperaturo in vonjem. Naš primer opisuje uspešno zdravljenje boleznin z urgentno operacijo in ponovnim operativni posegom zaradi pooperativnega zapleta.

**Abstract**

**Purpose:** In this case report, we describe a patient with Fournier gangrene, as well as his treatment course and management.

**Case report:** A 70-year-old male was hospitalized for Fournier gangrene in the perianal region. We performed radical necrectomy, drainage of perianal abscess, and transversostomy. Based on wound culture results, Amoxiclav and Ciprobay were administered. The complication of decompensated adhesive ileus occurred, which required reoperative intervention.

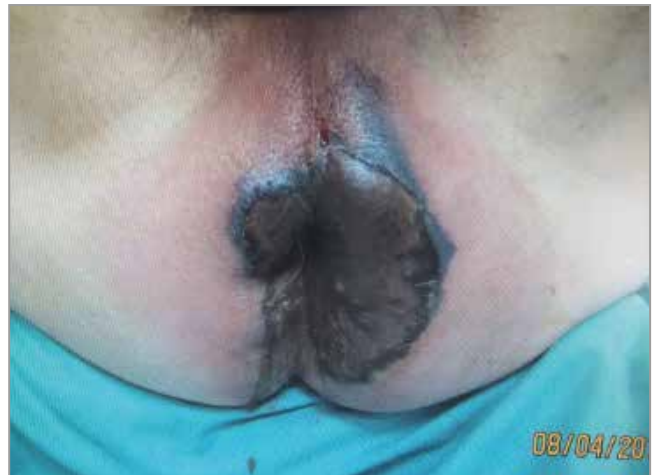**Conclusion:** Fournier gangrene is a rare disease that usually affects males. The disease begins with swelling, cellulitis, fever, and odor. We successfully treated this disease with emergency surgery and reoperative intervention.

## INTRODUCTION

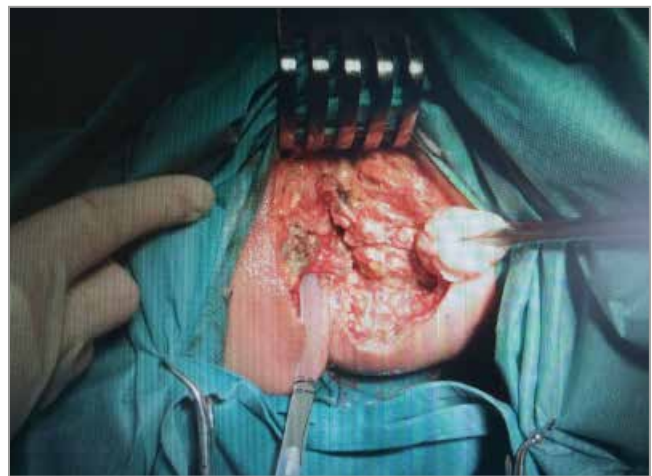
Fournier gangrene was first described in 1764 by Baurienna. It was named after Fournier, who reported five cases of this disease in 1883. Fournier gangrene is a necrotizing fasciitis that affects the subcutaneous tissue of the perineum and genitals. The disease is usually caused by an aerobic or anaerobic infection of the colon, the rectum, the lower part of the genitourinary tract, or cutaneous infection of genitalia, perineum and the anus. Microorganisms that are usually isolated include *Escherichia coli*, *Enterococci*, *Staphylococci*, *Streptococci*, *Bacterioides fragilis*, and *Pseudomonas aeruginosa*. Superficial skin damage, genitourinary or colorectal diseases can create points of entry leading to genitourinary sepsis, sepsis of the prostate, perianal sepsis, and ischiorectal abscess. Immune system dysfunction also plays an important role in disease development, with the most common etiologies being diabetes, obesity, alcoholism, malignancy, and immunosuppression. Signs of the disease include swelling, cellulitis, necrosis, crepitation, fever, and odor. The disease is treated surgically with radical necrectomy and administration of broad spectrum antibiotics. The mortality rate nears 50%.

## CASE REPORT

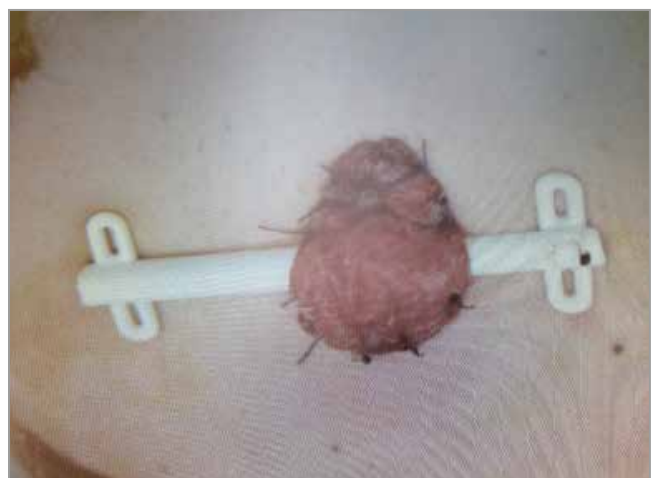A 70-year-old male was admitted to our hospital with bilateral gluteal inflammation. His medical history included long standing hemorrhoids (more than 30 years). In the previous three years, he complained of liquid stool mixed with mucus. His symptoms started one week prior to admission and included right gluteal induration, which had expanded to the left gluteal region. He also complained of severe pain, fever, and uncontrolled leakage of stool. At admission, he had persistent pain, he was tachycardic with a heart rate of 91 beats per minute, his arterial blood pressure was 126/69 mm Hg, and his body temperature was 36.6° C. On physical examination, his left and right gluteal regions revealed a visibly necrotic area (Figure 1). There was palpable fluctuation on palpation. A CT revealed infrarenal and right common iliac artery aneurysms. The patient was treated on the same day



**Figure 1.** Perianal necrotic tissue prior to surgery.

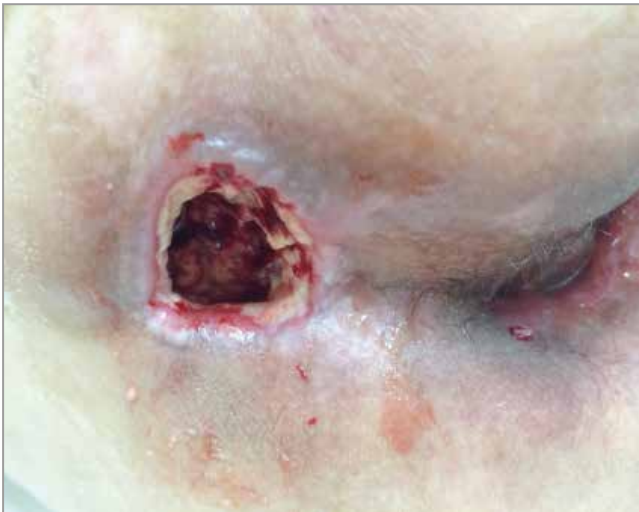

**Figure 2.** Immediately postoperatively.



**Figure 3.** Protective transversostomy.

with wide debridement of devitalized tissue, perianal abscess drainage, and transversostomy (Figures 2 and 3). The patient returned to the operating room 11 days after his first radical neorectomy, for further transanal drainage. Two days after the second operation, he developed a complication; decompensated adhesive ileus, requiring laparotomy. Intraoperatively, we found gastric distension with 2 L of gastric contents, which was aspirated. Thin intestinal convolutions were adhered in three regions in the left inguinal canal, in proximity to the sigmoid colon. After adhesiolysis and suturing, abdominal lavage was performed, followed by an appendectomy and drain placement. The incision was closed with a running suture. Next, the perianal region was addressed and a neorectomy and dressing replacement were performed. The patient was discharged approximately one month later (Figure 4). Wound cultures taken the day after the first



**Figure 4.** Wound healing by second intention one month postoperatively.

operation demonstrated the presence of *E. coli*, *Morganella morgani*, *Streptococcus anginosus*, *Enterococcus faecalis*, and several anaerobes, including at least one that was resistant to clindamycin. Based on the wound culture results, Amoxiclav and Ciprobay were prescribed.

## DISCUSSION

Fournier gangrene is a form of necrotizing fasciitis. In most cases, it affects men over 50 years of age. The infectious etiologies stem from pre-existing colorectal disease. Points of entry include cutaneous injury, urogenital sepsis, or perianal sepsis with aerobic and anaerobic organisms which act synergistically in tissue. The microorganisms most frequently isolated are caused by hemorrhoids. Clinical signs of Fournier gangrene include intense pain, fever, and swelling. The treatment involves administration of broad-spectrum antibiotics, supportive care if multiorgan system failure is present, and emergency surgery in the form of wide excision with serial debridements. The objective is to widely debride necrotic tissue until only healthy tissue remains. The patient is usually discharged one month after surgery. The most commonly isolated microorganism in wound cultures is *E. Coli*, which was also isolated in our case. The etiology in our case was perianal sepsis.

## CONCLUSION

Fournier gangrene is a rare disease with high mortality rate. We successfully treated our patient with emergency surgery, which included radical soft tissue neorectomy and transversostomy. It also describes the resolution of the early postoperative complications.

## REFERENCES

1. Agostini T, Mori F, Perello R, Dini M, Russo GL. Successful combined approach to a severe Fournier's gangrene. *Indian J Plast Surg* 2014;47:132-6.
2. Matilsky D, Lewiss R. E, Whalen M, Saul T. Fournier's Gangrene. Case report. *Med Ultrason* 2014, Vol. 16, no. 3, 262-3
3. Benjelloun et al.: Fournier's gangrene: our experience with 50 patients and analysis of factors affecting mortality. *World Journal of Emergency Surgery* 2013 8:13.
4. Prasan Kumar Hota. Fournier's Gangrene: Report of 2 Cases. Hindawi Publishing Corporation Case Reports in Emergency Medicine Volume 2012, Article ID 984195
5. Altarac S, Katušin D, Crnica S, Papeš D, Rajković Z, Arslani N. Fournier's gangrene: etiology and outcome analysis of 41 patients. *Urol Int.* 2012;88(3):289-93.
6. Vanden Bempt I, Van Trappen S, Cleenwerck I, Van De Vyvere M, De Vos P, Camps K, Celens A. *Actinobaculum schaalii* Causing Fournier's Gangrene. *Journal of clinical microbiology*, June 2011, p. 2369–71
7. Leung E, McArdle K, Yazbek-Hanna M. Pus swabs in incision and drainage of perianal abscesses: what is the point?. *WorldJ surg.* 2009 Nov;33(11):2448-51
8. Erikoglu M, Tavli S, Turk S. Fournier's gangrene after renal transplantation. *Nephrol Dial Transplant* (2005) 20: 449–50
9. Townsend, Beauchamp, Evers, Mattox, Sebastian text book of surgery, Philadelphia, Elsevier Saunders, 2004, chapter 76, Aria F. Olumi Jerome P. Richie ,p. 2297
10. Efem S.E.E. The features and aetiology of Fournier's gangrene. *Postgrad Med J* (1994); 70: 568-71