

# Nodozni poliarteritis pri 6-letni deklici – prikaz primera in pristop k obravnavi pediatričnih bolnikov

## Polyarteritis nodosa in a 6-year-old girl – a case report and overview of current management techniques of the disease in paediatric patients

Avtor / Author

Ustanova / Institute

Nataša Marčun Varda<sup>1,2</sup> Mirjam Močnik<sup>1</sup>

<sup>1</sup>Univerzitetni klinični center Maribor, Klinika za pediatrijo, Maribor, Slovenija; <sup>2</sup>Univerza v Mariboru, Medicinska fakulteta, Katedra za pediatrijo, Maribor, Slovenija;

<sup>1</sup>University Medical Centre Maribor, Department of Paediatrics, Maribor, Slovenia;

<sup>2</sup>University of Maribor, Faculty of Medicine, Division of Paediatrics, Maribor, Slovenia;

### Ključne besede:

vaskulitis, nodozni poliarteritis, diagnosticiranje, zdravljenje, otroci.

### Key words:

vasculitis, polyarteritis nodosa, diagnostic evaluation, treatment, children.

### Članek prispel / Received

25. 1. 2018

### Članek sprejet / Accepted

17. 4. 2018

### Naslov za dopisovanje /

#### Correspondence

Izr. prof. dr. Nataša Marčun Varda,  
dr. med., Klinika za pediatrijo, UKC  
Maribor, Ljubljanska 5,  
2000 Maribor, Slovenija  
Telefon: +386 23212416  
Fax: +386 23212465  
E-pošta: natasa.marcunwarda@amis.net

### Izvleček

**Namen:** V članku predstavljamo redek primer 6-letne deklice z nodoznim poliarteritisom (PAN), trenutna priporočila o sodobni obravnavi in zdravljenju in nove raziskave na tem področju. Slednje so pri otrocih potrebne zaradi jasne opredelitve prezentacije bolezni, odgovora na zdravljenje in prognoze. PAN je redka oblika vaskulitisa pri otrocih, ki prizadene srednje velike in majhne žile. Klinični potek je na začetku lahko zelo nespecifičen in prikrit in kot tak predstavlja diagnostični problem.

**Metode:** Uporabili smo naslednjo metodo: prikaz klinične slike bolnice, izvidov opravljenih preiskav, poteka njene obravnave ter pristopa k obravnavi, zdravljenju in spremljanju teh bolnikov.

**Rezultati:** Diagnoza pri deklici je bila potrjena z laboratorijsko in morfološko diagnostiko. Uvedli smo zdravljenje s kortikosteroidi in mikofenolat mofetilom, kar je vodilo v klinično izboljšanje, deklica pa potrebuje nadaljnje sledenje.

**Zaključek:** Zgodnja diagnoza in pravočasen začetek zdravljenja sta za do-

### Abstract

**Purpose:** In this article a rare case report of a 6-year-old girl with polyarteritis nodosa (PAN) is presented and current clinical and treatment recommendations and new research data are reviewed. The latter is needed to clearly describe disease presentation, treatment responses, and prognosis in children. PAN is a rare form of vasculitis in children, affecting medium- and small-sized arteries. Its clinical presentation can be quite unspecific and insidious at the beginning, presenting a diagnostic problem.

**Methods:** Presentation of the patient clinical characteristics, results of the investigation and treatment carried out, as well as the approach to management, treatment, and monitoring of patients with the same condition.

**Results:** Patient diagnosis was confirmed by laboratory and morphological diagnostics. Treatment with corticosteroids and mycophenolate mofetil was introduced, which led to clinical improvement. The patient requires further

bro prognozo in preprečevanje hudih nepopravljivih posledic te bolezni izrednega pomena. Za izboljšanje obravnave redkih pediatričnih bolnikov so potrebne nove multicentrične raziskave.

*lifelong follow-up.*

**Conclusions:** *Early diagnosis and timely initiation of treatment are of the utmost importance for good prognosis and prevention of devastating irreversible impairment caused by PAN. New multicentre research is needed to improve the treatment of rare paediatric patients with this condition.*

## INTRODUCTION

Childhood polyarteritis nodosa (PAN) is a primary systemic necrotizing vasculitis that predominantly targets medium-sized arteries (1). Although it is rare in children, it must be considered as a diagnostic possibility (2).

Diagnostic criteria include histologic evidence of necrotizing vasculitis in medium- or small-sized arteries or angiographic abnormalities, in addition to one of the following five criteria: skin involvement, myalgia or muscle tenderness, hypertension, peripheral neuropathy, and renal involvement (3).

Based on limited trial data in adults, conventional treatment of severe PAN in children requires corticosteroids combined with cyclophosphamide (2,4). Other immunosuppressive agents like mycophenolate mofetil (MMF), as well as biologic agents, including anti-TNF- $\alpha$  and rituximab, have also been used (1,5). Because relapses have been diagnosed in 75% of the cases, patients require close monitoring and follow-up to prevent further progression of the disease and treatment-related complications (6,7). However, with timely diagnosis and early treatment the prognosis and disease-related cumulative damage have been improved significantly (6).

In this report, a case of a 6-year-old girl admitted to the hospital with prolonged fever and subsequent PAN diagnosis is presented and current management of paediatric patients with this rare disease is discussed.

## CASE PRESENTATION

A 6-year-old girl admitted to our department two years ago, presented with three weeks of intermit-

tent febrile state and a rash on the face, appearing only when the body temperature was elevated. Before admission, the patient's appetite was decreased, she had lost some weight, and occasionally complained of headaches. There were no other symptoms present. The patient had previously been suspected to have late-onset congenital adrenal hyperplasia due to development of some signs of premature puberty. However, hormonal testing as well as magnetic resonance (MR) of the brain were normal.

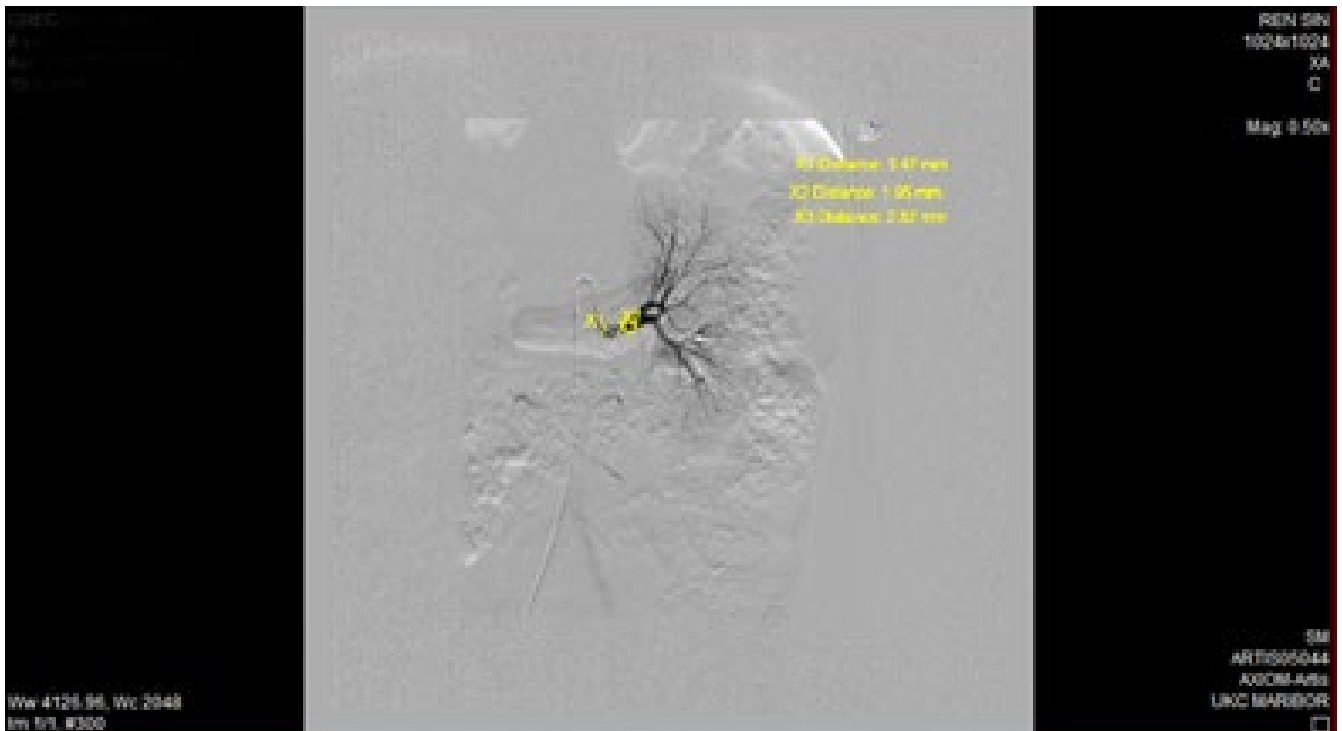
Upon admission to the hospital, febrile state with no obvious focus was confirmed and hirsutism, already evaluated before, was noticed. In addition, mildly elevated blood pressure (BP) was detected. The physical examination was otherwise normal.

Laboratory investigation showed increased erythrocyte sedimentation rate (SR) of 79 mm, elevated C-reactive protein level of 129 mg/L with mild leucocytosis of  $15 \times 10^9/L$ , and thrombocytosis of  $500 \times 10^9/L$ . Other haematological, biochemical, and hormonal tests, as well as urinalysis, were within normal range. First, acute causes of fever were investigated. However, blood cultures, serologic tests, microbiological tests to exclude all potential bacterial infections, and nasopharyngeal swab for viral pathogens, were negative. Imaging investigation was also normal. Anti-neutrophil cytoplasmic antibody (ANCA) was screened for twice and appeared normal, similar to other immunological tests. During diagnostic evaluation, persistently elevated BP was confirmed in the range of 145/100 mmHg, necessitating an investigation of all secondary causes of hypertension, including hormonal and renovascular ones. Both Doppler and magnetic resonance angiography (MRA) scans of the aorta and

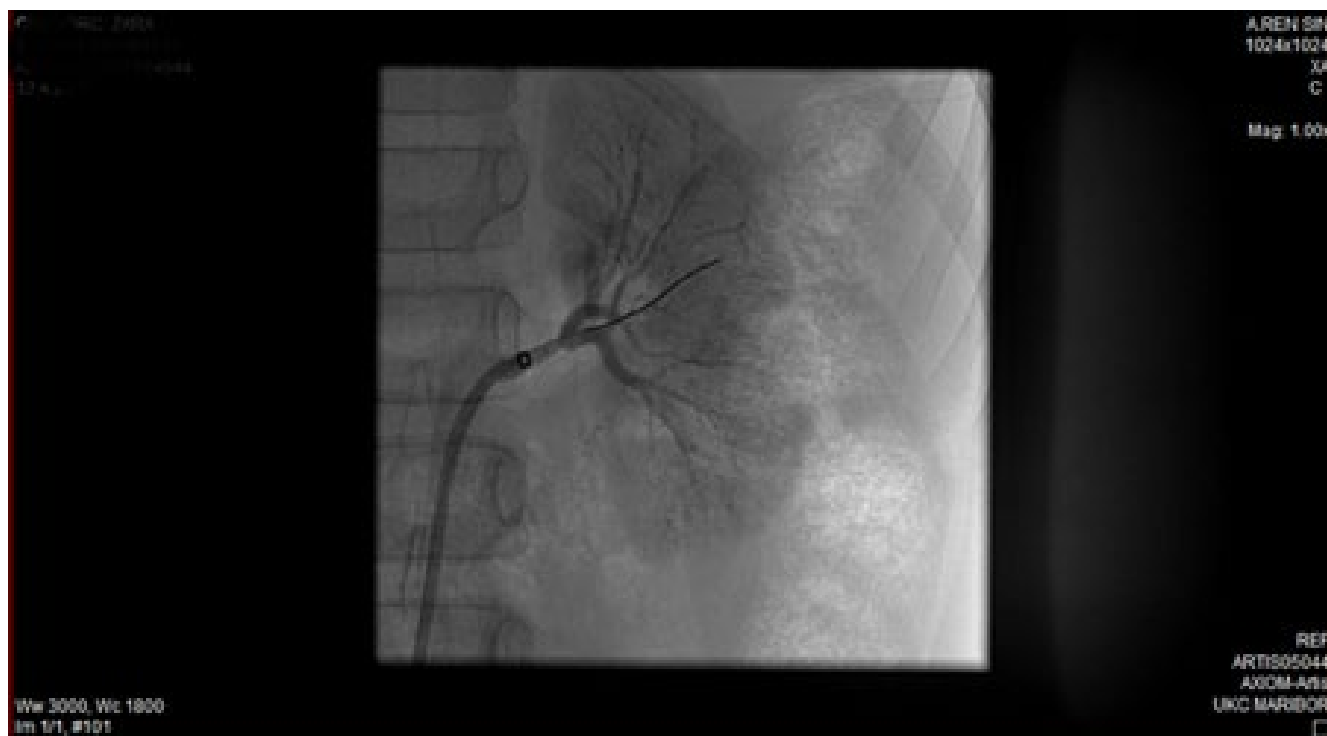renal arteries were normal. After four weeks, the patient's temperature normalised and SR decreased to 4 mm with no treatment. In addition, the patient's BP normalised with angiotensin-converting enzyme inhibitor enalapril treatment and she was determined to be clinically well. Due to her normal laboratory results and improved clinical state, the patient was discharged with instructions for BP monitoring and continued treatment with enalapril. At that point, the aetiology of hypertension remained unexplained.

The patient was admitted to the hospital again after four months, in April 2016, with a headache, vomiting, and elevated BP in a similar range as during the first hospitalisation, even though she was undergoing therapy. Elevated levels of creatinine (89  $\mu\text{mol/L}$ ) were detected for the first time, while urinalysis was normal. Enalapril treatment was terminated and a calcium channel antagonist and a beta blocker were

prescribed, decreasing BP to acceptable levels. The first course of action at that point was to perform renal angiography, when in addition to elevated creatinine, proteinuria in nephrotic range of 1.7 g/day was detected. Therefore, renal biopsy was performed and revealed focal segmental glomerulosclerosis (FSGS) and mild changes in the vessel walls, in accordance with BP levels. After BP normalisation, creatinine decreased to 60  $\mu\text{mol/L}$  and proteinuria decreased to 0.77 g/day. All immunological assays were normal and SR, although elevated for a short period of time again (38 mm), decreased to 25 mm. With these results in mind, it was finally decided to perform an X-ray renal angiography, where stenosis of the distal part of the left renal artery was detected. It was dilated with percutaneous transluminal angioplasty (PTA) and revealed diffuse medium-sized vessel changes, typical for PAN (Figure 1a, 1b).



**Figure 1a.** Conventional renal angiography showing stenosis of the distal part of the left renal artery dilated with PTA, as well as diffuse medium-sized vessel changes, typical for PAN.



**Figure 1b.** Conventional renal angiography showing stenosis of the distal part of the left renal artery dilated with PTA, as well as diffuse medium-sized vessel changes, typical for PAN.

In addition, milder changes in the vessels of the right kidney, as well as in hepatic arteries, have been detected with a Doppler scan of the abdominal arteries. MRA of the brain vessels was normal and there were no obvious changes in the large arteries. The patient was then diagnosed with vasculitis of medium-sized vessels, with FSGS and hypertension as secondary events. Genetic analysis of the CECR1 gene (encoding adenosine deaminase 2 enzyme) was negative. Treatment with methylprednisolone (8 mg every 8 h) in combination with MMF (500 mg twice a day) was introduced, according to the ongoing MYPAN (mycophenolate mofetil for PAN) study. Esomeprazole, calcium carbonate, and calcitriol were also administered. High values of BP were measured during the next few weeks, and a noticeable drop in BP occurred only after the combination of these four medications was introduced. After six weeks of therapy, the dose of methylprednisolone was tapered slowly, as BP remained significantly elevated and the patient exhibited a Cushingoid appearance. Acetylsalicylic acid at a dose of 50 mg was also administered. After BP normalisation, the patient felt well and physical examination

was normal, except for the persistent Cushingoid appearance. Laboratory results were normal, including SR and serum creatinine, and proteinuria decreased to 0.4 g/day. The patient's daily dose of methylprednisolone was decreased to 4 mg every other day, with other medications unchanged. During follow-up, laboratory markers and paediatric vasculitis activity score (PVAS) were employed. The latter was high during evaluation at 15/63, decreasing to 3/63 during treatment. Morphological vessel diagnostics is planned for future testing as well.

## DISCUSSION

In this report, a clinical case of a patient with PAN and current disease management techniques for paediatric patients with this condition are presented. In recent years important progress has been made in the field of diagnostics, treatment, and follow-up of paediatric patients with this rare disease, which was previously based on results from adult studies (1,5). PAN is characterized by inflammation of small- and

medium-sized arteries (1). Its presentation in children is similar to other vasculitides, presenting with non-specific clinical symptoms or signs of specific organ involvement, making the diagnosis difficult (1). The beginning of the disease is usually mild with nonspecific clinical presentation, but can progress suddenly, with severe complications (2). The laboratory findings play a relatively small role in the diagnostics but are helpful in monitoring organ function and disease activity (1).

The first step in improving disease management was introduced in 2008 with the new classification of vasculitides in children, including PAN, which has been modified from the previous adult Chapel Hill classification (3).

It has also become clear that multicentre studies of this rare vasculitis should be conducted to detail treatment responses and prognosis in children (1,5). For this reason a pan-European study of the new treatment options in paediatric PAN with MMF has been designed and is currently in progress (5). The treatment, which is also based on adult studies, requires introduction of corticosteroids and immunosuppressive agents, mostly cyclophosphamide (4). This particular combination was used as first line therapy in 83% of subjects in the largest published cohort of paediatric PAN patients, with considerable number of adverse events such as neutropenia and sepsis (2).

Further progress in improvement of disease treatment involved introduction of the follow-up protocols, like the new PVAS (7), which is based on the Birmingham Vasculitis Activity Score. In the future, paediatric disease outcome measures as well as protocol for follow-up investigations will be needed (1,6).

The patient described in this case report was admitted to the hospital because of prolonged fever with elevated SR. Hypertension was subsequently diagnosed and further evaluation was performed according to the established guidelines. Possibility of renovascular hypertension was investigated using Doppler and MRA scans of the renal arteries and revealed a negative result. Several options are available for demonstrating renal involvement in PAN, including less invasive techniques. MRA usually fails to detect microaneurysms and overestimates stenotic lesions. CT angi-

ography performs similarly, at the expense of high-ionising radiation exposure (3,8). According to the diagnostic criteria in case of a possibility of PAN, conventional arteriography has to be performed because MRA results are often negative (3), which was the case in this patient. Renal biopsy was performed because of a sudden elevation of creatinine, active urine sediment, and nephrotic range proteinuria. It was later determined that this pathology was a secondary event. Most experts advocate performing renal biopsy only in patients with negative arteriography results. This assay may fail to detect pathognomonic changes due to sampling error (3,8). In addition, the presence of small aneurysms increases the risk of bleeding or fistulae formation (3,8). If central nervous system vasculitis is suspected, MRA is a reasonable initial modality. In cases of abnormal parenchymal MR and normal MRA, conventional arteriography should be considered (9). The MRA of cerebral vessels was performed in this patient and did not show any specific pathology. As she remained asymptomatic, further diagnosis was not determined until a later date.

Despite normalisation of the patient's clinical status, decrease of SR, and considerable decrease of the disease activity score after PTA and antihypertensive medications, active disease was still present as PVAS was 8/63 and SR was in the range of 25 mm, necessitating immunosuppressive treatment. It was decided to administer MMF because it produced fewer side effects and due to the promising preliminary results of the MYPAN study, which indicated that the disease remission rate in paediatric patients using this medication for 6 months compared to cyclophosphamide has not been statistically significantly different and was found to be 71% (5). It was also decided to introduce antiplatelet therapy with acetylsalicylic acid, although only low-quality evidence for this treatment has been described to date (10).

The patient follow-up also caused further concern. It became clear that there is a lack of a reliable disease activity assessment tool, although new disease activity scores have been developed recently (7). It was decided to perform regular patient follow-ups, monitoring laboratory results and PVAS. A plan for repeated morphological investigation was also prepared. Inactive disease is defined as PVAS=0, with normal in-

flammatory markers or inactive disease present upon imaging. According to the FSGS, some definitive renal damage is to be expected with persistent amount of proteinuria, which has to be taken into consideration. Follow-up is also needed because life-threatening complications can occur as a first manifestation or as a consequence of immunosuppressive therapy or poorly controlled disease (6,7).

PAN in children is a rare and serious disease. In recent years, progress in diagnostics, treatment, and follow-up has been made and is still ongoing, with the aim of creating an optimal management plan for the patients. The patient in this case report was managed according to presented guidelines and will need lifelong monitoring and follow-up.

## REFERENCES

1. Eleftheriou D, Brogan PA. Therapeutic advances in the treatment of vasculitis. *Pediatr Rheumatol Online J* 2016; 14: 26.
2. Eleftheriou D, Dillon MJ, Tullus K, Marks SD, Pilkington CA, Roebuck DJ et al. Systemic polyarteritis nodosa in the young: a single-center experience over thirty-two years. *Arthritis Rheum* 2013; 65: 2476-85.
3. Ozen S, Pisotiro A, Iusan SM, Bakkaloglu A, Herlin T, Brik R et al. Paediatric Rheumatology International Trials Organisation (PRINTO). The EULAR/PRINTO/PRES criteria for Henoch-Schönlein purpura, childhood polyarteritis nodosa, childhood Wegener granulomatosis and childhood Takayasu arteritis: Ankara 2008. Part II. Final classification criteria. *Ann Rheum Dis* 2010; 69: 798-806.
4. Guillevin L, Cohen P, Mahr A, Arene JP, Mouthon L, Puéchal X et al. Treatment of polyarteritis nodosa and microscopic polyangiitis with poor prognosis factors: a prospective trial comparing glucocorticoids and six or twelve cyclophosphamide pulses in sixty-five patients. *Arthritis Rheum* 2003; 49: 93-100.
5. Hampson LV, Whitehead J, Eleftheriou D, Tudur-Smith C, Jones R, Jayne D et al. Elicitation of expert prior opinion: application to the MYPAN trial in childhood polyarteritis nodosa. *PLoS One* 2015; 10: e0120981.
6. Ludici M, Puéchal X, Pagnoux C, Quartier P, Agard C, Aouba A et al. Brief report: childhood-onset systemic necrotizing vasculitides: long-term data from the French Vasculitis Study Group Registry. *Arthritis Rheumatol* 2015; 67: 1959-65.
7. Dolezalova P, Price-Kuehne FE, Özen S, Benseler SM, Cabral DA, Anton J et al. Disease activity assessment in childhood vasculitis: development and preliminary validation of the Paediatric Vasculitis Activity Score (PVAS). *Ann Rheum Dis* 2013; 72: 628-33.
8. Ozen S, Anton J, Arisoy N, Bakkaloglu A, Besbas N, Brogan P et al. Juvenile polyarteritis: results of a multicenter survey of 110 children. *J Pediatr* 2004; 145: 517-22.
9. Eleftheriou D, Cox T, Saunders D, Klein NJ, Brogan PA, Ganesan V. Investigation of childhood central nervous system vasculitis: magnetic resonance angiography versus catheter cerebral angiography. *Dev Med Child Neurol* 2010; 52: 863-7.
10. Emmi G, Silvestri E, Squatrito D, Amedei A, Nicolai E, D'Elia MM et al. Thrombosis in vasculitis: from pathogenesis to treatment. *Thromb J* 2015; 13: 15.