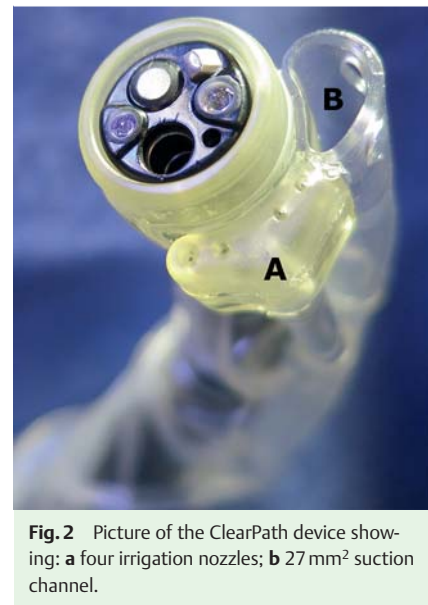
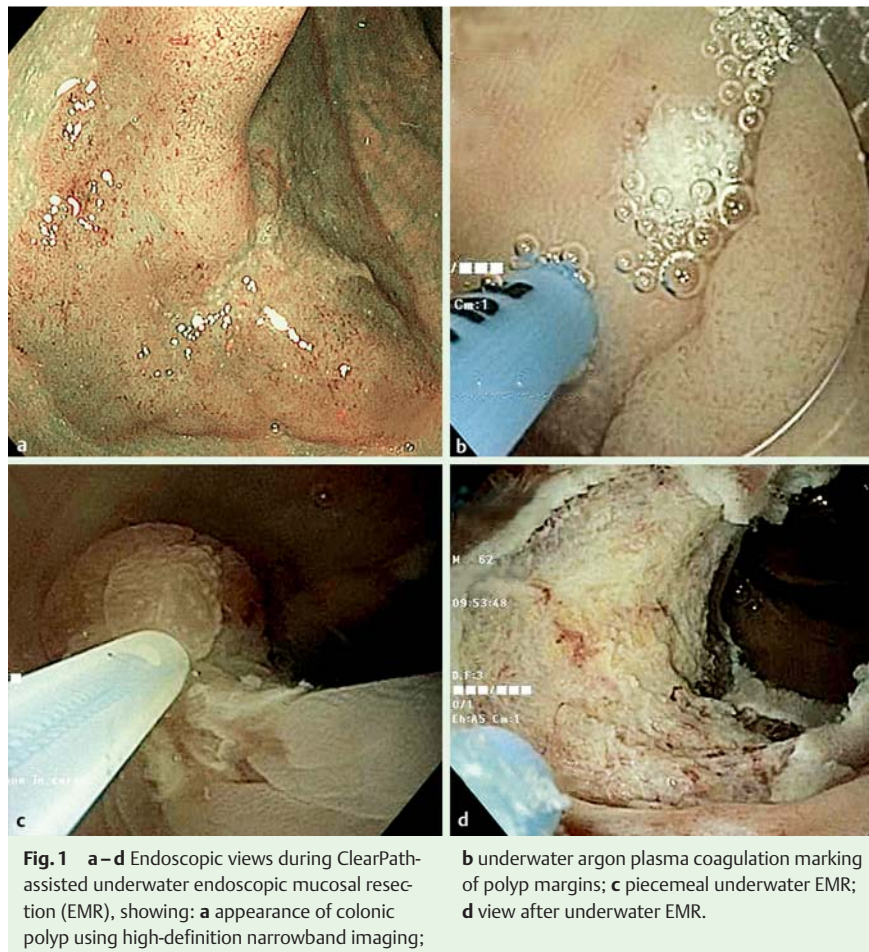

ClearPath-assisted underwater endoscopic mucosal resection of a laterally spreading tumor of the colon



blood clots during upper gastrointestinal bleeding and has also been shown to be useful and safe for cleaning of poorly prepared porcine colon [2]. ClearPath-assisted underwater EMR allowed complete endoscopic resection while reducing procedure time due to fast colonic irrigation/aspiration and rapid polyp fragment retrieval. Although its efficacy cannot be fully demonstrated by a single report, this application of ClearPath appears useful and safe and may stimulate the development and manufacture of new, dedicated devices for UEMR.

Endoscopy_UCTN_Code_TTT_1AQ_2AD

Competing interests: None

Gabriele Curcio, Antonino Granata, Neville Azzopardi, Patrizia Sanna, Luca Barresi, Ilaria Tarantino, Mario Traina

Gastroenterology and Endoscopy Unit, Mediterranean Institute for Transplantation and Advanced Specialized Therapies (ISMETT), Palermo, Italy

A 50-year-old gentleman with a 4 cm laterally spreading tumor of the sigmoid colon was referred to our institute for endoscopic resection. Biopsy of this lesion confirmed the presence of an adenomatous polyp with high-grade dysplasia. Based on the size and histology of the polyp, and in view of its location in the sigmoid colon, we opted to carry out underwater endoscopic mucosal resection (UEMR) [1]. This procedure was carried out with a high-definition narrowband endoscope (GIF-H190; Olympus Medical, Center Valley, PA, USA) equipped with a ClearPath cleaning device (Easy-Glide Ltd., Kfar Truman, Israel) to facilitate water irrigation and aspiration during the procedure. With the help of the ClearPath, the colon was rapidly irrigated with

water, allowing piecemeal UEMR. All the polyp fragments, regardless of size, were aspirated through the ClearPath suction channel (▶ Fig. 1, ▶ Fig. 2). The patient tolerated the procedure well with no adverse events recorded in the following days. UEMR of large sessile colorectal polyps without submucosal injection was described by Binmoeller et al. in 2012 [1]. In their experience, 60 consecutive patients with large sessile colorectal polyps undergoing UEMR had successful complete resection and no early complications. The ClearPath device has been developed for rapid luminal irrigation with high flow rates and efficient aspiration through its large suction channel (▶ Fig. 2). This may allow evacuation of fluids, bile, and

References

- 1 *Binmoeller KF, Weilert F, Shah J* et al. "Underwater" EMR without submucosal injection for large sessile colorectal polyps (with video). *Gastrointest Endosc* 2012; 75: 1086–1091
- 2 *Moshkowitz M, Hirsch Y, Carmel I* et al. A novel device for rapid cleaning of poorly prepared colons. *Endoscopy* 2010; 42: 834–836

Bibliography

DOI <http://dx.doi.org/10.1055/s-0033-1359127>
Endoscopy 2014; 46: E40–E41
© Georg Thieme Verlag KG
Stuttgart · New York
ISSN 0013-726X

Corresponding author

Gabriele Curcio, MD
Gastroenterology and Endoscopy Unit
ISMETT, UPMC
Via Tricomi 1
Palermo 90127
Italy
Fax: +39-091-2192400
gcurcio@ismett.edu