

SHORT COMMUNICATION

# Optical coherence tomography findings in a case of acute multifocal posterior placoid pigment epitheliopathy (AMPPPE)

G. LOFOCO<sup>1</sup>, F. CIUCCI<sup>1</sup>, A. BARDOCCI<sup>1</sup>, P. QUERCIOLI<sup>1</sup>, R.D. STEIGERWALT Jr.<sup>2</sup>, C. DE GAETANO<sup>1</sup>

<sup>1</sup>S. Pietro Fatebenefratelli Hospital, Roma

<sup>2</sup>ARS Medical Clinical, Roma - Italy

**PURPOSE.** To report the optical coherence tomography (OCT) findings in a case of acute multifocal posterior placoid pigment epitheliopathy (AMPPPE).

**Design.** Case report.

**METHODS.** A 26-year-old woman was seen for a mild loss of visual acuity in both eyes. The fundus examination revealed yellow-white placoid lesions in the posterior pole suggesting AMPPPE. Fluorescein and indocyanine green (ICG) angiography and optical coherence tomography (OCT) were performed 2 days, 9 days, and 1 month after the first examination.

**RESULTS.** In the acute phases the OCT revealed a mild hyperreflective area above the retinal pigmented epithelium (RPE) in the photoreceptor layer. In the later phases the OCT scan revealed a nodular hyperreflective lesion on the plane of the RPE with mild underlying backscattering.

**CONCLUSIONS.** In AMPPPE, the OCT demonstrates hyperreflective lesions that may indicate inflammatory tissue and inflammatory cells or the presence of ischemic edema in the outer retinal layers. (*Eur J Ophthalmol* 2005; 15: 143-7)

**KEY WORDS.** Acute multifocal posterior placoid pigment epitheliopathy, AMPPPE, Optical coherence tomography, OCT

Accepted: September 27, 2004

## INTRODUCTION

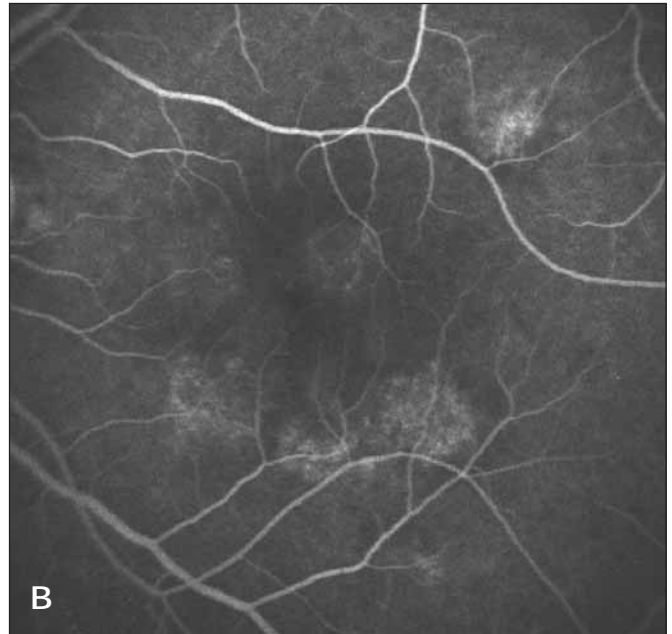
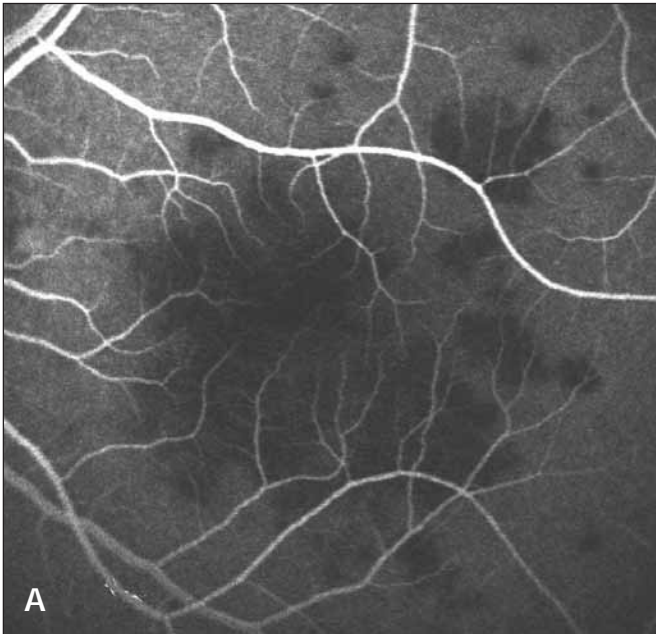
Acute multifocal posterior placoid pigment epitheliopathy (AMPPPE) is a disease of young adults characterized by multifocal yellow-white placoid lesions in the posterior pole and midperipheral fundus, which usually follows a viral illness with an acute visual acuity loss in both eyes. The appearance of new lesions and the simultaneous resolution of older lesions can continue for a few months in the course of the disease, leading to a rapid decline in vision which is usually followed, in the final phase of the disease, by a recovery to 20/25 or better (1, 2). AMPPPE has been

viewed as a form of delayed hypersensitivity to various antigenic stimuli, as demonstrated by the frequent association of this disease with various systemic pathologies (1, 2).

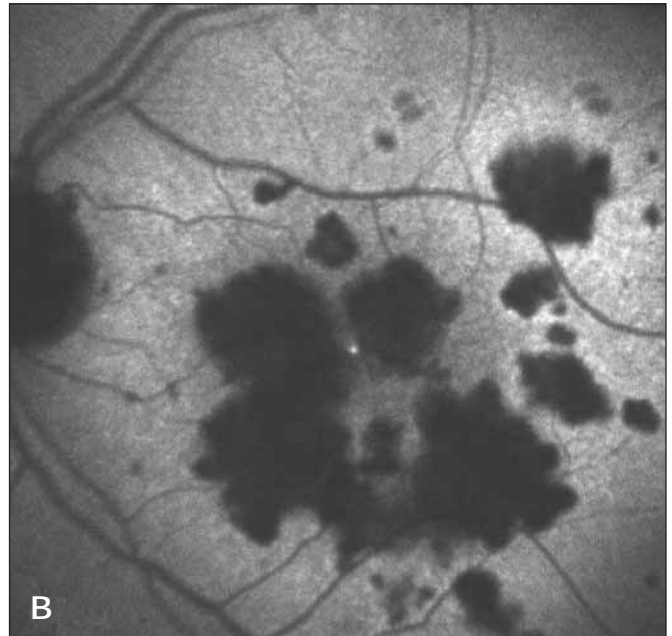
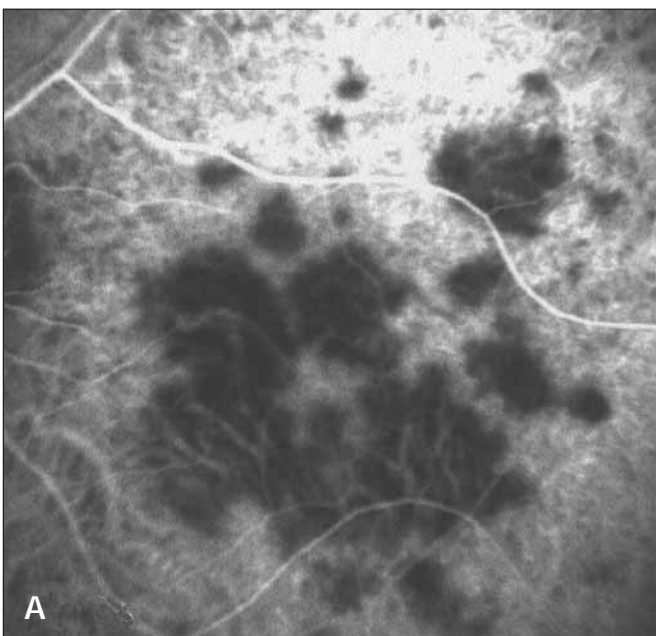
To our knowledge, this is the first report of optical coherence tomography (OCT) findings in AMPPPE.

## Case report

A 26-year-old woman was seen for a sudden bilateral mild visual loss after a severe viral illness. Her best-corrected visual acuity was 20/25 in the right eye and 20/32 in the left eye. Fundus examination re-



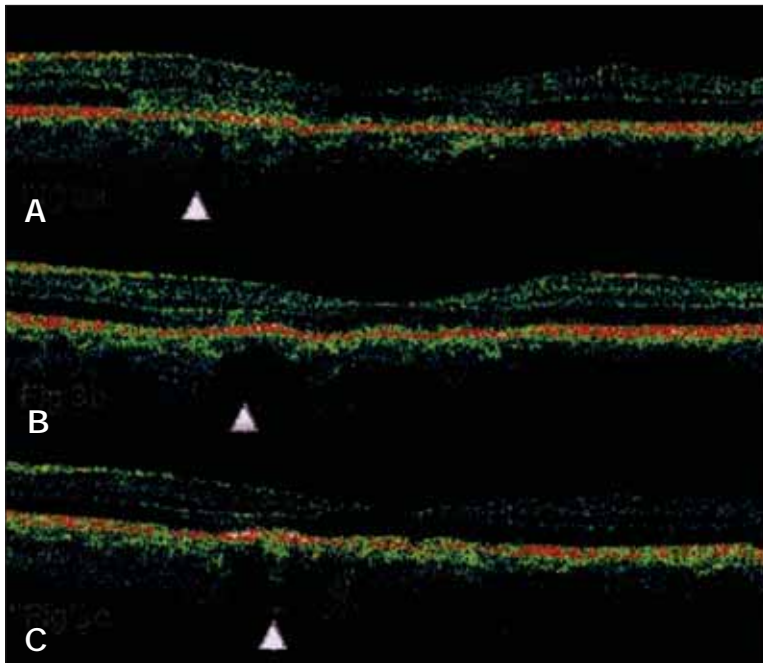
**Fig. 1** - Left eye: Fluorescein angiography revealed early hypofluorescence (A) and staining in the later phases (B). Similar findings were detected in the right eye.



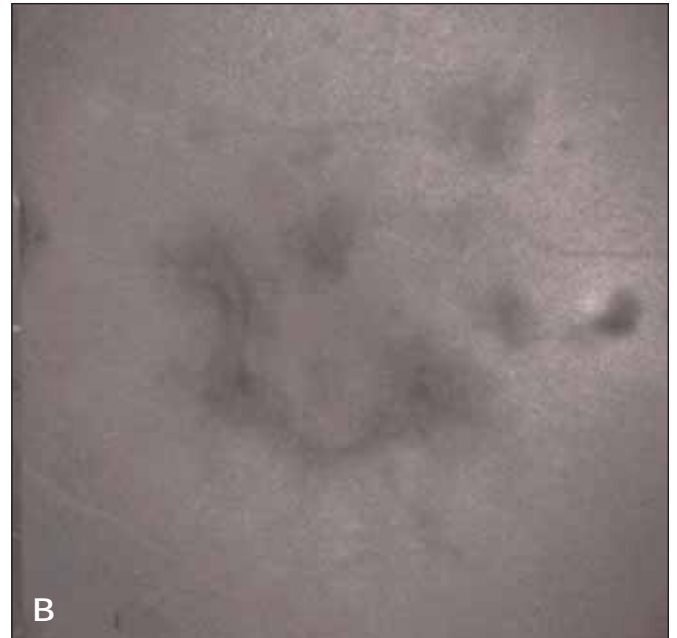
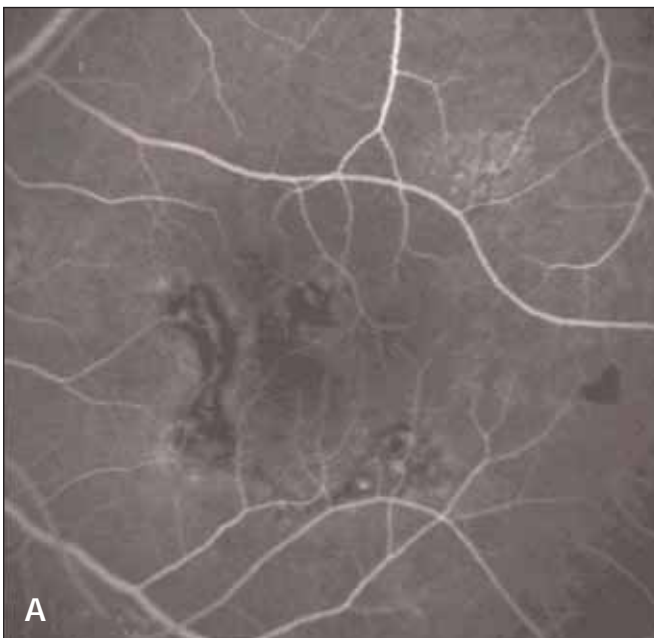
**Fig. 2** - Left eye: ICG angiography revealed early hypofluorescence (A) more clearly delineated in the late phases of the examination (B). Similar findings were detected in the right eye.

vealed multifocal yellow-white flat placoid lesions at the posterior pole consistent with AMPPPE. Fluorescein angiography revealed early hypofluorescence of the lesions followed by hyperfluorescence and staining in the later phases, the left eye being more af-

ected (Fig. 1, A and B). Indocyanine green (ICG) angiography revealed early hypofluorescence more clearly delineated in the late phases of the examination (Fig. 2, A and B). A horizontal OCT 3 scan of a placoid lesion showed a mild hyperreflective area above



**Fig. 3** -Left eye: (A) In the acute phase horizontal OCT 3 scan of a placoid lesion showed a mild hyperreflective area above the RPE in the photoreceptor layer. (B) Nine days later the OCT 3 scan revealed a reduction in the previous hyperreflective area with a corresponding increase in the underlying RPE. (C) After one month the OCT 3 scan revealed a nodular hyperreflective lesion on the plane of the pigmented retinal epithelium with mild underlying back scattering. Similar findings were detected in the right eye.



**Fig. 4** - Left eye: After one month fluorescein angiography revealed windows and masking defects (A). On the ICG the lesions appeared still hypofluorescent although to a lesser degree (B). Similar finding were detected in the right eye.

the retinal pigmented epithelium (RPE) in the photoreceptor layer (Fig. 3A). Systemic prednisolone therapy was administered. Nine days later her visual acuity improved to 20/20 in the right eye and 20/25 in the left eye. At that time the OCT 3 scan revealed a reduction in the

previous hyperreflective area with a corresponding increase in the underlying RPE thickness (Fig. 3B).

After 1 month her visual acuity had returned to 20/20 in both eyes. Prednisolone therapy was gradually reduced. Fundus examination showed atrophic areas,

mottling, and hyperpigmentation of the RPE corresponding to the windows and masking defects revealed by fluorescein angiography (Fig. 4A). On the ICG the lesions still appeared hypofluorescent although to a lesser degree (Fig. 4B). The OCT 3 scan revealed a nodular hyperreflective lesion on the plane of the RPE with mild underlying backscattering (Fig. 3C).

## DISCUSSION

AMPPPE seems to be a focal choroidal vasculopathy secondary to a form of delayed hypersensitivity (3). The mechanism underlying the hypofluorescence seen on fluorescein angiography and its correlation with the above-mentioned hypersensitivity remains a matter for discussion.

The hypofluorescence seen by fluorescein and ICG angiography could be due to a blockage caused by inflamed tissue and inflammatory cells or to a blockage from the cloudy cytoplasm of the RPE cells as reported by Gass et al (1, 2). Supporting this theory are the rapid recovery of visual acuity, the variability in the size and shape of the lesions, and the failure of the lesions to stain with fluorescein from the periphery towards the center in the acute phases (2). On the other hand, this theory seems to be incompatible with the persistent hypofluorescence as seen with ICG, months and years after the active phases of the disease (4). Several studies suggest that the choroidal hypofluorescence seen on angiography in AMPPPE could be secondary to an obstructive vasculitis of the choroidal arterioles, resulting in choroidal nonperfusion (5). Support for this theory comes from experimental choroidal vascular occlusion studies carried

out on animals (6, 7), from the great number of systemic and ocular vascular diseases occasionally present in patients with AMPPPE, and from a postmortem report of thrombo-obliterative vasculitis in a patient with AMPPPE (8-16). Currently, research and clinical findings indicate a partial choroidal vascular occlusion as the underlying cause of AMPPPE (17).

An alternative theory might be that choroidal vascular occlusion and blockage of choroidal fluorescence by inflamed tissue and inflammatory cells could together result in the insurgence of the lesions typical of AMPPPE (17).

The OCT findings of hyperreflective lesions corresponding to the lesions seen on fluorescein and ICG angiography could support this last theory, and may indicate the presence of inflammatory tissue and cells at the level of the lesions as stated by Gass (1, 2). On the other hand, the same clinical pattern could indicate the presence of ischemia of the outer retinal layers as reported by several studies (5-17); the OCT reports of retinal artery occlusions, in which histopathologic studies clearly indicate intracellular edema and ischemia, show highly reflective areas corresponding to the ischemic lesions. This finding probably depends on the fact that edema occurs in the intracellular and not in the extracellular space. Such a type of ischemic edema corresponds to an increased thickness and enhanced reflectivity instead of the hyporeflexivity seen in extracellular edema (18).

Reprint requests to:  
Francesco Ciucci, MD  
Via della Farnesina 32  
00194 Roma, Italy  
f.ciucci@tele2.it

---

## REFERENCES

1. Gass JDM. Acute posterior multifocal placoid pigment epitheliopathy. *Arch Ophthalmol* 1968; 80: 177-85.
2. Gass JDM. Acute posterior multifocal placoid pigment epitheliopathy. In: Gass JDM, ed. *Stereoscopic Atlas of Macular Diseases*. Washington, DC: CV Mosby; 1987: 504-9.
3. Park D, Schatz H, McDonald HR, Johnson RN. Acute multifocal posterior placoid pigment epitheliopathy: a theory of pathogenesis. *Retina* 1995; 15: 351-2.
4. Schatz H, Park D, McDonald R. Acute multifocal posterior placoid pigment epitheliopathy. In: Yannuzzi LA, Flower RW, Slakter JS, eds. *Indocyanine Green Angiography*. St. Louis: Mosby; 1997: 239-46.
5. Deutman AF, Lion F. Choriocapillaris nonperfusion in acute posterior multifocal placoid pigment epitheliopathy. *Am J Ophthalmol* 1977; 84: 652-7.
6. Young NJA, Bird AC, Selurd K. Pigment epithelial diseases with abnormal choroidal perfusion. *Am J Ophthalmol* 1980; 90: 607-18.
7. Hayreh SS, Baines JAB. Occlusion of the posterior cil-

- iary artery: R. chorio-retinal lesions. *Br J Ophthalmol* 1972; 56: 736-53.
8. Gass JDM. Acute posterior multifocal placoid pigment epitheliopathy: a long-term follow-up study. In: Fine SL, Owens SL, eds. *Management of Retinal Vascular and Macular Disorders*. Baltimore: Williams & Wilkins; 1983: 176-81.
  9. Holt WS, Regan CD, Trempe C. Acute posterior multifocal placoid pigment epitheliopathy. *Am J Ophthalmol* 1976; 81: 403-12.
  10. Kirkham TH, Ffytche TJ, Sanders MD. Placoid pigment epitheliopathy with renal vasculitis and papillitis. *Br J Ophthalmol* 1972; 56: 875-80.
  11. Damato BE, Nanjiani M, Foulds WS. Acute posterior multifocal placoid pigment epitheliopathy. *Trans Ophthalmol Soc UK* 1989; 103: 517-22.
  12. Isashiki M, Koide H, Yamashita T, et al. Acute posterior multifocal placoid pigment epitheliopathy associated with diffuse retinal vasculitis and late haemorrhagic macular detachment. *Br J Ophthalmol* 1986; 70: 255-9.
  13. Deutman AR. Acute multifocal ischemic choroidopathy and the choriocapillaris. *Int Ophthalmol* 1983; 6: 155-60.
  14. Seigelman J, Behren M, Hilal S. Acute posterior multifocal placoid pigment epitheliopathy associated with cerebral vasculitis and homonymous hemianopsia. *Am J Ophthalmol* 1979; 88: 919-24.
  15. Hammer ME, Grizzard WS, Travies D. Death associated with acute multifocal placoid pigment epitheliopathy. *Arch Ophthalmol* 1989; 107: 170-1.
  16. Wilson CA, Choromokos EA, Sheppard R. Acute posterior multifocal placoid pigment epitheliopathy and cerebral vasculitis. *Arch Ophthalmol* 1988; 106: 796-800.
  17. Park DW, Schatz H, McDonald HR, Johnson RN. Acute posterior multifocal placoid pigment epitheliopathy. In Guyer R, Yannuzzi LA, Chang S, Shields JA, Green RW, eds. *Retinal Vitreous Macula, Italian edition*. Verduci Editore; 2000: 475-88.
  18. Cruz-Villegas V, Puliafito CA, Fujimoto JG. Retinal vascular diseases. In: Schuman JS, Puliafito CA, Fujimoto JG. *Optical Coherence Tomography of Ocular Diseases*. Thorofare, NJ: Slack Incorporated; 2004: 103-54.