

# Evaluation of Coronary Atherosclerosis by Multislice Computed Tomography in Patients With Acute Myocardial Infarction and Without Significant Coronary Artery Stenosis

## A Comparative Study With Quantitative Coronary Angiography

Annachiara Aldrovandi, MD; Filippo Cademartiri, MD, PhD; Alberto Menozzi, MD; Fabrizio Ugo, MD; Daniela Lina, MD; Erica Maffei, MD; Alessandro Palumbo, MD; Michele Fusaro, MD; Girolamo Crisi, MD; Diego Ardissino, MD

**Background**—It is known that 9% to 31% of women and 4% to 14% of men with acute myocardial infarction have normal coronary arteries or nonsignificant coronary disease at angiography. These patients represent a diagnostic and therapeutic challenge. Multislice computed tomography (CT) can noninvasively identify the presence of coronary plaques even in the absence of significant coronary artery stenosis. This study evaluated the role of 64-slice CT, in comparison with coronary angiography, in detecting and characterizing coronary atherosclerosis in patients with acute myocardial infarction without significant coronary artery stenosis.

**Methods and Results**—Thirty consecutive patients with acute myocardial infarction but without significant coronary stenosis at coronary angiography underwent 64-slice CT. All coronary segments were quantitatively analyzed by means of coronary angiography (CA-QCA) and 64-slice CT (CT-QCA). Forty-seven (10.4%) of the 450 coronary segments were not evaluable by CT. The mean proximal reference diameters at CT-QCA and CA-QCA were, respectively,  $2.88 \pm 0.75$  mm and  $2.65 \pm 0.9$  mm; the overall correlation between CT-QCA and CA-QCA for quantification of reference diameter was  $r_s = 0.77$ ;  $P < 0.001$ . The mean percent stenosis was  $14.4 \pm 8.0\%$  at CT-QCA and  $4.0 \pm 11.0\%$  at CA-QCA and the correlation was  $r_s = 0.11$ ;  $P = 0.03$ . Overall CT-QCA showed the presence of 50 plaques, of which only 11 were detected by CA-QCA. CT-QCA identified 25 plaques in infarct-related coronary arteries. Positive remodeling was present in 38 of the 50 plaques (76%), with a higher prevalence in the coronary plaques not visualized by CA-QCA (82.1% versus 54.5%).

**Conclusions**—CT-QCA correlates well with CA-QCA in terms of coronary reference diameter analysis, but not stenosis quantification. Multislice CT can detect coronary atherosclerotic plaques in segments of nonstenotic coronary arteries that are underestimated by CA and may have an incremental diagnostic value for the diagnosis of acute myocardial infarction in patients without significant coronary stenosis at CA. (*Circ Cardiovasc Imaging*. 2008;1:205-211.)

**Key Words:** angiography ■ coronary disease ■ imaging ■ myocardial infarction

Acute myocardial infarction (AMI) is attributable to coronary artery thrombosis, complicating an atherosclerotic coronary plaque usually in the presence of obstructive coronary artery disease. However, it is known that an AMI may occur even in patients without significant coronary artery stenosis at coronary angiography, because it may be due to the disruption of mildly stenotic “vulnerable” plaques, which are undetectable by conventional coronary angiography and may lead to thrombotic complications.<sup>1,2</sup> It has been reported that 9% to 31% of women and 4% to 14% of men with AMI have a normal coronary angiogram.<sup>3-6</sup> Coronary

angiography is the reference method for assessing coronary artery disease, but, intravascular ultrasound and pathological studies indicate that it underestimates the extent of coronary atherosclerosis, especially in case of mild disease.<sup>7,8</sup> Moreover, it is known that coronary angiography may not detect early stage atherosclerosis, because of the outward remodeling of atherosclerotic plaques.<sup>9</sup> Intravascular ultrasound, which is the current standard of reference for the assessment of coronary plaque volume and morphology, can only be used to study coronary lesions in the proximal segments of major vessels.<sup>10</sup>

Received April 22, 2008; accepted September 24, 2008.

From the Division of Cardiology (A.A., A.M., F.U., D.L., D.A.), Department of Heart and Lung, and Department of Radiology (F.C., E.M., A.P., M.F., G.C.), Azienda Ospedaliero-Universitaria di Parma, Italy.

Correspondence to Annachiara Aldrovandi, MD, Division of Cardiology, Department of Heart and Lung, Azienda Ospedaliero-Universitaria di Parma, 43100 Parma, Italy. E-mail aldrovandiac@yahoo.it

© 2008 American Heart Association, Inc.

*Circ Cardiovasc Imaging* is available at <http://circimaging.ahajournals.org>

DOI: 10.1161/CIRCIMAGING.108.786962

---

**Clinical Perspective see p 211**


---

Multislice computed tomography (MSCT) is an emerging technique that allows the noninvasive detection of coronary artery stenosis and atherosclerotic plaques. A number of studies have shown that MSCT can reliably quantify plaque volumes *in vivo* and identify the major morphological features of atherosclerotic lesions.<sup>11–13</sup>

The aim of this study was to evaluate the accuracy of quantitative 64-slice CT (CT-QCA) in identifying and quantifying atherosclerotic coronary lesions in comparison with quantitative coronary angiography (CA-QCA) in a population of patients with AMI without significant coronary artery stenosis.

## Methods

### Patient Selection

We evaluated 30 consecutive AMI patients with normal coronary arteries or nonsignificant coronary stenosis at coronary angiography. Myocardial infarction was defined as (1) typical chest pain lasting >20 minutes; (2) persistent electrocardiographic changes; and (3) increased cardiac enzymes (Troponin I >99 percentile and creatine kinase MB (CK MB) levels to more than twice the upper normal limit).

The study exclusion criteria were (1) the presence of any coronary stenosis causing a  $\geq 50\%$  reduction in lumen diameter, as evaluated by QCA; (2) a history of previous myocardial infarction or cardiomyopathy; (3) creatinine clearance <30 mL/min; and (4) an allergic reaction after contrast administration during coronary angiography. The localization of myocardial infarction was based on wall motion abnormalities detected by means of left ventriculography and transthoracic echocardiography. All of the patients gave their written informed consent to the study protocol, which was approved by the Institutional Review Board. The authors had full access to and take full responsibility for the integrity of the data. All authors have read and agree to the manuscript as written.

### Study Protocol

Patients with AMI without significant coronary artery stenosis at coronary angiography were asked to undergo 64-slice CT within 3 days of coronary angiography.

### Coronary Angiography and CA-QCA

Selective conventional coronary angiography was performed using standard techniques (Innova 2000 GE, General Electric). Standard multiple projections were recorded for left and right coronary arteries, and 0.2 mg intracoronary nitrates were administered before contrast injection for the projections used for QCA analysis. Left ventriculography was performed in the right oblique projection. The coronary angiograms were analyzed using an off-line computer-based software (MEDIS CMS version 6.0; MEDIS Imaging Systems) with an automatic edge-contour detection algorithm after standard and previously validated qualitative and quantitative parameters and definitions.<sup>14–16</sup> The angiograms were analyzed by an independent and experienced operator unaware of the results of MSCT. The automatic edge detection program determines the vessel contours by assessing brightness along scan lines perpendicular to the vessel center. To achieve the best filling with contrast medium of the arterial segment, an image was selected from the second or third cardiac cycle after contrast administration. The software was calibrated using the outer diameter of the contrast-filled catheter. CT-QCA measurements were performed in all coronary segments, according to the 15-segment American Heart Association classification.<sup>17</sup> For each coronary segment, an end-diastolic frame was selected in a perpendicular projection with minimal foreshortening and branch overlap. In the presence of a coronary lesion, the frame

that best showed the stenosis at its most severe degree was selected for analysis. The following parameters were calculated: (1) proximal and distal reference vessel diameter; (2) minimal lumen diameter; and (3) percent diameter stenosis, calculated as  $100(1 - \text{minimal lumen diameter/reference vessel diameter})$ .

### MSCT Data Acquisition

All of the MSCT examinations were performed using a 64-slice CT scanner (Sensation 64 Cardiac, Siemens). First, an unenhanced scan was made using standardized parameters: 64 (32 $\times$ 2) slices per rotation, 0.6-mm detector collimation, gantry rotation time 330 ms, table feed 3.84 mm/rotation, tube voltage 120 kV, tube current 150 mAs, and prospective X-ray tube modulation. This was followed by the CT angiographic acquisition using the following parameters: 64 (32 $\times$ 2) number of slices per rotation, 0.6-mm detector collimation, gantry rotation time 330 ms, effective temporal resolution 165 ms, spatial resolution 0.4 mm<sup>3</sup>, tube voltage 120 kV, tube current 900 mAs. Sublingual nitroglycerin 0.3 mg were administered to all patients before the examination. When heart rate was >65 bpm, intravenous  $\beta$ -blocker (atenolol 5 to 10 mg) was administered. Between 80 and 100 mL of nonionic contrast material (Iomeron 400, Bracco, Milan, Italy) were administered in the antecubital vein at a flow rate of 4 to 6 mL/s followed by a 50-mL saline chaser. A bolus tracking technique was used to synchronize the arrival of the contrast in the coronary arteries, and the scan was started once contrast attenuation in a preselected region of interest in the ascending aorta reached a predefined threshold of +100 Hounsfield Units (HU). All of the images were acquired during an inspiratory breath hold of approximately 10 to 12 seconds, with the simultaneous recording of the patient's ECG.

### MSCT Data Analysis

The CT data set were analyzed by 2 independent and experienced readers unaware of the CA-QCA using an off-line workstation software package (Leonardo, Siemens Medical Solutions). To obtain optimal image quality, data sets of the reconstructed coronary vessels were created at least at 2 points of the cardiac cycle using a retrospective ECG gating algorithm (1 diastolic cardiac phase usually at  $-350$  ms from the R waves and 1 end-systolic phase at  $+300$  ms). In the presence of motion artifacts, additional reconstructions were made at different time points of the R–R interval.

The analysis was performed using multiplanar reconstruction of the original axial images of the coronary arteries. As for in the case of QCA, all coronary segments were analyzed according to the American Heart Association classification. Each coronary segment was delimited by identifiable side-branches in both image modalities.

Any discernible structure that could be assigned to the coronary artery wall, which had a CT density less than the contrast-enhanced coronary lumen and greater than the surrounding epicardial fat tissue and could be identified in at least 2 independent planes, was considered as a noncalcified coronary atherosclerotic plaque. Any structure with a density of  $\geq 130$  HU that could be visualized separately from the contrast-enhanced coronary lumen (because it was "embedded" within a noncalcified plaque or because its density was above the contrast-enhanced lumen), which could be assigned to the coronary artery wall and identified in at least 2 independent planes, was considered a calcified atherosclerotic plaque.<sup>12</sup>

The display settings used for the lumen and plaque analysis were manipulated to achieve optimal separation between the vessel lumen, wall, and surrounding tissue.

For each coronary segment, a cross-sectional image was created perpendicular to the centerline of the vessel, and the vessel area at the proximal tract and 5 mm from the proximal point of measurement was calculated, with the corresponding diameters. The mean of the diameters was used as the reference vessel diameter for comparison with QCA. In the presence of coronary plaque, the vessel area at the plaque site, the plaque area, the minimum lumen diameter, and the percent stenosis were determined as was the remodeling index. Positive vessel remodeling was defined as a vessel area at plaque

**Table 1. Population Characteristics**

No of patients	30
Age (years±SD; range)	62±16 (37–85)
Male	9 (30%)
Female	21 (70%)
Risk factors	
Family history	10 (33%)
Hypertension	21 (70%)
Dyslipidemia	14 (46.6%)
Smoking	6 (20%)
Diabetes mellitus	1 (3%)
Obesity	3 (10%)
Clinical presentation	
NSTEMI	29 (96.6%)
STEMI	1 (3.4%)
Mean CK MB peak value, ng/mL	22.2±26.5
Mean Troponin I peak value, ng/mL	4.2±9.3
Location of AMI	
Anterior	14
Inferior	4
Lateral	2
Normal kinesis	10
Mean ejection fraction	55±8% (median 55%)

AMI indicates acute myocardial infarction; NSTEMI, non-ST elevation myocardial infarction; STEMI, ST elevation myocardial infarction.

site/reference vessel area ratio of >1.05. Plaque attenuation was measured and plaques were classified as calcified if HU >130, noncalcified if <130 HU, or mixed in the presence of areas with densities both >130 HU and <130 HU.

### Statistical Analysis

The quantitative data are presented as mean values±SD. Spearman correlation coefficient and Bland–Altman analysis were used to compare the vessel diameter measurements and the CT and CA quantifications of lesion severity and a probability value <0.01 was considered significant. The continuous variables were compared by means of the *t* test, and the categorical variables were compared by means of the  $\chi^2$  test. Statistical analysis was performed with SPSS version 12.0 (SPSS Inc).

### Results

Thirty patients were enrolled in the study and underwent MSCT after coronary angiography. Their clinical characteristics are shown in Table 1. MSCT was obtained 6.5±4.1 day after AMI and 4.6±3.8 days after coronary angiography. Forty-seven (10.4%) of the 450 coronary segments were not assessable by MSCT because of motion artifacts or small size (mean diameter, 1.25±0.50 mm); all of the nonassessable segments were distal coronary tracts or side branches (Table 2).

### Coronary Diameter Analysis

The mean proximal reference diameter was 2.65±0.90 mm at CA-QCA and 2.88±0.75 mm at CT-QCA. The overall correlation between the CT-QCA and CA-QCA for quantification of coronary diameters was  $r_s=0.77$ ;  $P<0.001$  (Figure

**Table 2. Distribution of Coronary Plaques at CT-QCA**

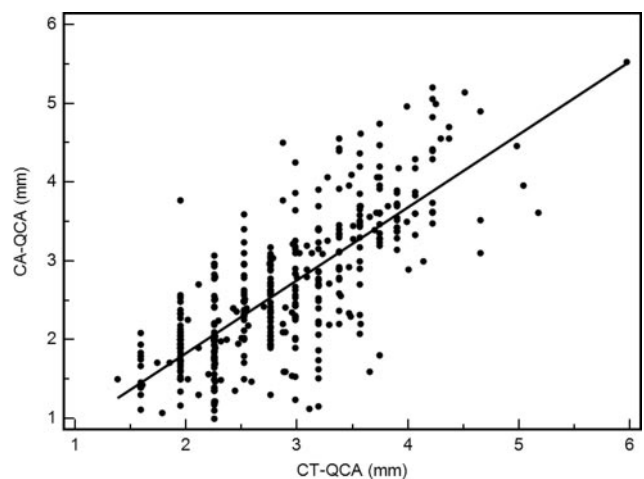
Segment	Name	Atherosclerotic Plaque Types				NA Segment
		Noncalcified	Mixed	Calcified	Total	
1	RCA prox	3	2	3	8	0
2	RCA m	2	1	0	3	0
3	RCA d	0	1	0	1	1
4	PDA	0	0	0	0	6
5	LM	1	1	2	4	0
6	LAD prox	9	5	3	17	0
7	LAD m	3	1	5	9	0
8	LAD d	0	0	0	0	0
9/10	D1/D2	0	0	0	0	21
11	CFX p	0	1	3	4	0
12	OM1	0	0	1	1	0
13	CFX m	1	0	1	2	0
14	OM2	0	0	1	1	13
15	CFX d	0	0	0	0	6
Total		19	12	19	50	47

NA indicates not assessable; CA-QCA, quantitative coronary angiography based on coronary angiography; CT-QCA, quantitative coronary angiography based on computed tomography; RCA, right coronary artery; PDA, posterior descending artery; LM, left main coronary artery; LAD, left anterior descending artery; D1/D2, first and second diagonal branches; CFX, circumflex coronary artery; OM1/2, obtuse marginal branches; prox, proximal tract; m, medium tract; d, distal tract.

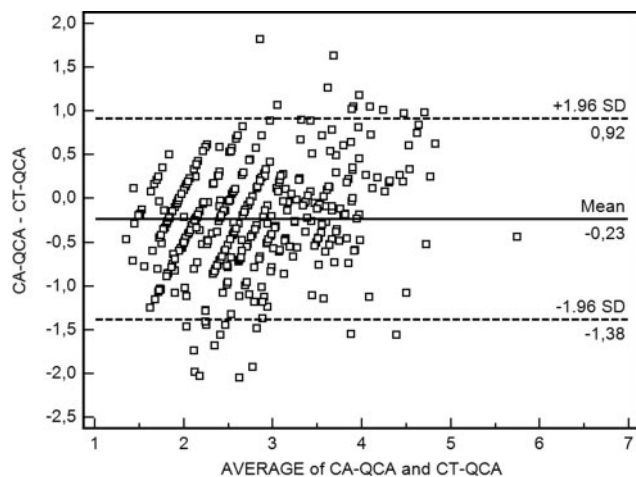
1). CT-QCA tended to overestimate coronary size, with a systematic error of +8.6% (Figure 2). The mean minimal lumen diameter was 2.24±0.87 mm at CA-QCA and 2.69±0.87 mm at CT-QCA ( $r_s=0.72$ ;  $P<0.001$ ).

### Coronary Stenosis Analysis

The mean percent stenosis was 14.4±8.0% at CA-QCA and 4.0±11.0% at CT-QCA ( $r_s=0.11$ ;  $P=0.03$ ). In the coronary segments with atherosclerotic plaques, the mean percent stenosis was 34.0±11% at CT-QCA and 16.8±9% at CA-QCA ( $r_s=0.11$ ;  $P=0.37$ ) (Figure 3). The mean plaque area at CT-QCA was 4.7±2.1 mm<sup>2</sup>. Mean Agatston coronary calcium score was 106.6±258.5 (range, 0 to 1325; median,



**Figure 1.** The correlation between CT-QCA and CA-QCA in terms of coronary reference diameter was  $r_s=0.77$ ;  $P<0.001$ .

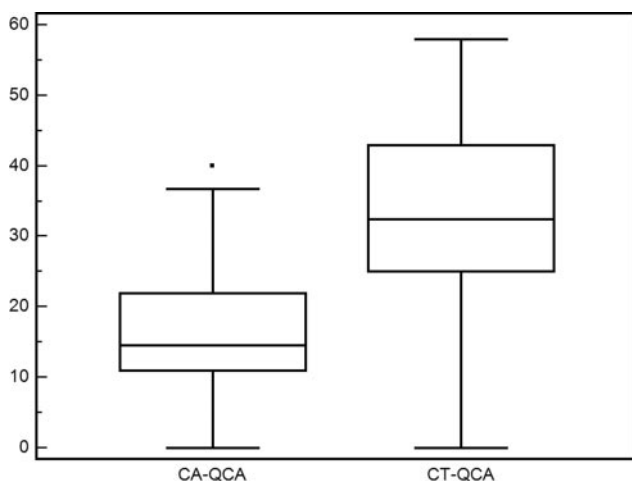


**Figure 2.** Bland-Altman analysis of CT-QCA versus CA-QCA demonstrated that CT-QCA slightly overestimated coronary reference diameter compared to CA-QCA (correlation coefficient  $r=0.28$ ;  $P<0.001$ ).

13.4). CT-QCA revealed the presence of 50 plaques (19 noncalcified, 12 mixed, and 19 calcified), of which only 11 were also detected by CA-QCA. In 4 patients, CT-QCA showed the complete absence of coronary plaques. The coronary plaque distribution is shown in Table 2. Positive remodeling was present in 38 lesions (76%; mean remodeling index,  $1.2\pm 0.3$ ). In particular, positive remodeling was present in as many as 32 of the 39 plaques (82.1%) identified by CT but not visualized by CA-QCA, and in only 6 of the 11 plaques identified also by CA-QCA (54.5%).

### Infarct-Related Artery Analysis

CT-QCA identified 25 plaques in infarct-related arteries in 19 patients, of which 17 were located in proximal segments and 8 in midsegments, whereas CA-QCA identified 8 plaques in infarct-related arteries, with 6 plaques in proximal segments and 2 in midsegments. Fourteen plaques in infarct-related arteries were noncalcified, 5 were mixed, and 6 were calcified; in noninfarct-related arteries, 14 plaques were calcified,



**Figure 3.** Comparison of stenosis quantification by CT-QCA and CA-QCA in coronary plaques identified by CT-QCA.

**Table 3. Characteristics of Infarct-Related Artery Plaques and Noninfarct-Related Artery Plaques**

	Infarct-Related Artery Plaques (n=25)	Noninfarct-Related Artery Plaques (n=25)	P Value
Noncalcified, %	14 (28%)	5 (10%)	
Mixed, %	5 (10%)	6 (12%)	0.02
Calcified, %	6 (12%)	14 (28%)	
Remodeling index	$1.20\pm 0.20$	$1.21\pm 0.19$	0.92
Mean % stenosis	$34\pm 9$	$32\pm 13$	0.49

5 were noncalcified, and 6 were mixed. The mean percent stenosis and remodeling index were not significantly different between infarct-related and noninfarct-related arteries plaques ( $1.20\pm 0.20$  versus  $1.21\pm 0.19$ ;  $P=0.92$ ; Table 3).

### Discussion

Our findings highlight the differences in evaluating coronary atherosclerosis between conventional coronary angiography and 64-slice CT. Although the 2 methods correlate well in terms of coronary diameter analysis, the correlation in detecting nonsignificant coronary artery stenosis is limited.

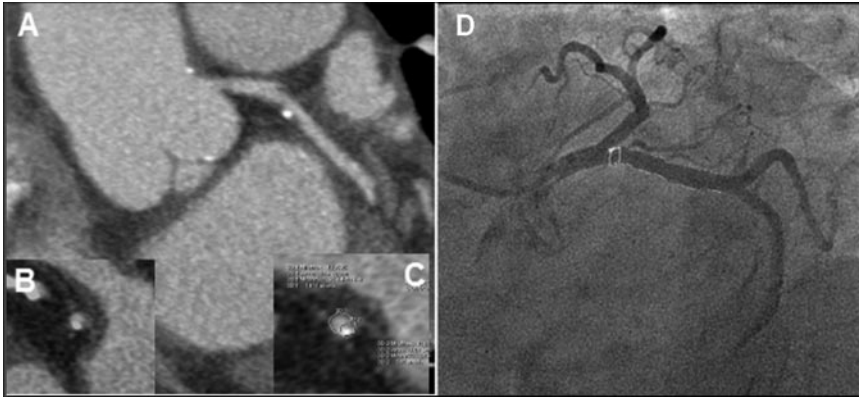We found that 64-slice CT, given its almost isotropic voxel resolution, can accurately measure and quantitatively analyze coronary arteries, showing a good correlation with CA-QCA ( $r_s=0.77$ ). Only a few studies have systematically compared the accuracy of measuring coronary artery lumen diameters by means of CT and CA.<sup>18,19</sup> A previous study by Cury et al<sup>19</sup> showed only a moderate correlation ( $r=0.48$ ) between 16-slice CT and QCA. The tendency of CT to overestimate coronary artery size is probably because of its more limited spatial resolution in comparison with CA, which does not allow an exact definition of outer vessel boundaries, and the use of image display settings focused on plaque detection.

In the case of nonsignificant coronary artery disease, there are substantial differences in coronary stenosis quantification between CT-QCA and CA-QCA. In our study, CT-QCA detected a significant number of coronary plaques that were not seen by CA-QCA and was capable of characterizing the composition of coronary plaques on the basis of their density, distinguishing between calcified and noncalcified plaques. Moreover, in segments with coronary plaques, mean percent stenosis calculated by CT-QCA was significantly higher in comparison to CA-QCA ( $34.0\pm 11.0\%$  versus  $16.8\pm 9.0\%$ ).

MSCT directly identifies coronary plaques, whereas conventional coronary angiography images the lumen contour of coronary vessels but does not provide any information concerning the vessel wall and plaque volume and may, therefore, underestimate the atherosclerotic burden and possible vulnerable plaques leading to AMI (Figures 4 and 5).

Intracoronary ultrasound is the "gold standard" for plaque detection and quantification of noncritically stenotic lesions, but it is invasive and time consuming and cannot be used extensively in all coronary arteries, but only in selected proximal coronary segments. Its clinical applicability is therefore usually limited to assessing a few coronary segments, whereas in the clinical setting of angiographically





**Figure 4.** Case of a 55-year-old patient with AMI, with a hypokinetic lateral wall, peak CK MB mass value of 55 ng/mL. A, Mixed atherosclerotic plaque at proximal left circumflex coronary artery detected by 64-slice CT. B, Cross-section of multiplanar reconstruction reconstruction at coronary plaque level: the calcified (898 HU) and the noncalcified components (78 HU) are well demarcated. C, Coronary vessel and plaque area measures. D, Coronary angiography showing normal CFX lumen.

normal coronary arteries, an extensive analysis is needed. MSCT has the advantage of allowing a noninvasive evaluation of the complete coronary artery tree.

Preliminary studies have also shown that CT can assess the morphology and composition of culprit lesions in patients with acute coronary syndrome,<sup>20,21</sup> which show a higher prevalence of noncalcified plaque and positive remodeling index.<sup>22,23</sup>

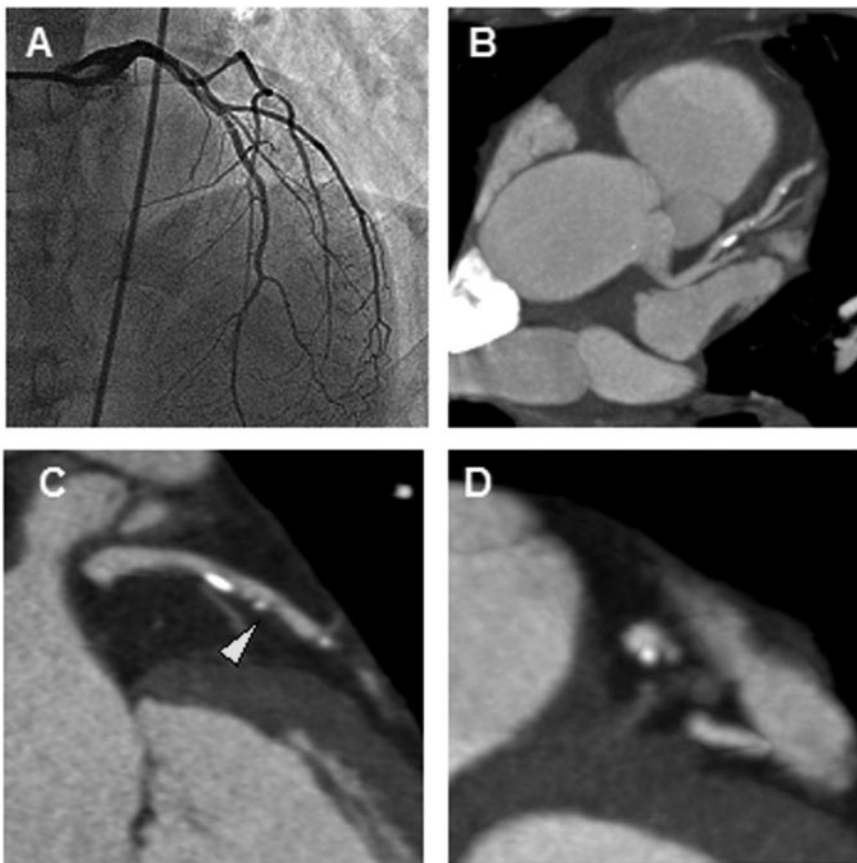
In our population of patients with AMI, CT-QCA revealed the presence of 25 plaques in infarct-related artery compared with only 8 plaques detected by CA-QCA; most of the coronary plaques in infarct-related arteries were noncalcified.

Moreover in our study, CT identified positive remodeling in a large number of plaques (76%), with a much higher

prevalence in the group of plaques detected only by CT-QCA (82.1% versus 54.5%). This finding confirms that coronary angiography identifies mainly negatively remodeled plaques, and it has limitations in the evaluation of positive remodeled coronary plaques.

In 4 patients, CT-QCA showed the complete absence of any coronary plaque; a different diagnosis may therefore be hypothesized in this subgroup, such as possible myocarditis or embolic myocardial infarction.

In patients with AMI, demonstrating the absence of significant coronary stenosis at coronary angiography may challenge the diagnosis. However, it is known that the prognosis of these patients is similar to that of patients with AMI and significant coronary disease. The use of



**Figure 5.** Coronary plaque characteristics in a 62-year-old woman with anterior AMI. A, CA-QCA of medium tract of left anterior descending artery (LAD). B, MIP reconstruction of LAD. C, Multiplanar reconstruction of LADm. D, Axial image at plaque level. CA-QCA showed a 14% stenosis in the first tract of LADm; CT-QCA showed multiple plaques, with a proximal calcified plaque (HU 789) corresponding to the stenosis detected by CA and a more distal mixed eccentric plaque (79 HU noncalcified component, 535 HU calcified spot), remodeling index=1.1, 28% stenosis (arrowhead).

CT-CA may confirm the diagnosis of myocardial infarction on an atherosclerotic basis and therefore may support the use of optimal antithrombotic therapy and secondary prevention therapy.

In 7 patients, it was not possible to define the infarct-related artery clearly, because of the absence of wall motion abnormalities. Left ventriculography and transthoracic echocardiogram are the most widely used techniques to evaluate the localization and extent of myocardial infarction, but they have a limited sensitivity in identifying small areas of necrosis. Cardiac magnetic resonance with gadolinium enhancement can detect areas of myocardial fibrosis and differentiate in vivo myocardial scarring because of ischemic etiology or myocarditis, and it may have an incremental role over standard imaging techniques in this setting. MSCT is an attractive noninvasive method for the analysis of coronary plaques, but it is limited by radiation exposure, which vary from 15 to 21 mSV<sup>24</sup> per examination, although the introduction of the prospective gating technique has the potential to reduce radiation exposure to 1.1 to 3.0 mSV.<sup>25</sup>

In conclusion, CT-CA may be a valuable noninvasive imaging method of assessing overall plaque burden and may complement coronary angiography in patients with AMI without significant coronary stenosis, although it is still limited in identifying culprit lesions in this population.

## Disclosures

None.

## References

- Mann JM, Davies MJ. Vulnerable plaque. Relation to degree of stenosis in human coronary arteries. *Circulation*. 1996;94:928–931.
- Libby P, Theroux P. Pathophysiology of coronary artery disease. *Circulation*. 2005;111:3481–3488.
- Zimmerman F, Cameron A, Fisher LD, Ng G. Myocardial infarction in young adults: angiographic characterization, risk factor and prognosis (CASS Registry). *J Am Coll Cardiol*. 1995;26:654–661.
- Bugiardini R, Bairez Merz GM. Angina with normal coronary arteries: a changing philosophy. *JAMA*. 2005;293:477–484.
- Bugiardini R, Manfrini O, De Ferrari GM. Unanswered questions for management of acute coronary syndrome: risk stratification of patients with minimal disease or normal findings on coronary angiography. *Arch Intern Med*. 2006;166:1391–1395.
- Germing A, Lindstaedt M, Ulrich S, Grewe P, Bojara W, Lawo T, von Dryander S, Jager D, Machraoui A, Mugge A, Lemke B. Normal Angiogram in acute coronary syndrome - preangiographic risk stratification, angiographic finding and follow-up. *Int J Card*. 2005;99:19–23.
- Alfonso F, Macaya C, Goicolea J, Iniguez A, Hernandez R, Zamorano J, Perez-Vizcayne MJ, Zarco P. Intravascular ultrasound imaging of angiographically normal coronary segments in patients with coronary artery disease. *Am Heart J*. 1994;127:536–544.
- Nissen SE, Gurley JC, Grines CL, Booth DC, McClure R, Berk M, Fischer C, DeMaria AN. Intravascular ultrasound assessment of lumen size and wall morphology in normal subjects and patients with coronary artery disease. *Circulation*. 1991;84:1087–1099.
- Glagov S, Weisenberg E, Zarins CK, Stankovic R, Kolettis GJ. Compensatory enlargement of human atherosclerotic coronary arteries. *N Engl J Med*. 1987;316:371–375.
- Mintz GS, Painter JA, Pichard AD, Kent KM, Satler LF, Popma JJ, Chuang YC, Bucher TA, Sokolowicz LE, Leon MB. Atherosclerosis in angiographically “normal” coronary artery reference segments: an intravascular ultrasound study with clinical correlations. *J Am Coll Cardiol*. 1995;25:1479–1485.
- Achenbach S, Moselewski F, Ropers D, Ferencik M, Hoffmann U, MacNeill B, Pohle K, Baum U, Anders K, Jang IK, Daniel WG, Brady TJ. Detection of calcified and noncalcified coronary atherosclerotic plaque by contrast-enhanced, submillimeter multidetector spiral computed tomography: a segment-based comparison with intravascular ultrasound. *Circulation*. 2004;109:14–17.
- Schroeder S, Kuettner A, Leitritz M, Janzen J, Kopp AF, Herdeg C, Heuschmid M, Burgstahler C, Baumbach A, Wehrmann M, Clausen CD. Reliability of differentiating human coronary plaque morphology using contrast-enhanced multislice spiral computed tomography: a comparison with histology. *J Comput Assist Tomogr*. 2004;28:449–454.
- Moselewski F, Ropers D, Pohle K, Hoffmann U, Ferencik M, Chan RC, Cury RC, Abbara S, Jang IK, Brady TJ, Daniel WG, Achenbach S. Comparison of measurement of cross-sectional coronary atherosclerotic plaque and vessel areas by 16-slice multidetector computed tomography versus intravascular ultrasound. *Am J Cardiol*. 2004;94:1294–1297.
- Kirkeide RL, Gould KL, Parsel L. Assessment of coronary stenoses by myocardial perfusion imaging during Pharmacologic Coronary Vasodilatation. Validation of Coronary flow reserve as a single integrated functional measure of stenosis severity reflecting all its geometric dimensions. *J Am Coll Cardiol*. 1986;7:103–113.
- Popma JJ, Lansky AJ, Yeh W, Kennard ED, Keller MB, Merritt AJ, DeFusco RA, Desai A, Pacera JH, Schnabel JF, Niedermeyer V, Baim DS, Detre KM. Reliability of the quantitative angiographic measurements in the New Approaches to Coronary Intervention (NACI) registry: a comparison of clinical site and repeated angiographic core laboratory readings. *Am J Cardiol*. 1997;80:19K–25K.
- Berry C, L'Allier PL, Gregoire J, Lesperance J, Levesque S, Ibrahim R, Tardif JC. Comparison of intravascular ultrasound and quantitative coronary angiography for the assessment of coronary artery disease progression. *Circulation*. 2007;115:1851–1857.
- Austen WG, Edwards JE, Frye RL, Gensini GG, Gott VL, Griffith LS, McGoon DC, Murphy ML, Roe BB. A reporting system on patients evaluated for coronary artery disease. Report of the Ad Hoc Committee for grading of Coronary Artery Disease, Council on Cardiovascular Surgery, American Heart Association. *Circulation*. 1975;51:5–40.
- Sinha AM, Mahnken AH, Borghans A, Kruger S, Koos R, Dedden K, Wildberger JE, Hoffmann R. Multidetector-row computed tomography vs. angiography and intravascular ultrasound for the evaluation of the diameter of proximal coronary arteries. *Int J Cardiol*. 2006;110:40–45.
- Cury RC, Ferencik M, Achenbach S, Pomerantsev E, Nieman K, Moselewski F, Abbara S, Jang IK, Brady TJ, Hoffmann U. Accuracy of 16-slice multi-detector CT to quantify the degree of coronary artery stenosis: assessment of cross-sectional and longitudinal vessel reconstructions. *Eur J Radiol*. 2006;57:345–350.
- Hoffmann U, Moselewski F, Nieman K, Jang I, Ferencik M, Rahman AM, Cury RC, Abbara S, Joneidi-Jafari H, Achenbach S, Brady TJ. Noninvasive assessment of plaque morphology and composition in culprit and stable lesions in acute coronary syndrome and stable lesions in stable angina by multidetector computed tomography. *J Am Coll Cardiol*. 2006;47:1655–1662.
- Leber AW, Knez A, White CW, Becker A, von Ziegler F, Muehling O, Becker C, Reiser M, Steinbeck G, Boekstegers P. Composition of coronary atherosclerotic plaques in patients with acute myocardial infarction and stable angina pectoris determined by contrast-enhanced multislice computed tomography. *Am J Cardiol*. 2003;91:714–718.
- Achenbach S, Ropers D, Hoffmann U, MacNeill B, Baum U, Pohle K, Brady T, Pomerantsev E, Ludwig J, Flachskampf FA, Wicky S, Jang I, Daniel WG. Assessment of coronary remodeling in stenotic and nonstenotic coronary atherosclerotic lesions by multidetector spiral computed tomography. *J Am Coll Cardiol*. 2004;43:842–847.
- Motoyama S, Kondo T, Sarai M, Sugiura A, Harigaya H, Sato T, Inoue K, Ohumura M, Ishii J, Anno H, Virmani R, Ozaki Y, Hishida H,

- Narula J. Multislice computed tomography characteristics of coronary lesions in acute coronary syndromes. *J Am Coll Cardiol.* 2007;50:319–326.
24. Mollet NR, Cademartiri F, van Mieghem CA, Runza G, McFadden EP, Baks T, Serruys PW, Krestin GP, de Feyter PJ. High resolution spiral computed tomography coronary angiography in patients referred for diagnostic conventional coronary angiography. *Circulation.* 2005;112:2318–2323.
25. Husmann L, Valenta I, Gaemperli O, Adda O, Treyer V, Wyss CA, Veit-Haibach P, Tatsugami F, von Schulthess GK, Kaufmann P. Feasibility of low-dose coronary CT angiography: first experience with prospective ECG-gating. *Eur Heart J.* 2008;29:153–154.

### CLINICAL PERSPECTIVE

Almost 15% of patients with acute myocardial infarction have normal or near normal coronary arteries at coronary angiography. The absence of significant coronary stenosis may challenge the diagnosis; however, coronary atherosclerosis may be present even in angiographically normal coronary arteries, because of outward remodeling of coronary arteries in the presence of mild atherosclerotic plaques not affecting the coronary lumen, and myocardial infarction may occur because of disruption of only mildly stenotic plaque. Multislice computed tomography is a new noninvasive imaging technique that allows detection of atherosclerotic coronary plaques. In our study, we demonstrate that in patients with myocardial infarction without significant coronary stenosis, multislice computed tomography may evaluate atherosclerotic burden and detect a significant number of coronary plaques not seen by coronary angiography. These findings may support the use of optimal antithrombotic and secondary prevention therapy to reduce the risk of future events.

**Evaluation of Coronary Atherosclerosis by Multislice Computed Tomography in Patients With Acute Myocardial Infarction and Without Significant Coronary Artery Stenosis: A Comparative Study With Quantitative Coronary Angiography**

Annachiara Aldrovandi, Filippo Cademartiri, Alberto Menozzi, Fabrizio Ugo, Daniela Lina, Erica Maffei, Alessandro Palumbo, Michele Fusaro, Girolamo Crisi and Diego Ardissino

*Circ Cardiovasc Imaging*. 2008;1:205-211

doi: 10.1161/CIRCIMAGING.108.786962

*Circulation: Cardiovascular Imaging* is published by the American Heart Association, 7272 Greenville Avenue, Dallas, TX 75231

Copyright © 2008 American Heart Association, Inc. All rights reserved.

Print ISSN: 1941-9651. Online ISSN: 1942-0080

The online version of this article, along with updated information and services, is located on the World Wide Web at:

<http://circimaging.ahajournals.org/content/1/3/205>

**Permissions:** Requests for permissions to reproduce figures, tables, or portions of articles originally published in *Circulation: Cardiovascular Imaging* can be obtained via RightsLink, a service of the Copyright Clearance Center, not the Editorial Office. Once the online version of the published article for which permission is being requested is located, click Request Permissions in the middle column of the Web page under Services. Further information about this process is available in the [Permissions and Rights Question and Answer](#) document.

**Reprints:** Information about reprints can be found online at:  
<http://www.lww.com/reprints>

**Subscriptions:** Information about subscribing to *Circulation: Cardiovascular Imaging* is online at:  
<http://circimaging.ahajournals.org/subscriptions/>