

Treatment of infected pancreatic pseudocysts using a novel, dedicated covered self-expandable metal stent (CSEMS) with an effective antimigration system

Endoscopic ultrasound (EUS)-guided treatment has become the preferred approach for managing pancreatic pseudocysts because it is associated with a lower morbidity rate compared with surgical and percutaneous approaches [1]. The disadvantages of the endoscopic approach are the need for multiple revisions because of obstruction of plastic stents, patient discomfort, and dislodgment of stents after placement of a nasocystic catheter. The most appropriate type of stent for drainage is currently a major area of interest. Covered self-expandable metal stents (CSEMSs) have recently been

used for drainage of pseudocysts [2–5]. Use of CSEMSs allows creation of a larger-diameter access fistula, an increase in the final success rate, and a reduction in the time for resolution, even in complicated cysts [3–5]. One problem with using a CSEMS is the risk of stent migration. A 53-year-old man was admitted because of an episode of necrotizing acute pancreatitis. He was febrile, and a computed tomography (CT) scan showed a large pseudocyst (20 cm) with solid debris, involving the head-body of the pancreas. Given the content and the large size, we planned to use a curvilinear

ear array echoendoscope (GF-UCT140; Olympus America Corp., Melville, New York, USA), a transgastric puncture with a 19-gauge needle (EUSN-19-T; Wilson-Cook Medical, Winston-Salem, North Carolina, USA) was made under EUS with Doppler guidance. A 0.035-inch wire (Jagwire, Microvasive Endoscopy, Boston Scientific, Natick, Massachusetts, USA) was positioned in the cavity, and a pre-cut was done to create a fistula. A new CSEMS (2 cm in length and 10 mm in diameter) with large flares (3 cm in diameter) at the extremities (Niti-S ComVi fully covered biliary stent, Taewoong Medical, Gyeonggi-do, Korea) was placed, with immediate drainage of pus (▶ Fig. 1, ▶ Fig. 2). The patient promptly recovered and no longer had fever. A CT scan after 10 days showed resolution of the pseudocyst. A gastroscopy conducted 3 months later showed that the CSEMS was correctly placed and patent. It was easily removed with a snare and the patient has not experienced any further problems.

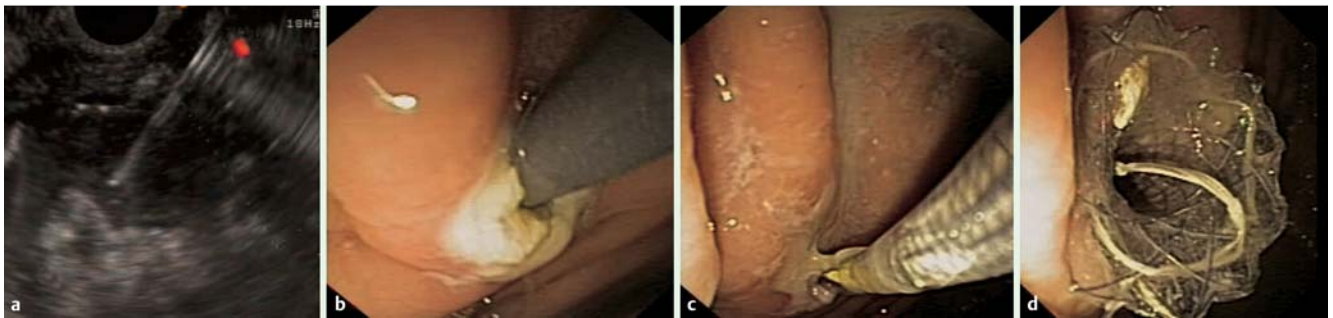

Fig. 1 a Endoscopic ultrasound-guided puncture in a 53-year-old man with a pancreatic pseudocyst. b Fistula created by pre-cut. c A covered self-expandable metal stent (CSEMS) on the guide wire. d The CSEMS observed from the stomach.

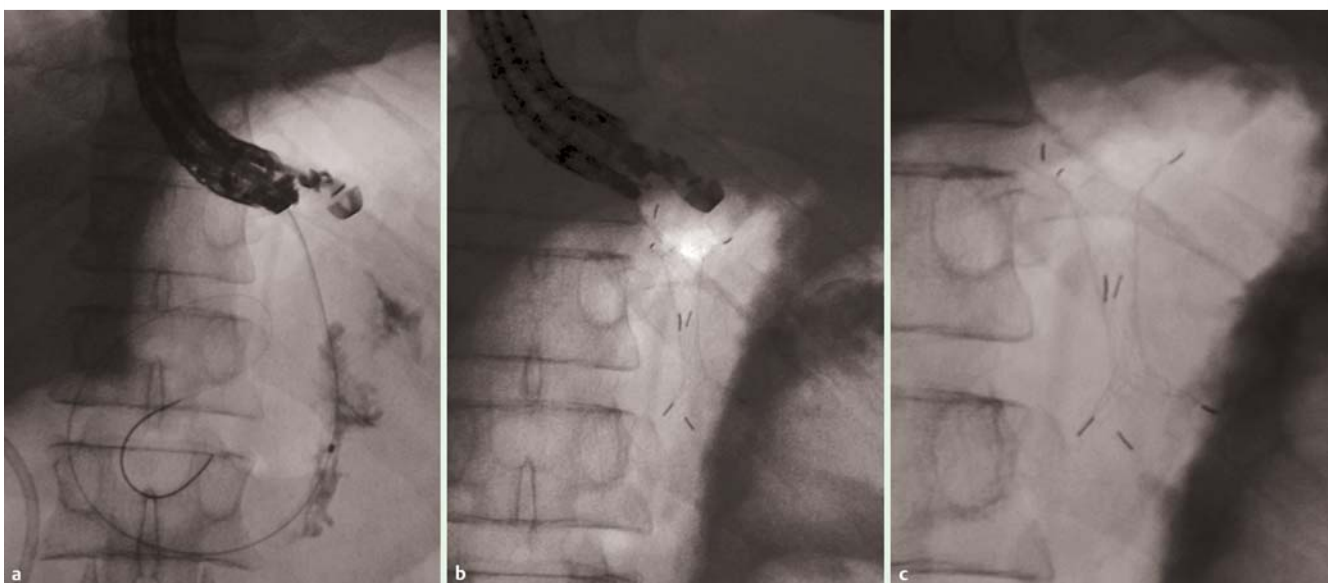


Fig. 2 a–c Radiological images of covered self-expandable metal stent (CSEMS) placement.

Wide flares at the extremities of a CSEMS ensure stable positioning of the stent in the transmural gastric fistula, and allow complete drainage in one session, reducing the time necessary for resolution. This type of CSEMS, due to its short length and wide flares, seems to offer the best solution for treatment of large, infected pseudocysts, with elimination of migration-related problems.

Endoscopy_UCTN_Code_TTT_1AS_2AD

Competing interests: None

I. Tarantino, M. Traina, L. Barresi, M. Di Pisa, G. Curcio, A. Granata

Department of Gastroenterology, ISMETT/UPMC (University of Pittsburgh Medical Center in Italy), Palermo, Italy

References

- 1 *Giovannini M, Pesenti C, Rolland AL et al.* Endoscopic ultrasound guided drainage of pancreatic pseudocysts or pancreatic abscesses using a therapeutic echoendoscope. *Endoscopy* 2001; 33: 473–477
- 2 *Talreja JP, Shami VM, Ku J et al.* Transenteric drainage of pancreatic-fluid collections with fully covered self-expanding metallic stents. *Gastrointest Endosc* 2008; 68: 1199–1203
- 3 *Tarantino I, Barresi L, Fazio V et al.* EUS-guided self-expandable stent placement in 1 step: a new method to treat pancreatic abscess. *Gastrointest Endosc* 2009; 69: 1401–1403
- 4 *Tarantino I, Traina M, Barresi L et al.* Transgastric plus transduodenal necrosectomy with temporary metal stents placement for treatment of large pancreatic necrosis. *Pancreas* 2010; 39: 269–270
- 5 *Belle S, Collet P, Post S et al.* Temporary cystogastrostomy with self-expanding metallic stents for pancreatic necrosis. *Endoscopy* 2010; 42: 493–495

Bibliography

DOI <http://dx.doi.org/10.1055/s-0031-1291570>
Endoscopy 2012; 44: E147–E148
© Georg Thieme Verlag KG
Stuttgart · New York
ISSN 0013-726X

Corresponding author

Professor I. Tarantino
via Tricomi
Palermo, 90100
Italy
Fax: +39-091-6665340
itarantino@ismett.edu