

Noninvasive treatment of pneumoperitoneum after gastric mucosectomy microperforation

A 75-year-old woman with epigastric pain was referred to our center for removal of a polypoid lesion in the stomach. Esophago-gastroduodenoscopy revealed a 25-mm semipedunculate, polypoid, multilobular lesion at the small gastric curve. Histopathological examination showed that the lesion was a moderately differentiated adenocarcinoma with invasion of the muscularis mucosa (► Fig. 1).

Abdominal tomography confirmed a 2-cm thickening of the gastric walls without extraperitoneal extension. Endoscopic ultrasound showed the lesion to be 33 × 22 mm in size, mobile, and inhomogeneous, with no infiltration of the muscularis propria. Endoscopic mucosectomy resection (EMR) was carried out [1–3] after identifying and marking the lesion with circumferential electrocoagulation. Following infiltration of hydroxyethyl starch in sodium chloride (Voluven, Fresenius Kabi Italia S.p.A., Verona, Italy) and epinephrine (1 : 20 000, 20 mL) the mucosa was lifted from the submucosa [4]. The lesion was removed by piecemeal technique, using a diathermic snare. Hemostasis was obtained with electrocoagulation and injection of epinephrine (1 : 20 000). On the first postoperative day gaseous abdominal distension was observed with no clinical evidence of perforation. Abdominal radiographs confirmed the presence of abundant intraperitoneal free air and the diaphragm was raised. The patient had severe abdominal pain, but there was no fever and no signs of peritonitis. The abdominal distension and pain persisted throughout the second postoperative day.

Microperforations can occur during EMR, with the high pressure in the stomach facilitating the passage of air into the abdominal cavity. However, microperforations cannot be managed with endoscopic metal clipping because they cannot be seen [5]. We decided to carry out air extraction with intraperitoneal placement of a Verress needle (► Fig. 2) in the right hypochondrium in the peritoneal cavity, following the same technique as used during laparoscopic cholecystectomy.

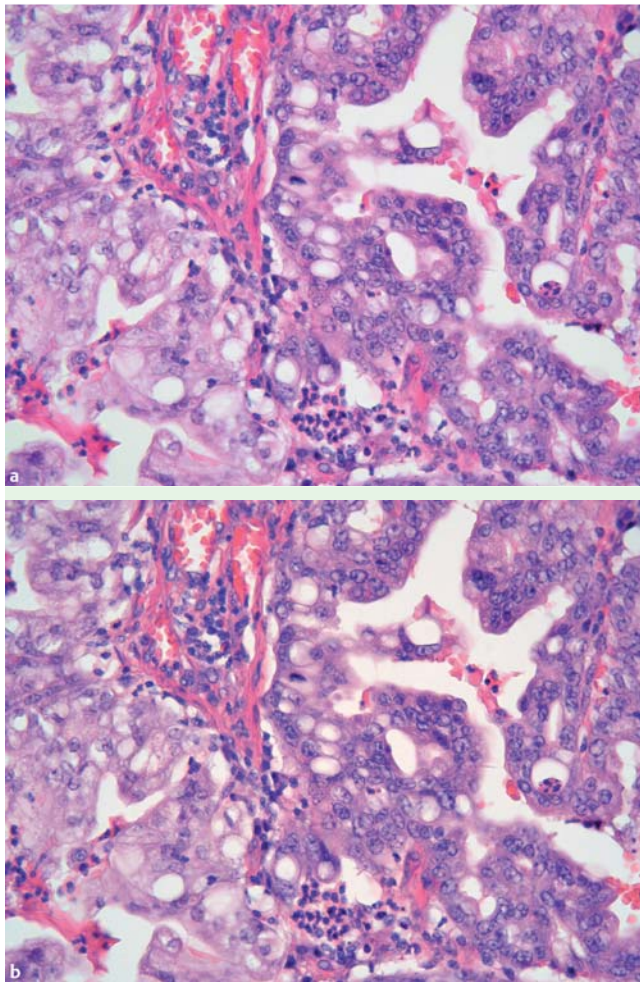


Fig. 1 a, b The biopsy specimen showing a moderately differentiated adenocarcinoma (hematoxylin and eosin, magnification × 40).



Fig. 2 The Verress needle.

This resulted in instantaneous outflow of air and an immediate and marked improvement in the patient's symptoms.

Our case confirms that the presence of free air does not affect the management or the clinical outcome of microperforations and that a simple device such as the Verress needle can be used with immediate benefit and without any risks.

Endoscopy_UCTN_Code_TTT_1AO_2AG
Endoscopy_UCTN_Code_TTT_1AO_2AN

**M. E. Riccioni¹, M. Mutignani¹,
R. Urgesi¹, P. Familiari¹, R. Cianci²,
G. Costamagna¹**

¹ Digestive Endoscopy Unit, Catholic University, Rome, Italy

² Institute of Internal Medicine, Catholic University, Rome, Italy

References

- 1 Tanabe S, Koizumi W, Mitomi H *et al.* Clinical outcome of endoscopic aspiration mucosectomy for early stage gastric cancer. *Gastrointest Endosc* 2002; 56: 708 – 713
- 2 Ono H, Kondo H, Gotoda T *et al.* Endoscopic mucosal resection for treatment of early gastric cancer. *Gut* 2001; 48: 225 – 229
- 3 Soetikno RM, Gotoda T, Nakanishi Y *et al.* Endoscopic mucosal resection. *Gastrointest Endosc* 2003; 57: 567 – 579
- 4 Fujishiro M, Yahagi N, Kashimura K *et al.* Comparison of various submucosal injection solutions for maintaining mucosal elevation during endoscopic mucosal resection. *Endoscopy* 2004; 36: 579 – 583
- 5 Tsunada S, Ogata S, Ohyama T *et al.* Endoscopic closure of perforations caused by EMR in the stomach by application of metallic clips. *Gastrointest Endosc* 2003; 57: 948 – 951

Bibliography

DOI 10.1055/s-0029-1215224

Endoscopy 2009; 41: E286 – E287

© Georg Thieme Verlag KG Stuttgart · New York ·

ISSN 0013-726X

Corresponding author

R. Urgesi

Digestive Endoscopy Unit

Catholic University of Rome

Largo A. Gemelli 8

00168 Rome

Italy

Fax: +39-06-30156581

riurgesi@tin.it