

Aesthetic Surgery Journal

<http://aes.sagepub.com/>

Fractional Nonablative 1540-nm Laser Treatment of Striae Distensae in Fitzpatrick Skin Types II to IV : Clinical and Histological Results

Francesca de Angelis, Larissa Kolesnikova, Franco Renato and Giuseppina Liguori
Aesthetic Surgery Journal 2011 31: 411
DOI: 10.1177/1090820X11402493

The online version of this article can be found at:
<http://aes.sagepub.com/content/31/4/411>

Published by:



<http://www.sagepublications.com>

On behalf of:



[American Society for Aesthetic Plastic Surgery](http://www.asap.org)

Additional services and information for *Aesthetic Surgery Journal* can be found at:

Email Alerts: <http://aes.sagepub.com/cgi/alerts>

Subscriptions: <http://aes.sagepub.com/subscriptions>

Reprints: <http://www.sagepub.com/journalsReprints.nav>

Permissions: <http://www.sagepub.com/journalsPermissions.nav>



Fractional Nonablative 1540-nm Laser Treatment of Striae Distensae in Fitzpatrick Skin Types II to IV: Clinical and Histological Results

Aesthetic Surgery Journal
31(4) 411–419
© 2011 The American Society for
Aesthetic Plastic Surgery, Inc.
Reprints and permission:
[http://www.sagepub.com/
journalsPermissions.nav](http://www.sagepub.com/journalsPermissions.nav)
DOI: 10.1177/1090820X11402493
www.aestheticsurgeryjournal.com

Francesca de Angelis, MD; Larissa Kolesnikova, MD;
Franco Renato, MD; and Giuseppina Liguori, PhD

Abstract

Background: Current striae treatments are limited in their ability to deliver long-lasting improvements for all skin types. The success of fractional nonablative lasers for surgical scars has been attributed to the controlled wound-healing response stimulated by microscopic columns of epidermal and dermal thermal damage.

Objectives: The authors describe the safety and efficacy results of treatment with a fractional nonablative 1540-nm erbium:glass laser in patients with Fitzpatrick skin types II to IV for both striae rubra and striae alba.

Methods: A 51-person clinical study was conducted on striae ranging in duration from one to 40 years. Nine different anatomical locations were treated, including the breasts, hips, and abdomen. Treatment parameters included two to three passes with the 1540-nm laser, with energy settings from 35 to 55 mJ/mb with the 10-mm optical tip or 12 to 14 mJ/mb with the 15-mm optical tip. Two to four total treatments were performed at four- to six-week intervals. Nonblinded efficacy evaluations were performed on all 51 patients; blinded evaluations were conducted by three independent clinicians on 14 randomized sets of pre- and posttreatment images on a 0% to 100% quartile improvement scale. Skin reactions were assessed by the treating physician and recorded at multiple time points, and histology was conducted with hematoxylin and eosin as well as Orcein-Giemsas staining.

Results: Nonblinded clinical assessments rated overall improvement as 50% or greater for all patients at six months or longer after the last treatment. Blinded evaluators reported an overall mean improvement score of 51% to 75% on properly selected images taken at least three months after treatment ($n = 11$). In all patients examined at either 18 or 24 months after treatment, there was no recurrence of striae. Typical side effects included transient erythema and edema. A small minority of patients experienced transient cases of trace postinflammatory hyperpigmentation (PIH), which all resolved. Histologic observations showed thickening of the epidermis and dermis, neocollagenesis, and increased elastin deposition one month after the last treatment.

Conclusions: Positive safety and efficacy results with the fractional nonablative 1540-nm erbium:glass laser for the treatment of striae rubra and striae alba ranging in maturation age from one to 40 years was demonstrated in Fitzpatrick skin types II to IV.

Keywords

striae, stretch marks, fractional lasers, nonablative lasers, cosmetic medicine

Accepted for publication July 17, 2010.

Striae distensae, or stretch marks, arise from progressive or rapid stretching of the dermis¹ and generally form following rapid weight changes during adolescent growth spurts, corticosteroid use, or pregnancy and (less typically) due to Cushing syndrome.^{2–4} The classic anatomical sites affected include the abdomen and breasts for pregnancy-related striae, the outer thighs or lumbosacral regions for adolescent boys, and the buttocks, thighs, upper arms, and breasts for adolescent girls.^{5,6}

Striae progress through three different stages of maturation: the acute stage is characterized by red and slightly

raised striae (rubra), the subacute stage is characterized by purpuric striae, and the chronic stage is characterized by

Dr. de Angelis is a plastic surgeon in private practice in Naples, Italy. Dr. Kolesnikova is a dermatologist in private practice in Milan, Italy. Drs. Renato and Liguori are from the Pathology Department of the G. Pascale National Cancer Institute, Naples, Italy.

Corresponding Author:

Francesca de Angelis, via A.D'Antona 20, 80131, Naples, Italy.
E-mail: francesca.deangelis@yahoo.com

hypopigmented and atrophic striae (alba).⁷ Dermoscopy and histology studies have demonstrated that the varying colors of striae are influenced by melanocyte mechanobiology and that striae formation parallels the wound-healing process of regular scar formation.^{6,8,9} Initial inflammatory changes are followed by a flattening and thinning of the epidermis due to underlying changes in the numbers and organization of collagen, fibrillin, and elastin fibers.⁶ Histologic studies of mature striae reveal stretched collagen fibers aligned parallel to the skin surface, followed by subsequent loss of collagen and increased flattening of rete ridges.⁶ Contributing to the atrophied appearance of striae are the reduced amounts of fibrillin surrounding the dermal-epidermal junction (DE), reduced elastin in the papillary dermis, and reorganization of elastin and fibrillin fibers in deep dermis.¹⁰

Initial treatment modalities for either early- or late-stage striae distensae were aimed at improving the pigment abnormalities. Treatments with 0.1% topical tretinoin (retinoic acid) reduced the mean length and width of pregnancy-related striae but failed to increase collagen or elastin, and they were only effective for early-stage striae.^{11,12} An alternative treatment with demonstrated efficacy for variously-staged striae combined sand abrasion with 15% trichloroacetic acid; however, successful outcomes depended on both the physician's familiarity with the procedure and the patient's compliance with posttreatment care instructions.¹³

Preliminary light and laser therapy studies achieved initial improvements in the overall appearance of striae alba, with the caveat that these results required periodic maintenance treatments every one to four months.^{14,15} Goldberg et al¹⁵ conducted histologic and ultrastructural analyses following treatment with either UVB light or a 308-nm excimer laser and attributed the repigmentation of striae alba to increased production of melanocytes. A second 308-nm excimer study also observed pigment correction after multiple treatments; however, these improvements began to deteriorate by the six-month follow-up visit.¹⁴ A nonablative 1450-nm mid-infrared diode laser study in Asian skin observed no noticeable improvement two months after treatment in any patients and postinflammatory hyperpigmentation (PIH) in 64% of patients.¹⁶ Intense pulsed-light (IPL) studies also yielded inconsistent results; although a study by Hernandez-Perez et al¹⁷ demonstrated clinical improvement and positive microscopic changes, a study by Trelles et al¹⁸ reported low patient satisfaction and poor clinician assessments.

The predominant current laser treatment for striae is the 585-nm pulsed-dye laser (PDL). Based on its affinity for hemoglobin, this therapy has demonstrated benefits for striae rubra but not for striae alba. McDaniel et al¹⁹ treated 39 striae patients with a range of spot sizes and fluences using the 585-nm PDL and observed the best improvements with the 10-mm spot size and low fluence. In another small study comparing the efficacy of the short-pulsed CO₂ laser to the 585-nm PDL, investigators cancelled future study plans due to prolonged erythema and marked PIH in darker skin types.²⁰ Jimenez et al²¹ observed only moderate benefits for striae rubra following 585-nm treatment and no improvements for striae alba, along with PIH. A study combining radiofrequency with 585-nm

treatments for patients with Asian skin reported high patient assessment scores along with increased collagen and elastic fibers, although the study population was largely confined to patients with striae rubra.²²

These early laser studies underscore the need for a treatment that provides long-lasting results for both striae rubra and striae alba by targeting pigment abnormalities as well as textural irregularities. Fractional nonablative laser technology has the potential to meet these requirements through its ability to generate microscopic columns of coagulated damaged tissue that extend through the epidermis deep into the dermis for highly-controlled wound healing. Fractional laser delivery also results in an improved safety profile over standard flat-beam nonablative and ablative laser treatments due to the areas of treated tissue being surrounded by untreated tissue and the laser's increased preservation of the stratum corneum.²³ The proximity of untreated tissue to the microcolumns of thermal damage enables faster migration of nearby epidermal keratinocytes for rapid reepithelialization of the skin (within 24 hours) and an expedited healing response.²³ The skin-rejuvenating effects following fractional photothermolysis (FP) have been attributed to increased rete ridges in the dermal-epidermal junction, increased mucin deposition, evidence of myofibroblast activity, and neocollagenesis.^{24,25} Thus far, FP has been successfully used for photodamaged skin,²⁶ leucodermic scars,²⁷ acne scars,^{28,29} melasma,^{30,31} nonfacial skin rejuvenation,³² thermal burn scars,³³ and, most recently, surgical scars.³⁴

Studies to date have produced mixed results with the fractional nonablative 1550-nm erbium-doped laser for the treatment of striae distensae. In a study conducted in six patients with Fitzpatrick skin types II to IV, Kim et al⁷ observed neocollagenesis, increased elastin fiber deposition, and initial improvements in melanin and erythema indices, which subsequently decreased eight weeks after treatment. Another study examining the efficacy of the 1550-nm laser reported overall improvements between 26% and 50% in 63% of patients and also reported 26% to 50% improvements in texture for 50% of patients three months after six treatments.³⁵ Katz et al³⁶ performed three to five treatments with the 1550-nm laser on striae rubra in two adolescent females, reporting marked improvements along with excellent patient satisfaction. Finally, Bak et al³⁷ observed "good to excellent" improvement in 27% of their patients, with side effects of erythema, crusting, and PIH. In contrast to the majority of published studies—which typically reported better improvement for striae rubra—Bak et al reported superior results for striae alba.

The laser used in this study, the fractional nonablative 1540-nm erbium:glass (Er:Glass) laser (Lux1540; Palomar Medical Technologies, Inc., Burlington, Massachusetts), is currently the only fractional laser approved by the US Food and Drug Administration to treat striae. Advantages of this laser over the predecessor fractional nonablative 1550-nm laser include the stamping compression mode of light delivery (which has the potential to overcome irregularities of the skin surface for deeper, more uniform penetration into the dermis), as well as the laser's ability to treat a narrow region due to the small tip size.

Our objective in this study was to determine whether the 1540-nm Er:Glass laser could safely and effectively improve the appearance of both striae rubra and alba while minimizing the risk of PIH. Results described in this report include histologic findings, safety assessments, and nonblinded and blinded clinical assessments of striae improvement.

METHODS

Laser Device

The 1540-nm fractional nonablative Er:Glass laser (Lux1540) was developed as an accessory to the StarLux Laser and Pulsed Light System (Palomar Medical Technologies, Inc.). The laser generates an array of focused microbeams, up to 470 per pulse. The system's two interchangeable optical tips allow a spot size of either 10 mm or 15 mm delivering energies up to 70 mJ/ μb and 15 mJ/ μb , respectively. Corresponding densities are 100 mB/cm² per pulse with the 10-mm tip and 320 mB/cm² per pulse with the 15-mm tip.

Patients

A total of 51 consecutive patients, three male and 48 female, with variously-staged striae were treated between May 2007 to May 2008 at one of two private practices (Naples, Italy and Milan, Italy). Anatomical locations for treatment included the hips, breasts, abdomen, flanks, knees, buttocks, arms, thighs, and shoulders, with the majority of treatments occurring on the first three sites. Several patients had striae on multiple areas of the body and were treated accordingly. A total of 79 striae locations were treated among the 51 patients.

Histology

Three-millimeter punch biopsies were taken prior to treatment and at one month after the third treatment in three patients. Striae samples were collected from the abdominal wall and inner thighs and immediately fixed in formalin. Serial sections measuring 3 μm in thickness were taken and processed for hematoxylin and eosin (H&E) staining for collagen fiber analysis or Orcein-Giemsma staining for elastic fiber analysis.

Treatment Details

The majority of patients followed our recommended pretreatment regimen, which consisted of applying a compound of 1% hydrocortisone, 4% hydroquinone cream, and 3% vitamin C to their striae for 30 days prior to treatment. The majority of patients received two to three treatments spaced at four- to six-week intervals, although some patients (two out of the 51 total; both female) received four treatments. A range of energy settings between 35 and 55 mJ/ μb (with the 10-mm tip) and between 12 and 14 mJ/ μb (with the 15-mm tip) was applied. Topical anesthetic was not required;

Table 1. Grading Scale and Scoring

% Improvement	Treatment Effect	Score
0%	No change or worsened scar	0
1%-25%	Slight improvement	1
26%-50%	Mild improvement	2
51%-75%	Moderate improvement	3
76%-99%	Significant improvement	4
100%	Complete clearance	5

however, some patients were given ice for increased comfort. After treatment, patients were instructed to apply moisturizing cream multiple times per day to maintain hydration of the skin and to help reduce erythema. All patients were also instructed to apply the same pretreatment topical compound to their treated striae every day for three to six months after their final treatment.

Photo Documentation System

Patient images were taken with a Cybershot DSC-H9 digital camera (Sony, Inc., New York, New York). Lighting and patient positioning were reproduced between baseline and follow-up images using the baseline image as a guide.

Efficacy Evaluations

Both nonblinded and blinded reviewers evaluated the percent improvement after treatment on a 0% to 100% quartile scale (Table 1). Nonblinded reviews were conducted by treating physicians at three months or longer after the last treatment. Blinded reviews were conducted on 14 randomized sets of high-resolution pre- and posttreatment images by nontreating physicians at three months or longer posttreatment. Photo selection for blinded review entailed choosing photos of sufficient quality to permit blinded scoring; selection criteria included reproducible body position and lighting between pre- and posttreatment images and accurate representation of the clinical condition of the striae. Blinded reviewers were independent of the clinical sites (two dermatologists, one plastic surgeon) and were asked to blindly select the treated or "better" image. The data were then unblinded, tabulated, and analyzed.

Safety Evaluations

Side effects were evaluated by the treating physicians immediately after treatment, prior to the next treatment (four to six weeks), and at three, six, and 12 months after the final treatment for long-term evaluations. All side effects were graded for severity and followed until resolution.

RESULTS

Patient ages ranged from 13 to 56 years (mean, 33 years). Fitzpatrick skin type ranged from II to IV (Table 2). The duration of striae ranged from one to 40 years, with an average duration of 12 years (Table 3). The striae formed as a result of pubertal growth (41%, $n = 21$), pregnancy (31%, $n = 16$), weight change (20%, $n = 10$), muscular atrophy (2%, $n = 1$), or unknown causes (6%, $n = 3$) (Table 4).

Histology

H&E staining of pretreatment tissue samples revealed an atrophied epidermis and flattened rete ridges within the papillary dermis. No intact collagen fibers were identifiable in the striae before treatment, and the degenerated appearance of the fibers resulted in uneven staining as well as indistinct borders (Figure 1A). In contrast, following three 1540-nm treatments with the 10-mm tip at 40 mJ and 10-ms pulse width, significant neocollagenesis was observed (Figure 1B). Elastic fibers in the reticular dermis appeared sparse and fragmented prior to the 1540-nm treatment (Figure 2A). One month after the third treatment, elastic fibers were uniformly increased in number throughout the reticular dermis (Figure 2B).

Safety

Treatments were well-tolerated, with only minimal side effects. Immediately following treatment, all patients experienced the expected side effects of edema and/or erythema, with the majority of cases resolving within two to seven days or shortly thereafter. In general, the severity of the side effects depended on the energy level setting. For energy settings between 20 and 30 mJ/ μb , mild edema and/or erythema was initially observed and resolved between six and 12 hours. For energy settings between 30 and 40 mJ/ μb , edema typically resolved within six to 24 hours, and erythema resolved within seven days. For energy settings between 40 and 50 mJ/ μb , edema typically resolved within 24 hours, and erythema resolved within two weeks. Mild PIH was observed in eight patients, but cases were trace or mild in severity, and the majority resolved within one to four months. The remaining three cases resolved by seven, 11, and 15 months after treatment, but we feel it is likely that these cases may have resolved earlier since they were not evaluated until later follow-up visits. The onset and duration of PIH were largely dependent on the patient's Fitzpatrick skin type, as well as strict adherence to proper sun exposure precautions (use of sunblock and no direct sun exposure). There were no reports of hypopigmentation, burns, blisters, or scars at any time throughout the study.

Table 2. Fitzpatrick Skin Type

Fitzpatrick Skin Type	Total No. of Patients
II	7
III	34
IV	10

Table 3. Range of Striae Maturation

Striae Maturation, years	No. (%) of Patients
1-2	7 (14)
3-10	19 (37)
11-20	18 (35)
21-30	6 (12)
31-40	1 (2)

Table 4. Causes of Striae

Cause	% of Patients	Total No. of Patients
Pubertal growth	41	21
Pregnancy	31	16
Weight change	20	10
Muscular atrophy	2	1
Unknown	6	3

Efficacy

Nonblinded study investigators observed improvements of 50% or greater in the appearance of striae for all 51 study patients. These results were corroborated in a blinded review conducted by three independent physicians on a subset of 14 images from these 51 patients; for all correctly selected images ($n = 11$), blinded reviewers reported an overall mean improvement score of "3," or 51% to 75%. "Correctly selected" images included those selected in which the photos accurately reflected the clinical condition of the striae and in which the pre- and posttreatment views were accurately matched.

Overall, the fractional nonablative 1540-nm laser treatment was found to be effective for a wide range of striae varying in color (rubra to alba), anatomical location (breasts, hips, abdomen, thighs, flanks, etc), and maturation (one to 40 years). Examples of clinical benefits achieved in variously-aged striae and in various Fitzpatrick skin types are shown in Figures 3 through 6.

The histologic and clinical results of this study demonstrate the safety and efficacy of the fractional nonablative 1540-nm Er:Glass laser for the treatment of a wide range

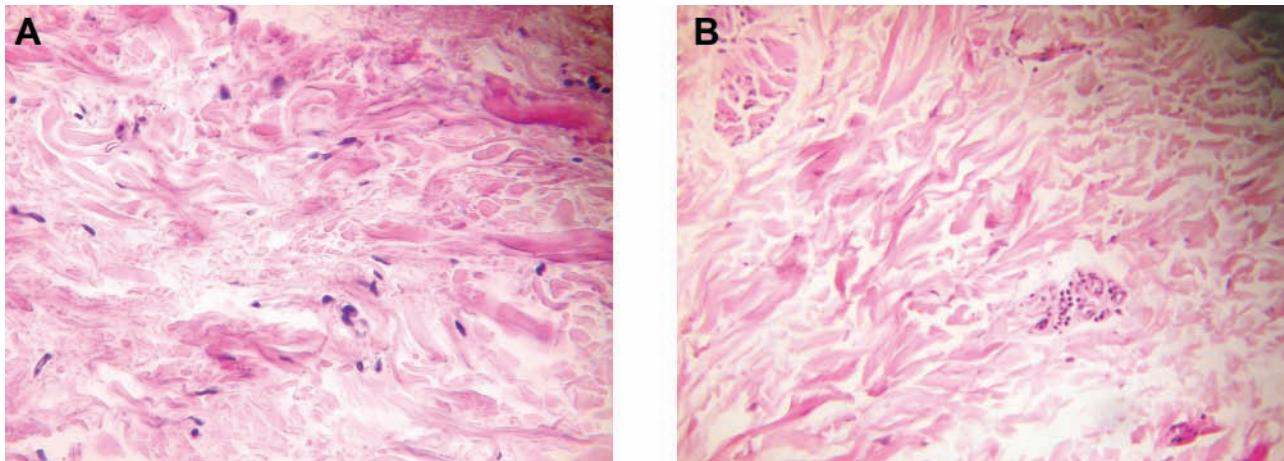


Figure 1. Neocollagenesis in the reticular dermis resulting from the 1540-nm treatment. (A) Untreated striae show an atrophied epidermis with degenerated and fragmented collagen fibers. (B) One month after the last of three treatments with the 1540-nm erbium:glass laser, significant neocollagenesis is demonstrated.

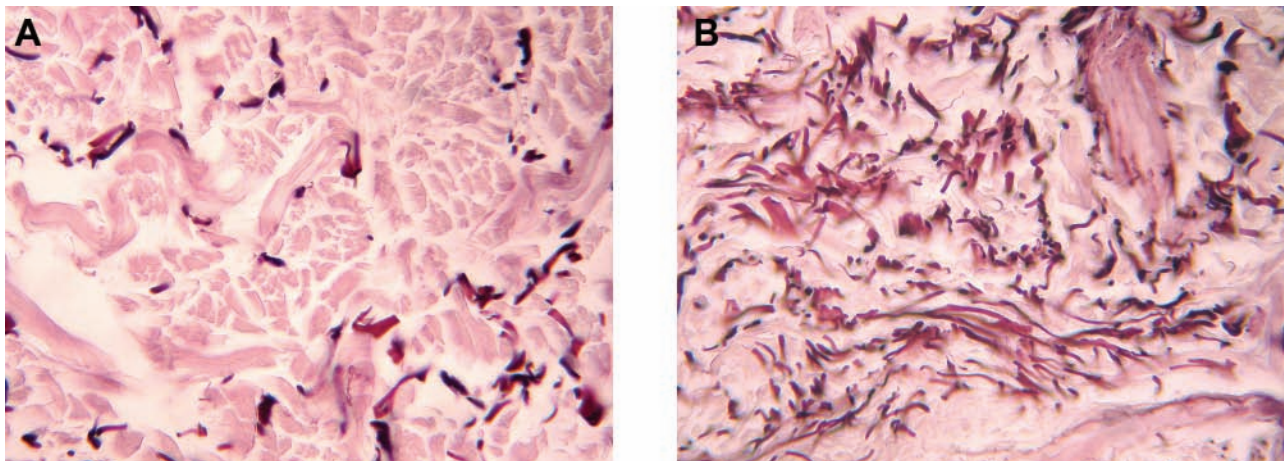


Figure 2. Increased amounts of elastic fibers following the 1540-nm treatment. (A) Before treatment, elastic fibers (dark purple stain) in the reticular dermis appear fragmented and sparse in number. (B) One month after the last of three treatments with the 1540-nm erbium:glass laser, the elastic fibers appear uniformly increased in number.

of striae distensae, from early rubra to late alba stage. Treatments were well-tolerated with only minimal (and expected) side effects, all of which resolved. As of the writing of this report, half of the participants had been followed for up to 18 months posttreatment, and half had been followed for up to 24 months with no recurrence of striae in either group.

DISCUSSION

Our selection of the fractional nonablative 1540-nm laser device applied in this study was based on its demonstrated efficacy in the treatment of scars as well as its preservation of the stratum corneum for enhanced safety and expedited skin recovery after treatment.³⁴ Fractional nonablative lasers deliver microcolumns of thermal damage deep into

the epidermis and dermis to stimulate a controlled wound-healing response, which in turn results in remodeling and regeneration of dermal collagen.^{7,25,37}

Although a variety of previous therapies have been used to treat striae distensae, no previous medium has resulted in sustainable results for both pigment and textural irregularities with equivalent efficacy for striae rubra and striae alba.³⁷ Topical applications of glycolic acid and ascorbic acid have yielded variable results,^{38,39} and tretinoin therapy appears to be beneficial only for early-stage striae (rubra).^{11,12} Studies with 585-nm PDL technology demonstrated pigment correction for striae rubra but not for striae alba, a difference attributed to the system's blood vessel-selective wavelength. Conversely, better outcomes for striae alba were observed in a recent 1550-nm study.³⁷

Blinded evaluators in our study observed improvements of between 51% and 75% for 11 of 14 correctly

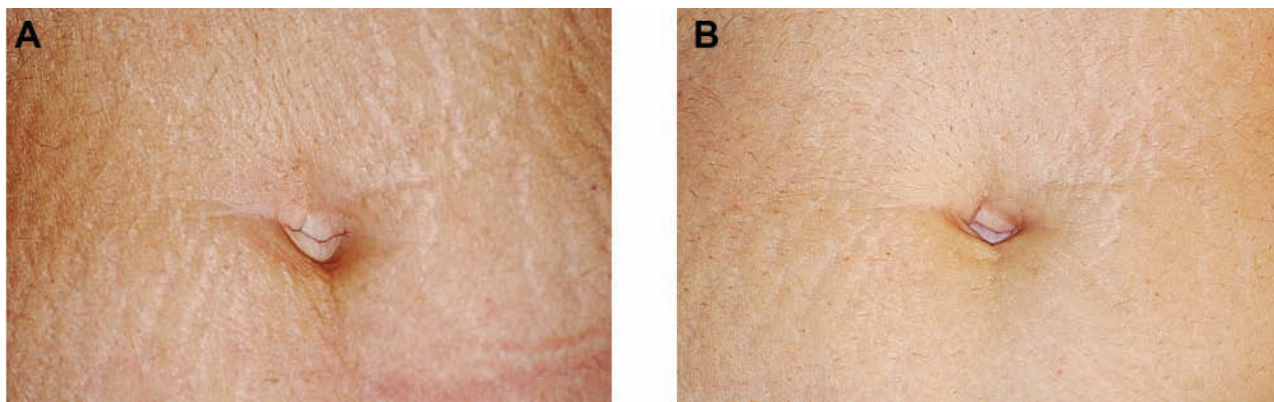


Figure 3. (A) This 40-year-old woman presented with widespread, 12-year-old, pregnancy-related vertical striae alba across her lower abdomen. This patient had a Fitzpatrick III skin type. (B) Three months after the last of four treatments with the 10-mm tip of the 1540-nm erbium:glass laser at energy settings ranging from 45 to 55 mJ/ μ b and a 15-ms pulse width, the hypopigmentation and textural irregularities were significantly reduced and the patient's skin appeared uniformly smooth. Another notable feature of this patient's clinical outcome was the marked decrease in pretreatment hypopigmentation; taken together, these improvements in pigment and texture contributed to an overall softening and smoothing of the striation-like appearance of the treated region.

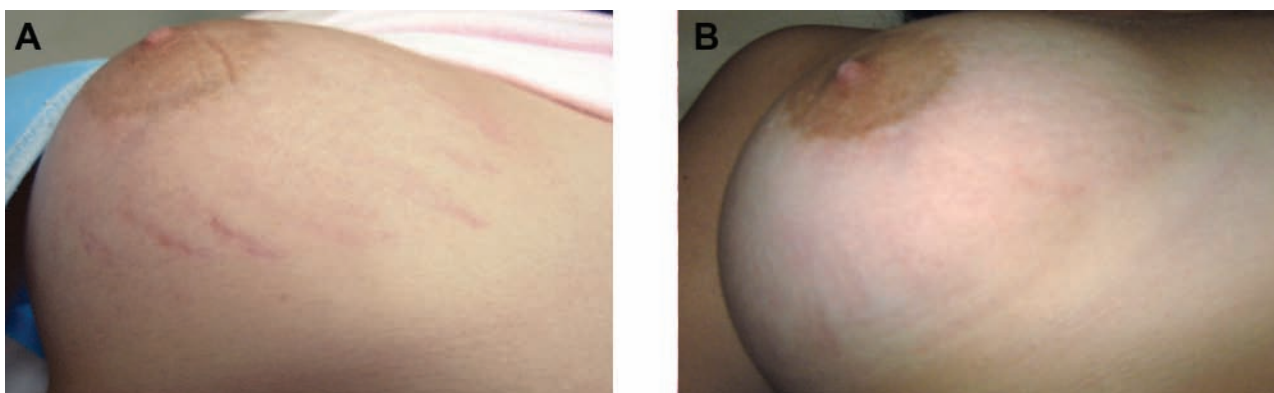


Figure 4. (A) This 30-year-old woman presented with one-year-old striae rubra spanning her breasts as a result of pubertal growth. This patient had a Fitzpatrick III skin type. (B) Four months after the last of three treatments with the 10 mm-tip of the 1540-nm erbium:glass laser at 40 mJ/ μ b and a 15-ms pulse width, the pinkish-red discoloration of the striae appeared markedly reduced.

selected images of treated striae, including striae rubra and alba. Nonblinded assessments of the entire population by study investigators concluded that all striae exhibited improvements of 50% or greater. One of the strengths of this study was the wide diversity in striae maturation, as shown in Table 2. Although most striae fell between the ages of three and 20 years (72% total), 14% of treated striae scars were one to two years old, and 14% were more than 20 years old. The observed corrections for pigmented striae can most likely be attributed to the extrusion of melanin through microscopic epidermal necrotic debris (MENDs), along with the migration of nearby keratinocytes and melanocytes from adjacent untreated tissue into coagulated tissue.^{25,34}

Histologic analyses have demonstrated that striae formation parallels the wound healing observed in scar

formation⁹; therefore, comprehensive improvements should address the underlying texture and scarring sequelae. Preliminary investigations of fractional nonablative photothermolysis demonstrated the capability of this technology to induce dermal remodeling,²³⁻²⁵ and these histologic changes (neocollagenesis, increased epidermal thickness) have recently been confirmed in striae studies with the 1550-nm laser.^{7,37}

The dermal remodeling capabilities of the fractional nonablative 1540-nm laser were recently tested in a resurfacing scar study conducted by Vasily et al,³⁴ in which 73% of treated scars improved 50% or more, and histologic observations included renewal and reorganization of dermal collagen. In the current study, we observed thickening of the epidermis and dermis as well as greater organization and an increased number of collagen fibers at

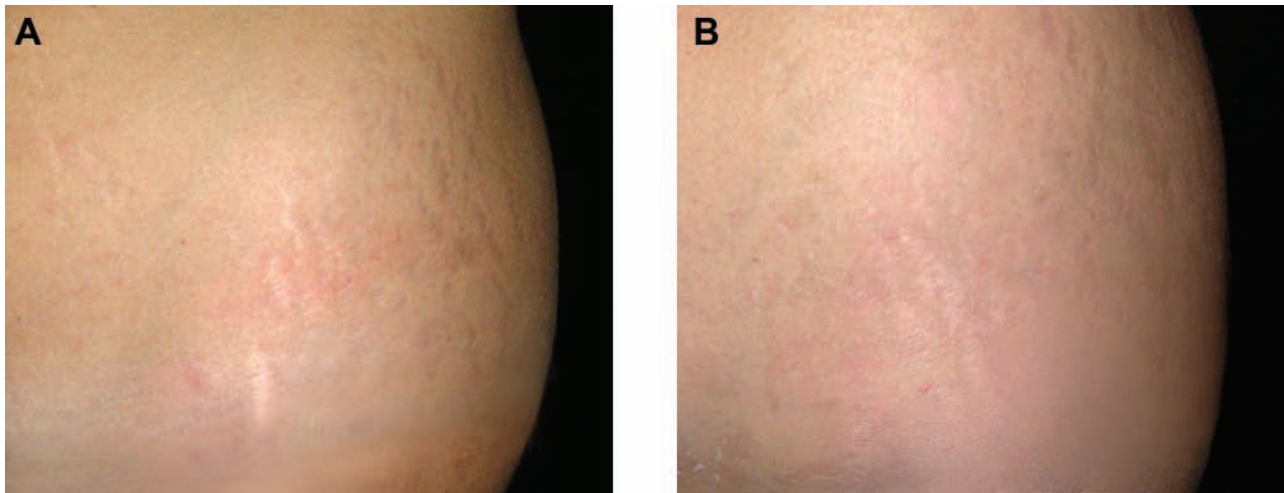


Figure 5. (A) This 41-year-old woman presented with 17-year-old, hypopigmented, pregnancy-related striae alba dispersed across her lower hips. The striae were characterized by palpable depression and “pearliness.” This patient had a Fitzpatrick IV skin type. (B) Nine months after the last of four treatments with the 10-mm tip of the 1540-nm erbium:glass laser at 40 mJ/ μ b and a 15-ms pulse width, the hypopigmentation, “pearliness,” and textural irregularities were all significantly improved.

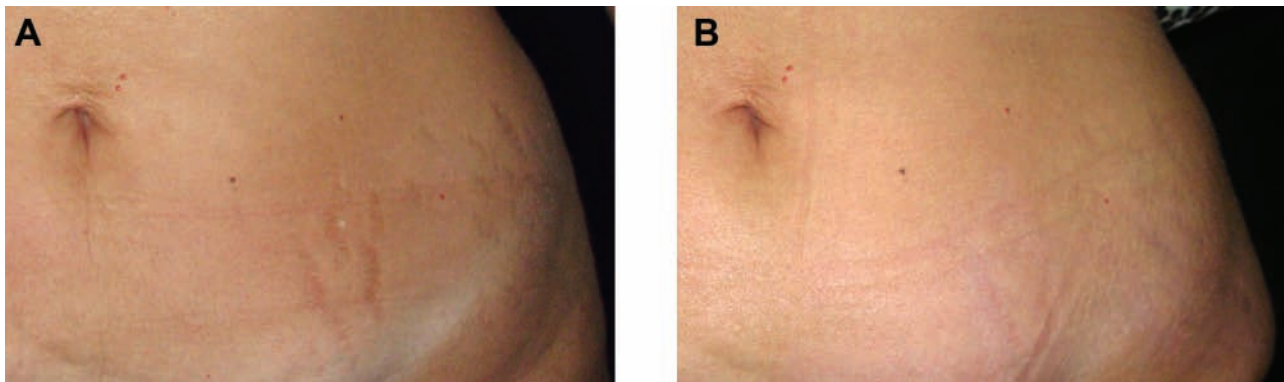


Figure 6. (A) This 43-year-old woman presented with 19-year-old, pregnancy-related, visible striae alba across her lower abdomen and hips. This patient had a Fitzpatrick IV skin type. (B) Three months after the last of three treatments with the 10-mm tip of the 1540-nm erbium:glass laser at 40 mJ/ μ b and a 15-ms pulse width, the patient demonstrated compelling improvements in both pigment and texture.

30 days after the last treatment. Additionally, we observed increased numbers and more uniform distribution of elastic fibers in the papillary dermis. These results, although suggestive of enhanced rebuilding of dermal elastin, were taken from only a small number of patients and will require additional sampling to confirm. If validated with larger systematic sampling, these findings support the rebuilding of skin as an important mechanism leading to the observed improvements in the appearance of striae.

As mentioned previously, independent blinded image evaluations from this study revealed improvements of 51% to 75% or more in the appearance of striae. In contrast, blinded evaluators in the Bak et al³⁷ study reported a mean clinical improvement of 25% to 50% with a 1550-nm laser, with the majority graded as improving less than 25%. Of the eight patients randomly evaluated in a study with the 1550-nm

laser by Stotland et al,³⁵ 63% of patients demonstrated improvements of 26% to 50%. Although the litmus test would be a direct-comparison, split-body study of both fractional nonablative devices, we speculate that the higher efficacy of the 1540-nm device in our study may be attributed to the following three factors: (1) the pre- and posttreatment topical treatment regimen, (2) the optimized zone of treatment established through our range-finding testing, and (3) the mode in which the treatment was applied.

We feel that the topical treatment regimen kept the skin well-hydrated and prevented or managed any postinflammatory pigmentation, particularly for patients with darker skin types. Although there is a precedent for topical applications of 10% L-ascorbic acid (a form of vitamin C) providing some improvement for striae alba in combination with 20% glycolic acid,³⁸ since there are no published reports of

either hydrocortisone or hydroquinone independently improving striae, we feel any bias introduced with the application of this topical regimen would be minimal.

Our optimized zone of treatment was developed to allow for the best combination of coverage and depth of treatment. Treatments that yield high coverage rates or deep dermal penetration increase the risk of prolonged side effects; conversely, shallow coverage or treatments with limited dermal depth are associated with lower efficacy. Among the authors' practices, enough patients (more than 100) have been treated to identify a standard treatment protocol associated with long-lasting results and limited side effects. By first applying a range of treatment parameters and closely monitoring our patients for both safety and efficacy outcomes, we were able to determine that treatment parameters ranging from 30 to 50 mJ/ μ b provided the best clinical outcomes with only limited or transient side effects. Finally, we speculate that the stamping mode of energy delivery may be better suited to addressing the unique textural irregularities of striae due to the practitioner's ability to compress the skin for uniform, even contact, which ensures effective and consistent distribution of microbeams into the skin.

Another pitfall of many current striae treatments is their inability to provide long-lasting results. Current published studies either fail to mention the longevity of observed improvements or state that their results require periodic maintenance treatments.^{7,14} We have now followed-up with half of our patients for up to 18 months and the other half for up to 24 months posttreatment and observed no recurrence of striae.

Patients tolerated the treatment well, and all observed side effects were transient in nature. Side effects reported immediately following treatment included erythema and edema, which typically resolved within two to seven days. Trace PIH was observed in a small majority of patients and resolved over time. These skin reactions are characteristic of fractional nonablative treatments and are indicative of dermal wound healing.

The limitations of our study include the small set of images available for blinded review due to the challenges of obtaining reproducible pre- and posttreatment images of striae. Striae are particularly difficult to photograph, requiring reproducible lighting and subject positioning. As a result, we only selected those images that accurately reflected the clinical condition of the striae. We also learned that proper patient selection was critical to ensuring that striae responded quickly and effectively to treatment. Slower improvement was observed in darker skin types (IV-V), with maximal improvement often not visible until a year after the final treatment due to the lower energy settings, which helped avoid side effects such as hyperpigmentation. Another limitation is the lack of a universal classification scale to grade the condition of striae prior to treatment. Ideally, such a scale could be applied to guide the physician in designing the optimal protocol (ie, number of treatments and follow-up visits) and would provide the physician with an expected timeframe for when maximal results would be achieved.

Based on our experience, improvements in striae may be affected by sex, age, body contour sites, skin tone, diet, age of striae, etiology, and striae pattern. Body locations that seemed to respond better to treatment included the abdomen, breast, inner thighs, and legs, whereas striae located on the buttocks and outer thighs seemed to be associated with an increased risk of hyperpigmentation. As stated, we have now treated striae ranging in maturation age from one to 40 years and feel that the improvements are more dependent on the density, length, and depth of the striae than on maturation age.

CONCLUSIONS

Significant textural and pigment corrections were observed for a wide range of striae rubra and striae alba after treatment with a 1540-nm fractional nonablative laser. Advantages of the fractional technology include greater preservation of the stratum corneum for enhanced safety, along with dermal remodeling through controlled wound healing. Side effects were minimal and resolved relatively quickly. High rates of clinical efficacy (as evaluated through independent blinded review as well as physician assessment) were reported. Histologic studies showed neocollagenesis, epidermal thickening, and increased elastic fibers.

Disclosures

Dr. de Angelis is a paid investigator and speaker for Palomar Medical (the manufacturer of the laser used in this study).

Funding

Palomar Medical (the manufacturer of the laser used in this study) provided writing assistance for this manuscript.

REFERENCES

1. McDaniel DH. Laser therapy of stretch marks. *Dermatol Clin* 2002;20(1):67-76, viii.
2. Zheng P, Lavker RM, Kligman AM. Anatomy of striae. *Br J Dermatol* 1985;112(2):185-193.
3. Nieman LK, Ilias I. Evaluation and treatment of Cushing's syndrome. *Am J Med* 2005;118(12):1340-1346.
4. Cho S, Park ES, Lee DH, Li K, Chung JH. Clinical features and risk factors for striae distensae in Korean adolescents. *J Eur Acad Dermatol Venereol* 2006;20(9):1108-1113.
5. Chang AL, Agredano YZ, Kimball AB. Risk factors associated with striae gravidarum. *J Am Acad Dermatol* 2004;51(6):881-885.
6. Elsaie ML, Baumann LS, Elsaie LT. Striae distensae (stretch marks) and different modalities of therapy: an update. *Dermatol Surg* 2009;35(4):563-573.
7. Kim BJ, Lee DH, Kim MN, et al. Fractional photothermolysis for the treatment of striae distensae in Asian skin. *Am J Clin Dermatol* 2008;9(1):33-37.
8. Hermanns JF, Pierard GE. High-resolution epiluminescence colorimetry of striae distensae. *J Eur Acad Dermatol Venereol* 2006;20(3):282-287.

9. Atwal GS, Manku LK, Griffiths CE, Polson DW. Striae gravidarum in primiparae. *Br J Dermatol* 2006;155(5):965-969.
10. Watson RE, Parry EJ, Humphries JD, et al. Fibrillin microfibrils are reduced in skin exhibiting striae distensae. *Br J Dermatol* 1998;138(6):931-937.
11. Kang S, Kim KJ, Griffiths CE, et al. Topical tretinoin (retinoic acid) improves early stretch marks. *Arch Dermatol* 1996;132(5):519-526.
12. Rangel O, Arias I, Garcia E, Lopez-Padilla S. Topical tretinoin 0.1% for pregnancy-related abdominal striae: an open-label, multicenter, prospective study. *Adv Ther* 2001;18(4):181-186.
13. Adatto MA, Deprez P. Striae treated by a novel combination treatment—sand abrasion and a patent mixture containing 15% trichloroacetic acid followed by 6-24 hrs of a patent cream under plastic occlusion. *J Cosmet Dermatol* 2003;2(2):61-67.
14. Alexiades-Armenakas MR, Bernstein LJ, Friedman PM, Geronemus RG. The safety and efficacy of the 308-nm excimer laser for pigment correction of hypopigmented scars and striae alba. *Arch Dermatol* 2004;140(8):955-960.
15. Goldberg DJ, Marmur ES, Schmults C, Hussain M, Phelps R. Histologic and ultrastructural analysis of ultraviolet B laser and light source treatment of leukoderma in striae distensae. *Dermatol Surg* 2005;31(4):385-387.
16. Tay YK, Kwok C, Tan E. Non-ablative 1,450-nm diode laser treatment of striae distensae. *Lasers Surg Med* 2006;38(3):196-199.
17. Hernandez-Perez E, Colombo-Charrier E, Valencia-Ibieta E. Intense pulsed light in the treatment of striae distensae. *Dermatol Surg* 2002;28(12):1124-1130.
18. Trelles MA, Levy JL, Ghersetich I. Effects achieved on stretch marks by a nonfractional broadband infrared light system treatment. *Aesthetic Plast Surg* 2008;32(3):523-530.
19. McDaniel DH, Ash K, Zukowski M. Treatment of stretch marks with the 585-nm flashlamp-pumped pulsed dye laser. *Dermatol Surg* 1996;22(4):332-337.
20. Nouri K, Romagosa R, Chartier T, Bowes L, Spencer JM. Comparison of the 585 nm pulse dye laser and the short pulsed CO₂ laser in the treatment of striae distensae in skin types IV and VI. *Dermatol Surg* 1999;25(5):368-370.
21. Jimenez GP, Flores F, Berman B, Gunja-Smith Z. Treatment of striae rubra and striae alba with the 585-nm pulsed-dye laser. *Dermatol Surg* 2003;29(4):362-365.
22. Suh DH, Chang KY, Son HC, Ryu JH, Lee SJ, Song KY. Radiofrequency and 585-nm pulsed dye laser treatment of striae distensae: a report of 37 Asian patients. *Dermatol Surg* 2007;33(1):29-34.
23. Geronemus RG. Fractional photothermolysis: current and future applications. *Lasers Surg Med* 2006;38(3):169-176.
24. Manstein D, Herron GS, Sink RK, Tanner H, Anderson RR. Fractional photothermolysis: a new concept for cutaneous remodeling using microscopic patterns of thermal injury. *Lasers Surg Med* 2004;34(5):426-438.
25. Laubach HJ, Tannous Z, Anderson RR, Manstein D. Skin responses to fractional photothermolysis. *Lasers Surg Med* 2006;38(2):142-149.
26. Rostan EF. Laser treatment of photodamaged skin. *Facial Plast Surg* 2005;21(2):99-109.
27. Glaich AS, Rahman Z, Goldberg LH, Friedman PM. Fractional resurfacing for the treatment of hypopigmented scars: a pilot study. *Dermatol Surg* 2007;33(3):289-294; discussion 293-294.
28. Hu S, Chen MC, Lee MC, Yang LC, Keoprasom N. Fractional resurfacing for the treatment of atrophic facial acne scars in Asian skin. *Dermatol Surg* 2009;35(5):826-832.
29. Alster TS, Tanzi EL, Lazarus M. The use of fractional laser photothermolysis for the treatment of atrophic scars. *Dermatol Surg* 2007;33(3):295-299.
30. Rokhsar CK, Fitzpatrick RE. The treatment of melasma with fractional photothermolysis: a pilot study. *Dermatol Surg* 2005;31(12):1645-1650.
31. Tannous ZS, Astner S. Utilizing fractional resurfacing in the treatment of therapy-resistant melasma. *J Cosmet Laser Ther* 2005;7(1):39-43.
32. Wanner M, Tanzi EL, Alster TS. Fractional photothermolysis: treatment of facial and nonfacial cutaneous photodamage with a 1,550-nm erbium-doped fiber laser. *Dermatol Surg* 2007;33(1):23-28.
33. Haedersdal M, Moreau KE, Beyer DM, Nymann P, Alsbjorn B. Fractional nonablative 1540 nm laser resurfacing for thermal burn scars: a randomized controlled trial. *Lasers Surg Med* 2009;41(3):189-195.
34. Vasily DB, Cerino ME, Ziselman EM, Zeina ST. Non-ablative fractional resurfacing of surgical and post-traumatic scars. *J Drugs Dermatol* 2009;8(11):998-1005.
35. Stotland M, Chapas AM, Brightman L, et al. The safety and efficacy of fractional photothermolysis for the correction of striae distensae. *J Drugs Dermatol* 2008;7(9):857-861.
36. Katz TM, Goldberg LH, Friedman PM. Nonablative fractional photothermolysis for the treatment of striae rubra. *Dermatol Surg* 2009;35(9):1430-1433.
37. Bak H, Kim BJ, Lee WJ, et al. Treatment of striae distensae with fractional photothermolysis. *Dermatol Surg* 2009;35(8):1215-1220.
38. Ash K, Lord J, Zukowski M, McDaniel DH. Comparison of topical therapy for striae alba (20% glycolic acid/0.05% tretinoin versus 20% glycolic acid/10% L-ascorbic acid). *Dermatol Surg* 1998;24(8):849-856.
39. Pribanich S, Simpson FG, Held B, Yarbrough CL, White SN. Low-dose tretinoin does not improve striae distensae: a double-blind, placebo-controlled study. *Cutis* 1994;54(2):121-124.