

Painful Flexor Carpi Radialis Brevis Muscle: An Ultrasound and Magnetic Resonance Imaging Assessment

URIGO, Carlo, *et al.*

Reference

URIGO, Carlo, *et al.* Painful Flexor Carpi Radialis Brevis Muscle: An Ultrasound and Magnetic Resonance Imaging Assessment. *Journal of Ultrasound in Medicine*, 2017, vol. 36, no. 10, p. 2190-2193

DOI : 10.1002/jum.14305

PMID : 28675495

Available at:

<http://archive-ouverte.unige.ch/unige:95538>

Disclaimer: layout of this document may differ from the published version.



**UNIVERSITÉ
DE GENÈVE**

Painful Flexor Carpi Radialis Brevis Muscle: An Ultrasound and Magnetic Resonance Imaging Assessment

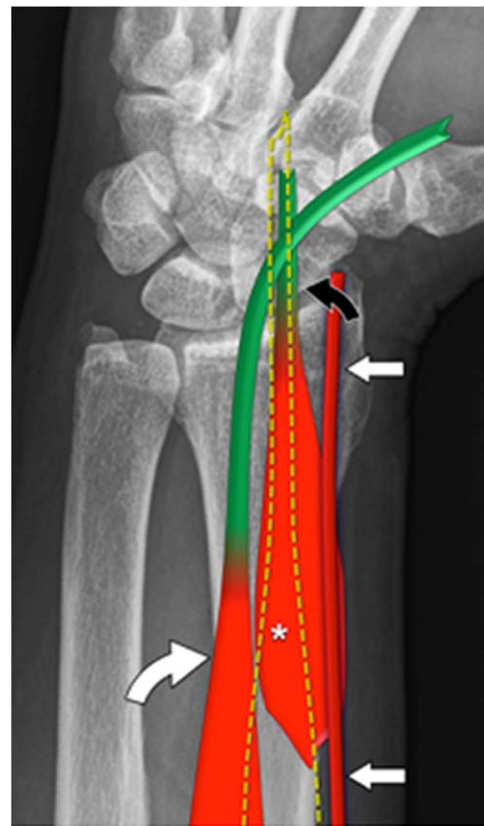
With the advent of modern cross-sectional imaging techniques, such as ultrasound (US) imaging, computed tomography, and magnetic resonance imaging (MRI), accessory muscles are frequently encountered and can be accurately assessed noninvasively.¹ Accessory muscles are frequently asymptomatic and are commonly overlooked during routine imaging evaluations performed for other purposes.^{1,2} In a minority of patients, they present as painless masses or can cause local symptoms related to compression of adjacent structures such as nerves,³ vessels, and tendons.¹ Awareness of the existence of accessory muscles as well as their location, resulting in possible nerve compression, is necessary for establishing an accurate diagnosis and appropriate treatment for compressive neuropathies.⁴ Accessory muscles can present with symptoms of median or ulnar nerve compression.⁵ The flexor carpi radialis brevis is a rare anomalous muscle of the wrist first described by Fano in 1851 and subsequently by Woods in 1867 (Figure 1).⁶ The incidence of the flexor carpi radialis brevis has been reported to be 2.6% to 7.5%.⁷ We report the US and MRI findings of a flexor carpi radialis brevis causing pain in the distal radial forearm, irradiating into the volar wrist.

A 62-year-old professional piano player presented with overuse pain in the radial volar aspect of the distal right forearm and wrist. The patient had a nearly unremarkable clinical history. The clinical examination showed a normal appearance of the forearm and wrist. The skin was normal. No tenderness was noted even at deep palpation. A US examination was performed with a broadband high-resolution transducer working at 5–18 MHz to rule out tendinopathy. Ultrasound showed the presence of an accessory muscle arising from the lateral part of the volar aspect of the distal radius, distally to the origin of the flexor pollicis longus (Figures 2 and 3). The muscle ran anterior to the pronator quadratus and presented a thin tendon located deep to the flexor carpi radialis tendon. Distally, the flexor carpi radialis brevis tendon inserted into the capitate bone and the base of the third and fourth metacarpals. The muscle showed a regular echo structure, and the tendon was normal, with no sign of tendinopathy. On US imaging, the clinically painful site corresponded to a normal-appearing proximal aspect of the muscle. Contralateral US images showed absence of accessory muscles. To confirm the clinical suspicion of overuse edema of the

accessory muscles, we performed an MRI examination after asking the patient to play piano for 3 hours. The scan was performed about 30 minutes after the patient played the piano. The MRI scan was performed with a 1.5-T scanner using an extremity coil. Axial proton density-weighted fat-saturated and T1-weighted, sagittal T1-weighted, and postcontrast axial T1-weighted fat-saturated images were obtained. Contrast images were performed because of the edema noted in the muscle to increase the detection of pathologic findings. The MRI confirmed the presence of the flexor carpi radialis brevis and had an excellent imaging correlation with US (Figures 2 and 3).

In addition, MRI showed local edema and gadolinium uptake in the postcontrast T1-weighted, fat-saturated images of the proximal flexor carpi radialis brevis and at its attachment into the radius (Figure 4), confirming that the local swelling and inflammation were responsible for the clinical symptoms. The patient

Figure 1. Schematic drawing illustrating the flexor carpi radialis brevis muscle (asterisk) and tendon (black arrow) and their relationships with the flexor carpi radialis muscle and tendon (dotted borders), flexor pollicis longus muscle and tendon (curved white arrow), and radial artery (white arrows).



underwent surgical resection of the flexor carpi radialis brevis (Figure 5), followed by complete recovery with absence of recurrent pain.

The flexor carpi radialis brevis muscle is usually encountered as an incidental finding during cadaveric dissection or surgical treatment of distal radius fractures.⁸⁻¹¹ According to Yoshida et al,¹² the incidence of this muscle was 4 per 225 cadavers (2%). Nakahashi and Izumi⁷ reported incidence rates between 2.6% and 7.5%.

The flexor carpi radialis brevis originates from the distal third of the radius on its volar surface, or the volar-adjacent border between the origin of the flexor pollicis longus and the insertion of the pronator quadratus, and it inserts into the base of the second or third metacarpal. Its insertion, however, is subject to frequent variations and may be into any metacarpal base except the first or fifth and radial-side carpal bones, such as the scaphoid, trapezium, trapezoid, and capitate.⁶ The flexor carpi radialis brevis muscle has been previously classified on the basis of its variations of insertion or origin: (1) radiopalmar type, (2) radiocarpal type, (3) radiometacarpal type, and (4) mixed.⁷ The radiocarpal type is the most frequent and has been reported to occur during cadaveric dissection in 2.6% of Japanese patients,¹² in 4% to 7.5% of European white patients,¹³ and in 3.4% of black patients.¹⁴ Dissection studies reported that flexor carpi radialis brevis innervation is provided by the anterior interosseous nerve.¹⁵

An important clinical aspect of the flexor carpi radialis brevis is its proximity to the standard volar approach for distal radius fracture surgery. Recently, as volar plating of distal radius fractures has become popular, surgeons have more likelihood of encountering the flexor carpi radialis brevis.¹⁶ Mantovani et al¹¹ reported 6 cases of the flexor carpi radialis brevis in 172 distal radius fractures (3.5%).

Anomalous muscles in the hand and wrist often arouse compression neuropathy. The flexor carpi radialis brevis may cause anterior interosseous nerve compression.⁷ The anterior interosseous nerve conceivably could be compressed by hypertrophy of this muscle, an aspect of anterior interosseous nerve compression described by Spinner¹⁷ in patients in whom the flexor carpi radialis brevis is present. A symptomatic flexor carpi radialis brevis is, however, extremely rare. To our knowledge, there have been only 3 previously reported cases,^{3,18,19} and only in the case described by Smith and Kakar¹⁹ was a US description of the muscle reported. The authors reported a case of a complete tear of the flexor carpi radialis with proximal retraction to the radioscapoid joint associated with flexor carpi radialis brevis tendinosis and a tendon sheath effusion versus tenosynovitis, which was detected by US and confirmed by MRI.¹⁹ Peers and Kaplan³ performed an MRI scan because of the uncharacteristic clinical nature of the mass. The mass was firm and nonmobile, and it did not have the typical cystic feel

Figure 2. Sagittal US (A and C) and MRI (B) appearance of the flexor carpi radialis brevis muscle. Images show the muscle (asterisks) and tendon (small curved black arrows) arising from the distal radius and lying beneath the tendon of the flexor carpi radialis (large curved black arrows). Scaph indicates scaphoid.

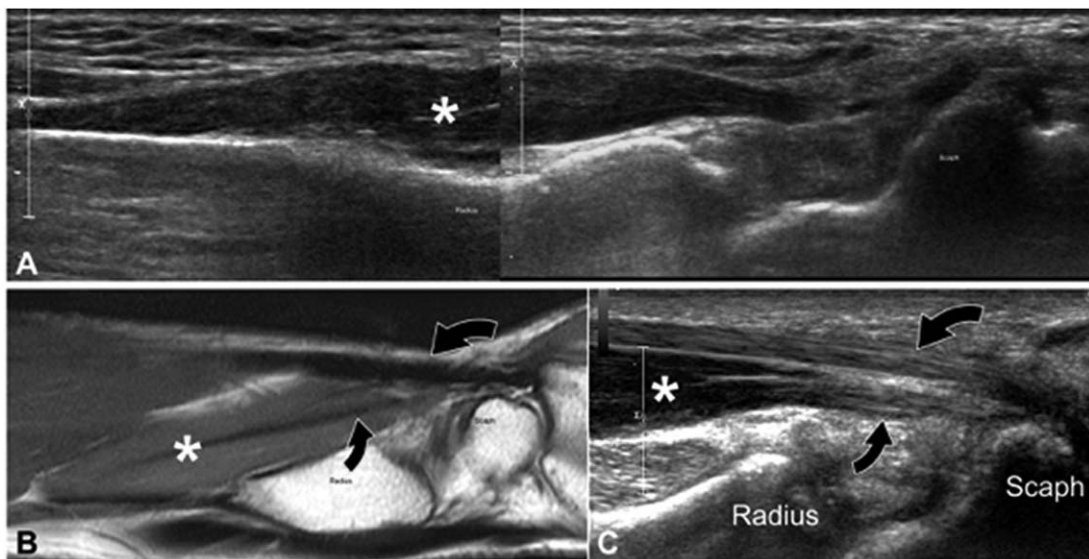
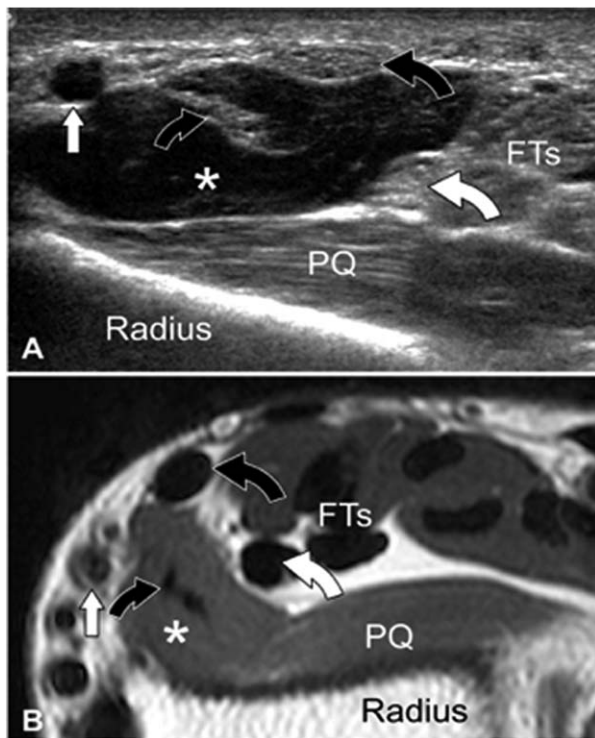


Figure 3. Transverse US (A) and MRI (B) appearance. Images show the relationships of the flexor carpi radialis brevis muscle (asterisks) and tendon (small curved black arrows) with the pronator quadratus muscle (PQ), the flexor carpi radialis tendon (large curved black arrows), the radial artery (white arrows), and the flexor pollicis longus tendon (curved white arrows). FTs indicates flexor tendon.



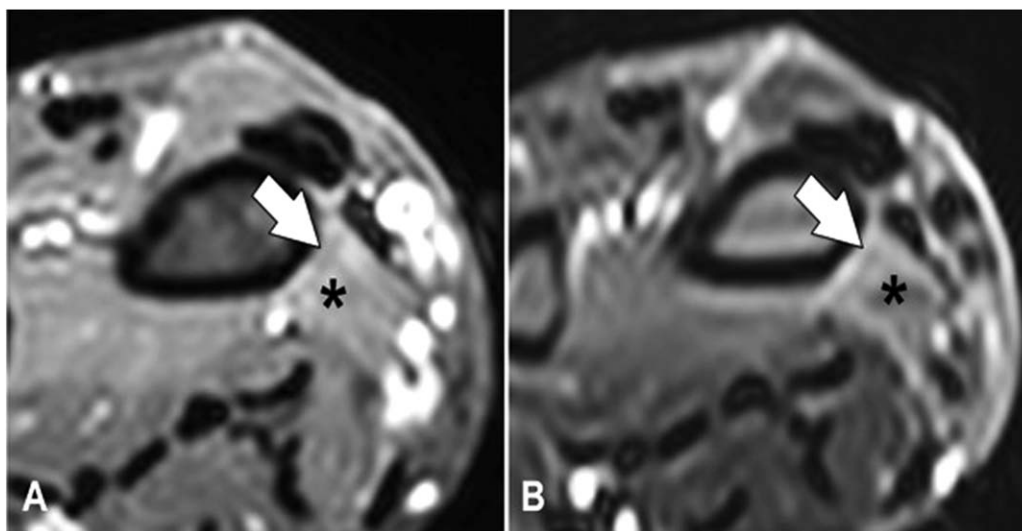
on palpation, as would be found in a ganglion. Magnetic resonance imaging showed the presence of an anomalous muscle. Kosiyatrakul et al¹⁸ reported the first published case of flexor carpi radialis brevis tenosynovitis in a patient clinically suspected of having a volar ganglion cyst or flexor carpi radialis tendinopathy. No preoperative imaging was performed.

Unlike the other cases reported in the literature, in which the pain was caused by tenosynovitis or tendinopathy of the flexor carpi radialis brevis tendon, in our case, the pain was related to overuse-related inflammation of the muscle at its attachment on the radius, which, to our knowledge, has never been reported. The reason

Figure 5. Surgical removal of the flexor carpi radialis brevis muscle (asterisk). Note the normal ulnarly sided displaced flexor carpi radialis tendon (arrow).

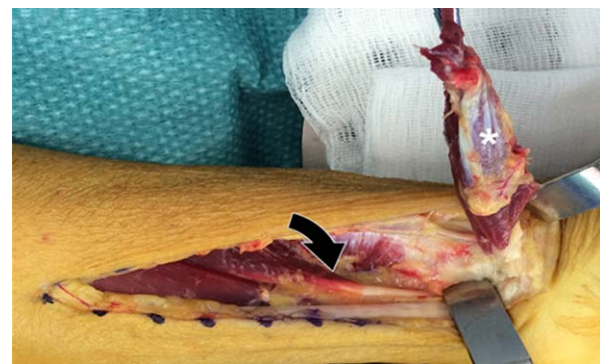

Figure 4. Axial proton density-weighted, fat-saturated and postcontrast T1-weighted spectral presaturation with inversion recovery images show (arrows) edema (A) and contrast enhancement (B) of the proximal portion and insertion of the flexor carpi radialis brevis (asterisks).



for the pain was not related to compression of adjacent nerves due to a mass effect or to a tendon-related disease such as tenosynovitis or tendinosis. On US imaging, the flexor carpi radialis brevis tendon appeared normal, and the muscle belly had a regular echo structure. Magnetic resonance imaging showed a regular signal intensity of the muscle and absence of tendinopathy. Magnetic resonance imaging performed after exercise showed gadolinium uptake in the postcontrast images, suggesting that the pain arose proximally. The accessory muscle and its distal tendon appeared normal at surgical removal.

Other than the case presented by Smith and Kakar,¹⁹ our case is the only one in the literature so far to describe the US features of a flexor carpi radialis brevis confirmed at surgery. Ultrasound allowed us to clearly identify the muscle within the radial volar compartment of the wrist, to detect a normal echo structure of the muscle and tendon, and to highlight its relationships with the pronator quadratus muscle, the radial artery, the flexor carpi radialis, and the flexor pollicis longus. In our case, resection of the accessory muscle allowed a complete resolution of the symptoms, confirming that US as well as MRI was essential for the clinical course of the patient. Nevertheless, MRI was superior to US in detecting the internal muscle edema related to overuse.

In conclusion, we report a case of a painful flexor carpi radialis brevis due to overuse in a professional piano player, which was assessed by US and MRI. Pain in the wrist and distal forearm related to the presence of a flexor carpi radialis brevis is rare, and, to the best of our knowledge, we report the first case related to overuse of the proximal insertion of the muscle rather than its distal tendon. Radiologists must be aware of the possibility of a symptomatic flexor carpi radialis brevis and that US can easily and accurately assess its presence and relationships with the adjacent structures. Magnetic resonance imaging can be useful if performed after exercise to determine the origin of pain.

**Carlo Urigo, MD, Marie Claude Schenkel, MD,
Jean-Yves Beaulieu, MD, Stefano Bianchi, MD**

Studio Radiologico Urigo

Sassari, Italy (C.U.)

Cabinet de Rhumatologie

Carouge, Switzerland (M.C.S.)

Geneva University Hospital

Geneva, Switzerland (J.-Y.B.)

Cabinet Imagerie Medicale

Geneva, Switzerland (C.U., S.B.)

doi: 10.1002/jum.14305

References

1. Sookur PA, Naraghi AM, Bleakney RR, Jalan R, Chan O, White LM. Accessory muscles: anatomy, symptoms, and radiologic evaluation. *Radiographics* 2008; 28:481–499.
2. Zammit J, Singh D. The peroneus quartus muscle: anatomy and clinical relevance. *J Bone Joint Surg Br* 2003; 85:1134–1137.
3. Peers SC, Kaplan FT. Flexor carpi radialis brevis muscle presenting as a painful forearm mass: case report. *J Hand Surg Am* 2008; 33: 1878–1881.
4. Lahey MD, Aulicino PL. Anomalous muscles associated with compression neuropathies. *Orthop Rev* 1986; 15:199–208.
5. De Smet L. Median and ulnar nerve compression at the wrist caused by anomalous muscles. *Acta Orthop Belg* 2002; 68:431–438.
6. Carleton A. Flexor carpi radialis brevis vel profundus. *J Anat* 1935; 69: 292–293.
7. Nakahashi T, Izumi R. Anomalous interconnection between flexor and extensor carpi radialis brevis tendons. *Anat Rec* 1987; 218:94–97.
8. Ho SYM, Yeo CJ. The flexor carpi radialis brevis muscle: an anomaly in forearm musculature—a review article. *Hand Surg* 2011; 16: 245–249.
9. Kang L, Carter T, Wolfe SW. The flexor carpi radialis brevis muscle: an anomalous flexor of the wrist and hand—a case report. *J Hand Surg Am* 2006; 31A:1511–1513.
10. Chong SJ, Al-Ani S, Pinto C, Peat B. Bilateral flexor carpi radialis brevis and unilateral flexor carpi ulnaris brevis muscle: case report. *J Hand Surg Am* 2009; 34A:1868–1871.
11. Mantovani G, Lino W, Fukushima WY, Cho AB, Aita MA. Anomalous presentation of flexor carpi radialis brevis: a report of six cases. *J Hand Surg Eur* 2010; 35E:234–235.
12. Yoshida Y, Yasutaka S, Seki Y. Studies on the flexor carpi radialis profundus and palmaris profundus muscles in man. *Acta Anat Nippon* 1983; 58:59–67.
13. Le Double AF. *Traité des Variations du Système Musculaire de l'Homme*. Vol 2. Paris, France: Schleicher Frères; 1897:141–148.
14. Loth E. *Beiträge zur Anthropologie der Negerweichteile (Muskelsystem)*. Stuttgart, Germany: Strecker and Schröder; 1912:145–153.
15. Dodds SD. A flexor carpi radialis brevis muscle with an anomalous origin on the distal radius. *J Hand Surg Am* 2006; 31:1507–1511.
16. Lee Y, Song S, Sur Y, Ahn C. Flexor carpi radialis brevis: an unusual anomalous muscle of the wrist. *Clin Orthop Surg* 2014; 6:361–364.
17. Spinner M. *Injuries to the Major Branches of Peripheral Nerves of the Forearm*. Philadelphia, PA: WB Saunders Co; 1978:192–193.
18. Kosiyatrakul A, Leunam S, Prachaporn S. Symptomatic flexor carpi radialis brevis: case report. *J Hand Surg Am* 2010; 35A:633–635.
19. Smith J, Kakar S. Combined flexor carpi radialis tear and flexor carpi radialis brevis tendinopathy identified by ultrasound: a case report. *PM R* 2014; 6:956–959.