

Comparative Trial of *N*-Acetyl-Cysteine, Taurine, and Oxerutin on Skin and Kidney Damage in Long-Term Experimental Diabetes

Patrizio Odetti,¹ Carlo Pesce,² Nicola Traverso,³ Stefano Menini,² Elena Pesce Maineri,³ Luana Cosso,³ Sabina Valentini,¹ Stefania Patriarca,³ Damiano Cottalasso,³ Umberto M. Marinari,³ and Maria Adelaide Pronzato³

This study analyzes the effect of chronic treatment with different antioxidants (*N*-acetyl-cysteine [NAC], taurine, a combination of NAC and taurine, and oxerutin) on long-term experimental diabetes induced by streptozotocin in rats. Glycoxidative damage was evaluated in the skin; glomerular structural changes were studied with morphometry and immunohistochemistry. Oxerutin treatment and the combined NAC plus taurine treatment resulted in reduced accumulation of collagen-linked fluorescence in skin in comparison with untreated diabetic rats. All treatments except taurine reduced glomerular accumulation of *N*^ε-(carboxymethyl)lysine and protected against the increase in glomerular volume typical of diabetes; furthermore, the apoptosis rate was significantly decreased and the glomerular cell density was better preserved. Glycoxidative markers in the skin turned out to be good indicators of the glomerular condition. The findings that emerged from our study support the hypothesis that glomerular damage in diabetes can be prevented or at least attenuated by supplementation with specific antioxidants. Treatment with oxerutin and combined treatment with NAC plus taurine gave the most encouraging results, whereas the results of taurine-only treatment were either negligible or negative and therefore suggest caution in the use of this molecule in single-drug treatment courses. *Diabetes* 52:499–505, 2003

Advanced glycation end products (AGEs) accumulate earlier and faster in long-term diabetes than in aging (1). In the glomerulus, AGE are likely to constitute the main mediator of the untoward consequences of hyperglycemia; the increase in oxidative stress, likely caused by hyperglycemia, is an

additional source of damage. Both AGE accumulation and oxidative stress enhance the synthesis of extracellular matrix and the release of toxic cytokines (2,3). Mesangial cells can be damaged by peroxidation of their membrane lipids and by glycation and oxidation of intracellular proteins, as a result of the hyperglycemia-driven upregulation of glucose uptake via GLUT-1 and GLUT-2 transporters (4,5). Because AGE accumulation occurs in all tissues, the concentration of a single end product in the subcutaneous tissue is believed to constitute a handy marker of AGE-related glomerular damage (6); a case in point is the detection of pentosidine, an AGE derived from the glycoxidation reaction. The accumulation of fluorescent adducts of proteins with malondialdehyde (MDA) or 4-hydroxynonenal (HNE) in tissues can indirectly evidence oxidative damage; these two reactive carbonyl compounds are formed by lipid peroxidation, another nonenzymatic cascade involved in the pathogenesis of diabetic complications (7).

Prevention of synthesis and tissue accumulation of AGE- or oxidative-derived end products could constitute a major advance in the treatment of diabetes complications. Several compounds with putative properties against AGE accumulation have been investigated in both clinical and experimental settings (8,9). In most instances, the results have been only partially satisfactory, possibly because the drugs being tested inhibited either glycation or oxidation but not both processes. The present study is a long-term comparative trial of *N*-acetyl-cysteine (NAC), oxerutin (OXE), and taurine (TAU) in experimental diabetes.

Not only does NAC exhibit antioxidant properties (10), but it may also counteract the glycation cascade through the inhibition of oxidation. NAC can also reduce the apoptosis elicited by reactive oxygen species (ROS) (11). These beneficial effects have been documented in endothelial dysfunction, in diabetic neuropathy, and in other instances of cell and tissue damage (12,13). OXE is a flavonoid found in staple foods and in several over-the-counter drugs and belongs to a large family of polyphenolic compounds with antioxidant properties (14). It exhibits superoxide scavenging activity and protects against lipid peroxidation (15). The beneficial effects of OXE have been documented in several conditions involving free radical damage, such as cataractogenesis, endothelial cell damage, and thrombosis (16,17). Flavonoids can also hinder the glycation cascade by inhibiting oxida-

From the ¹Department of Internal Medicine, University of Genova, Genova, Italy; the ²Centre of Pathological Anatomy (CLOPD) DISTBIMO, University of Genova, Genova, Italy; and the ³Department of Experimental Medicine, University of Genova, Genova, Italy.

Address correspondence and reprint requests to Nicola Traverso, DIMES, Section of General Pathology, Via LB Alberti 2, 16151 Genova, Italy. E-mail: ntraverso@medicina.unige.it.

Received for publication 27 June 2002 and accepted in revised form 22 October 2002.

AGE, advanced glycation end product; CML, *N*^ε-(carboxymethyl)lysine; HNE, 4-hydroxynonenal; HPLC, high-performance liquid chromatography; MDA, malondialdehyde; MGV, mean glomerular volume; NAC, *N*-acetyl-cysteine; OXE, oxerutin; ROS, reactive oxygen species; TAU, taurine; TGF, transforming growth factor; TUNEL, transferase-mediated dUTP nick-end labeling.

tive stress and aldose reductase activity (16,18). The antioxidant properties of TAU, an amino acid abundant in human tissues (19), are ascribed to its scavenging activity on HOCl⁻, a highly toxic molecule. The product, taurine chloramine, exhibits lower oxidative activity than HOCl⁻. TAU might also act as an antiglycative compound, providing free amino groups that may compete for the reducing sugars (19,20).

In this study, the effects of the above-mentioned substances on the AGE accumulation and oxidative damage that accompany long-term diabetes were assessed in the subcutaneous tissue by evaluating pentosidine accumulation, quantified by liquid chromatography, and specific fluorescence of AGE and protein adducts with MDA and HNE. In addition, the glomerular accumulation of N^ε-(carboxymethyl)lysine (CML), the main AGE found at this site (21) and a known marker of glycoxidation (22), was demonstrated immunohistochemically. The mean glomerular volume (MGV), glomerular apoptosis rate, and glomerular cell density were also measured. MGV is a reliable parameter used to evaluate glomerular damage in human glomerulosclerosis and in several experimental models of this lesion. There is considerable morphometric evidence of glomerular hypertrophy in diabetes; in addition, the development of glomerulosclerosis, the increase in mean size of the glomeruli, and the total mesangial volume depend on disease duration (23). In contrast, information on glomerular cell turnover in diabetes is still fragmentary (24). A recent study by our group has shown significant rates of apoptosis and a parallel decrease in cellularity in the glomeruli of rats after 6 months of diabetes (25).

RESEARCH DESIGN AND METHODS

Animals. Male Wistar rats ($n = 52$) purchased from Harlan Italy Srl (Milan, Italy) were randomly housed in pairs and fed a standard diet (Piccioni Spa, Milan, Italy) ad libitum. A group of control rats (CTR; $n = 8$) were left untreated. At 12 weeks of age, the remaining rats were rendered diabetic by means of a single intraperitoneal injection of streptozotocin (60 mg/kg), freshly dissolved in sterile citrate buffer (pH 4.5). The glucose concentration in blood taken from a tail vein was determined by means of reactive strips and read with a reflectometer (both from Glucotrend 2, Boehringer Mannheim Italia Spa, Milan, Italy). Stable blood glucose levels >200 mg/dl were considered to indicate diabetes onset.

The diabetic rats were randomly assigned to the following five groups: (1) untreated diabetic rats (UD group); (2) rats treated with NAC ($300 \text{ mg} \cdot \text{rat}^{-1} \cdot \text{day}^{-1}$; NAC group); (3) rats treated with TAU ($2.5 \text{ g} \cdot \text{rat}^{-1} \cdot \text{day}^{-1}$; TAU group); (4) rats treated with both NAC and TAU (same dosages as groups 2 and 3; N+T group); and (5) rats treated with OXE ($2.5 \text{ g} \cdot \text{rat}^{-1} \cdot \text{day}^{-1}$; Roche Italia Spa; OXE group). All rats were maintained at 22–24°C with 12-h dark/light cycles, in accordance with common procedures for good animal care. Blood glucose levels were measured once a week. GHb levels were measured by affinity chromatography (Glycaffin; Isolab, Akron, OH). The rats were killed at 40 weeks of age (~6 months after the onset of diabetes) by bleeding under anesthesia with intraperitoneal injection of sodium pentobarbital (65 mg/kg).

Sample preparation. On killing, blood was withdrawn from the inferior vena cava and aliquots were used to measure glucose and GHb. Samples of subcutaneous connective tissue were collected through a midline incision in the abdominal skin. The samples were washed thoroughly in normotonic saline solution and stored at -80°C until measurements were taken. A small amount of tissue was finely minced and homogenized in ice-cold 0.1 mol/l PBS (pH 7.4) with a Polytron homogenizer (Kinematica, Lucerne, Switzerland), set at level 3, for 2–3 min. Lipids were extracted with chloroform/methanol (2:1) by mild shaking overnight. The pellets were washed with methanol and water, stored overnight at 4°C in 0.05 mol/l Tris-HCl buffer (pH 7.4) with 1 mol/l NaCl, and freed from soluble protein by washing with high-performance liquid chromatography (HPLC)-grade water. The remaining tissue was digested for 24 h (at 37°C with mild shaking) with purified collagenase (type VII; Sigma, St. Louis, MO) in HEPES buffer (0.02 mol/l, pH 7.5) containing 0.01 mol/l CaCl₂

(26). The supernatant was used to determine hydroxyproline content and fluorescence. The undigested collagen amounted to $<20\%$ of the total.

Fluorescence determination. Fluorescence intensity was determined in the digested tissue preparations with an L55B Perkin-Elmer (Verkauf, Munchen, Germany) spectrophotofluorometer at (1) 370-nm excitation (EX)/440-nm emission (EM) for Maillard products (27), (2) 335-nm EX/385-nm EM for pentosidine-like products (28); and (3) 390-nm EX/460-nm EM and 356-nm EX/460-nm EM for MDA and HNE protein adducts, respectively (29). A hydroxyproline assay was performed according to the method of Stegemann and Stalder (30) to assess collagen content. Fluorescence intensity was expressed in arbitrary units of fluorescence per milligram of hydroxyproline. **Pentosidine quantification.** Subcutaneous collagen was used for pentosidine quantification. After homogenization and lipid extraction, 20 mg of collagen pellets were washed twice with phosphate buffer (0.1 mol/l, pH 7.4) and hydrolyzed in 2 ml of HCl 6N, under N₂ atmosphere for 24 h at 110°C in borosilicate tubes with screw caps. After hydrolysis, HCl was evaporated with Modulyo lyophilizer (Edwards Alto Vuoto SpA, Milan, Italy); each sample was reconstituted in water containing 0.01 mol/l heptafluorobutyric acid (Pierce, Prodotti Gianni, Milan, Italy) and filtered through a 0.45- μm pore diameter filter (Ultrafree MC; Millipore, Milan, Italy). Pentosidine was determined in HPLC following the method of Odetti et al. (31).

Morphology. Specimens of renal tissue were fixed in buffered 10% formaldehyde and embedded either in 2-hydroxyethyl-methacrylate (Technovit 7100; Kulzer, Wehrheim, Germany) for morphometric determinations or in Paraplast to identify apoptotic nuclei by means of the transferase-mediated dUTP nick-end labeling (TUNEL) reaction. A custom-made, C-language macro was written to measure the area of glomerular tuft profiles and to count the number of cells within the profiles by means of the Optimas 5.5 (Optimas) image analysis system. The number of cells per unit of glomerular tuft area ($N_a = 1/\mu\text{m}^2$) was used as an indirect measure of cell population density. The areas of at least 100 glomerular tuft profiles per sample were measured; by this method, MGV was estimated from the harmonic mean of the profile areas according to the DeHoff and Rhines formula, as previously described (32).

Apoptotic nuclei on tissue sections were demonstrated by using the POD in situ cell death detection kit (Boehringer Mannheim, Monza, Italy) for the detection of single- and double-stranded DNA breaks by means of the end-labeling TUNEL reaction. Streptavidin-conjugated peroxidase was preferred to alkaline phosphatase for reaction development to avoid interference with the phosphatase-rich renal tissue. The TUNEL results were integrated with morphological evaluation to define apoptotic cells.

CML was identified immunohistochemically in the renal tissue on 4- μm Paraplast sections treated with 0.1% trypsin for 30 min. Endogenous peroxidase activity was quenched by incubation in 0.3% H₂O₂ in PBS for 5 min. Nonspecific binding sites were blocked with 5% BSA diluted in PBS. The sections were incubated overnight at 4°C with a biotinylated mouse monoclonal antibody (Clone no. NF-1G; Wako Chemicals, Neuss, Germany) against CML at a concentration of 4 $\mu\text{g}/\text{ml}$, washed repeatedly with PBS, and incubated with streptavidin-biotinylated horseradish peroxidase (StreptAB-Complex/HRP; Dako, Glostrup, Denmark) for 20 min. 3,3'-Diaminobenzidine/H₂O₂ (Dako) was applied until the reaction product was visualized (~3 min). Specificity was confirmed by applying PBS instead of the antibody or by replacing the antibody with nonimmune serum.

Statistical evaluation. ANOVA and the Tukey-Kramer posttest were used. Analysis of the linear regression line and the relevant coefficient of correlation was performed to assess the fit between parameters. A two-tailed P value was considered significant when <0.05 ; data were expressed as mean \pm SE.

RESULTS

Animals. Streptozotocin induced an abrupt increase in blood glucose to values >14 mmol/l (250 mg/dl). Diabetic animals grew significantly less than CTR, reaching a mean body weight of 440 ± 25 g vs. 600 ± 35 g in CTR ($P < 0.001$) on completion of the experiment. Body weight gain in the diabetic rats treated with TAU, NAC, OXE, or N+T was similar to that of the UD rats (Fig. 1).

Blood glucose values were similar in UD rats and diabetic rats treated with TAU, OXE, NAC, or N+T, up to 21 weeks of age (~2 months after disease onset). Thereafter, all of the treated diabetic groups showed significantly lower blood glucose values than the UD group; Fig. 2A shows the mean blood glucose values of each group between 21 and 40 weeks of age. This observation was

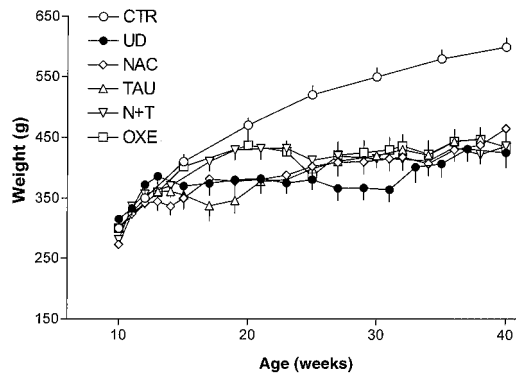


FIG. 1. Increase in body weight in CTR and diabetic rats, untreated or treated with active molecules.

paralleled by the total GHb concentration at the time the rats were killed, with the UD group showing significantly higher mean GHb values than those of all of the treated groups (Fig. 2B).

Subcutaneous tissue. In the UD group, fluorescence at the various wavelengths tested was significantly more intense than in CTR rats (Fig. 3). All treatments except TAU provided partial protection against fluorescent product accumulation, with N+T treatment giving the best results (Fig. 3). Pentosidine accumulation in the skin, as determined by HPLC, showed a similar pattern, being significantly higher in UD rats than in CTR rats. OXE treatment led to a marked abatement of pentosidine content, which decreased to values not significantly different from those of CTR rats; NAC and N+T treatments provided partial protection, whereas in the TAU group, the value was higher than in the UD group (Fig. 4).

Structural changes. The kidneys of the diabetic rats showed severe glycogenesis of the proximal tubules,

thickening of the glomerular basement membrane, and sparse periodic acid Schiff-positive deposits, which were observed mainly in the glomerulus and occasionally within the wall of the afferent arteriole. Mesangial expansion was also detected.

Immunohistochemistry for CML (Fig. 5) showed no staining in the glomeruli of CTR rats, with irregular, low-level positivity in the tubulointerstitial compartment. In UD rats, CML immunostaining was seen in both the glomerular and the tubulointerstitial compartment. In the glomeruli, there was intense, diffuse staining in the mesangium, basement membrane, and Bowman's capsule. The tubular epithelium and basement membrane were also intensely positive. In the interstitial arteries, the intima and the luminal erythrocytes also reacted for CML. Diabetic rats treated with NAC or OXE showed marked reduction of staining for CML in the glomeruli, arterial intima, and erythrocytes. The tubular epithelium showed intermediate positivity between UD and CTR rats. TAU treatment failed to reduce CML immunoreactivity in the glomeruli; staining of glomerular basement membrane and Bowman's capsule was particularly intense. On the contrary, TAU prevented CML immunostaining of erythrocytes of diabetic rats to the same degree of NAC and OXE. Diabetic rats treated with the N+T association showed reduction of CML positivity in the glomeruli similar to that observed with OXE or NAC alone.

Quantitative measurements revealed that MGv was significantly increased in UD rats in comparison with CTR rats. Diabetic rats treated with NAC or OXE showed a significant reduction in MGv in comparison with UD rats; in these groups, MGv values were not significantly different from those of the CTR group. Not only did treatment with TAU fail to prevent the diabetes-associated increase in MGv, but it was also associated with an additional increase in MGv. Treatment with N+T completely prevented the above TAU-related effect and induced a reduction in MGv comparable with that of NAC or OXE treatment (Fig. 6).

The UD group showed significant glomerular cell loss in comparison with the CTR group (data not shown). The combined effect of net glomerular cell loss and glomerular size increase determined a sharp reduction in cell density, i.e., mean number of cells per unit area, in the UD group. Treatment with NAC or OXE partially prevented the reduction in glomerular cell density found in UD rats. TAU treatment was associated with a marked reduction in glomerular cell density, an effect that exceeded that of UD rats. Again, treatment with N+T abated this negative effect of TAU-only treatment and provided protection against the decrease in glomerular cell density associated with diabetes to a similar extent to that of OXE treatment. Glomerular cell density in diabetic rats treated with OXE or N+T did not differ significantly from that of CTR animals (Fig. 7A).

Apoptosis rates showed a reverse pattern. The rate of glomerular apoptosis in UD rats was approximately four times that of CTR. OXE and, to a lesser degree, NAC abated the diabetes-associated rise in apoptosis. In particular, the low apoptosis rate in the OXE group did not differ significantly from that of the CTR group. Diabetic rats treated with TAU showed aggravation of diabetes-related

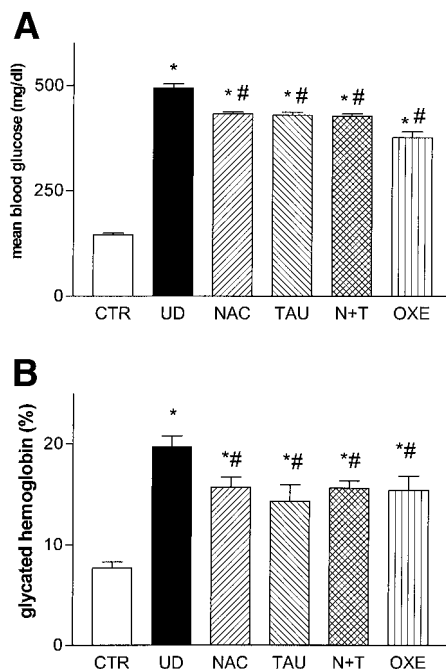


FIG. 2. Mean blood glucose (A: * $P < 0.001$ vs. CTR; # $P < 0.001$ vs. UD) and GHb levels (B: * $P < 0.01$ vs. CTR; # $P < 0.05$ vs. UD) during the observation period in CTR and diabetic rats, untreated or treated with active molecules. Bars represent mean \pm SE.

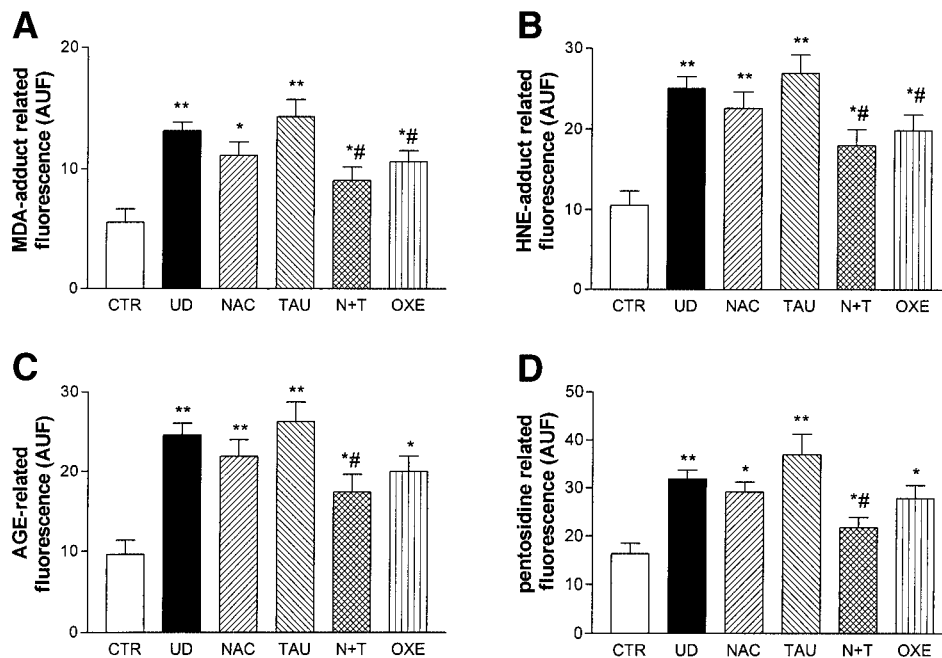


FIG. 3. Levels of fluorescence related to MDA-protein adducts (390 nm EX/460 nm EM; *A*), HNE-protein adducts (356 nm EX/460 nm EM; *B*), AGE (370 nm EX/440 nm EM; *C*), and pentosidine-like products (335 nm EX/385 nm EM; *D*) in CTR and diabetic rats, untreated or treated with active molecules. AUF, arbitrary units of fluorescence; * $P < 0.05$ vs. CTR; ** $P < 0.01$ vs. CTR; # $P < 0.05$ vs. UD.

apoptosis in the glomeruli. Again, this effect was abated in the N+T group, which showed mean values comparable with that of the NAC group (Fig. 7*B*).

Pentosidine concentration in the skin correlated significantly with mean GHb values ($r = 0.440$; $P < 0.002$), MGv ($r = 0.577$; $P < 0.002$), and rate of apoptotic cells ($r = 0.564$; $P < 0.002$). It correlated negatively with cell density ($r = -0.635$; $P = 0.0005$; Fig. 8).

DISCUSSION

NAC, OXE, and TAU, the three drugs being tested in this study, significantly affected the biochemical and morphological parameters that we assessed as biomarkers of damage in diabetic rats. All of the treatments tested produced a significant slight reduction in hyperglycemia and GHb levels in comparison with the UD group. However, because all of the treated diabetic rats were still markedly hyperglycemic, we do not believe that this reduction could have affected the tissue parameters as-

sessed. Moreover, because all antioxidant treatments were started after the development of diabetes, i.e., after virtual completion of β -cell damage, any protection of pancreatic β -cells against streptozotocin by the antioxidants is to be considered improbable.

NAC and OXE provided definite protection against the effects of long-term diabetes on the glomerulus: they drastically reduced CML accumulation, tuft enlargement,

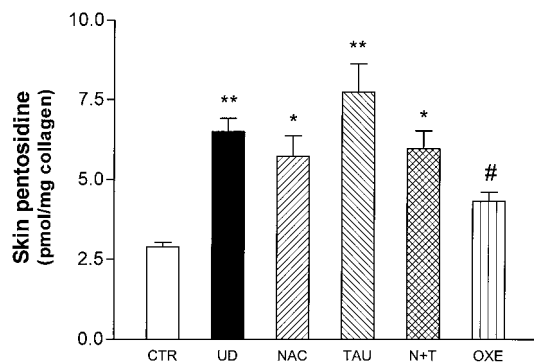


FIG. 4. Quantity of pentosidine per milligram of collagen, evaluated by HPLC in CTR and diabetic rats, untreated or treated with active molecules. * $P < 0.05$ vs. CTR; ** $P < 0.01$ vs. CTR; # $P < 0.05$ vs. UD.

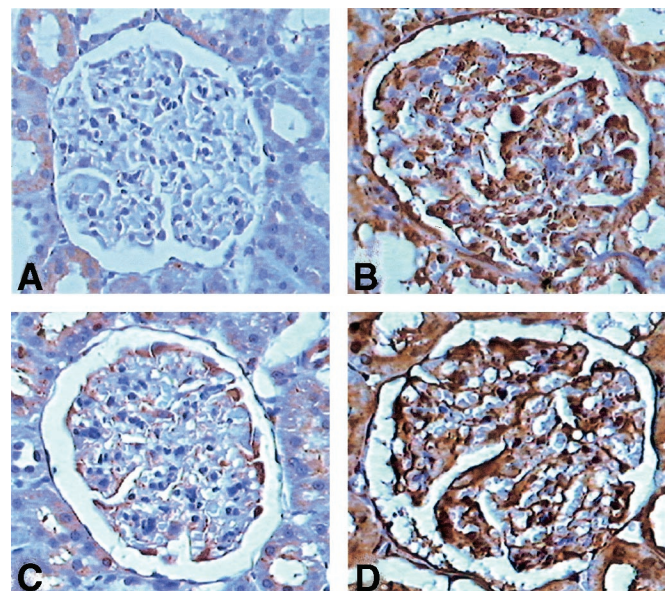


FIG. 5. Immunohistochemical reaction for CML in representative sections of CTR (*A*), UD rats (*B*), N+T treated diabetic rats (*C*), and TAU-treated diabetic rats (*D*). In the glomeruli of UD rats and of TAU-treated diabetic rats, there is intense staining for CML in the mesangium, basement membrane, and Bowman's capsule. The tubular epithelium is also intensely positive. There is no CML staining in CTR rats (*A*); the combined N+T treatment of diabetic rats (*C*) markedly reduces the CML reaction. Magnification $\times 420$.

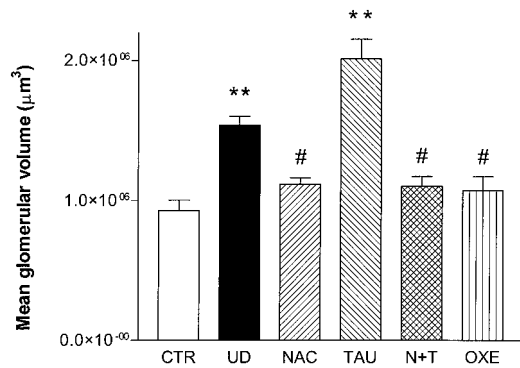


FIG. 6. MGV (μm^3) in CTR and diabetic rats, untreated or treated with active molecules. * $P < 0.05$ vs. CTR; ** $P < 0.01$ vs. CTR; # $P < 0.05$ vs. UD.

cell loss, and rate of apoptosis. In the skin, OXE prevented partially the accumulation of fluorescent protein adducts and of pentosidine, whereas NAC induced only slight, not significant, reductions of these parameters.

Our *in vivo* observations are consistent with the hypothesis that ROS play a pivotal role in apoptosis and that thiol reductants, such as NAC, can block or delay this process (33). Indeed, NAC has been shown to inhibit ROS-induced mesangial apoptosis (34) and to be able to protect cells from glucose-induced inhibition of proliferation (35). Moreover, NAC has been seen to inhibit transforming growth factor- β (TGF- β)-related pathways involved in collagen deposition (36). More recently, NAC proved capable of counteracting the high-glucose-dependent activation of mitogen-activated protein kinase pathways, which are probably involved in the development of microvascular complications of diabetes (37).

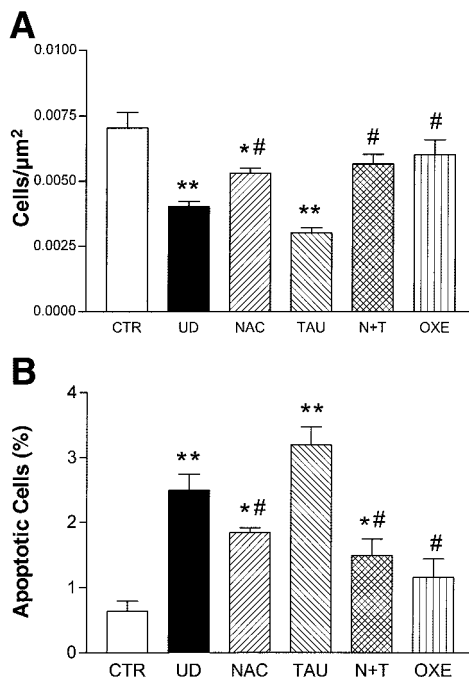


FIG. 7. Cell population density (A) and apoptosis rate (B) within the profiles of the glomerulus in CTR and diabetic rats, untreated or treated with active molecules. The number of cells per unit of glomerular tuft area ($N_a = 1/\mu\text{m}^2$) was used as an indirect measure of cell population density. * $P < 0.05$ vs. CTR; ** $P < 0.01$ vs. CTR; # $P < 0.05$ vs. UD.

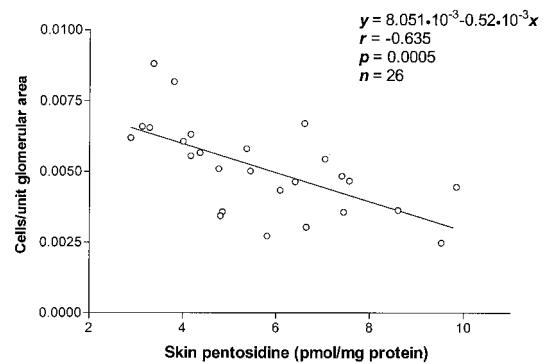


FIG. 8. Correlation between skin pentosidine and cell population density in kidney glomeruli cells. $y = 8.051(10^{-3}) - 0.52(10^{-3})x$; $r = -0.635$; $n = 26$; $P = 0.0005$.

The beneficial effects of NAC on long-term diabetes observed in this study, together with the literature data, indicate a role of NAC-mediated mechanisms in protecting the glomeruli from diabetes-induced disorders. These data indirectly support the observation that glomerular damage in diabetes is associated with the local generation of ROS and AGE deposition.

A novel observation of our study is that administration of a flavonoid, such as OXE, could offer a promising approach to reducing glycoxidation-related damage in diabetes. Indeed, decrease in skin pentosidine concentration and in glomerular CML accumulation, maintenance of MGV, and preservation of glomerular cell number through apoptosis abatement were greatest in OXE-treated diabetic animals.

OXE, which has been studied extensively as a protector in venous hypertension (38), has also aroused attention because of its antioxidant properties: it is able to protect against ROS (39), and, in combination with other antioxidants, has shown the ability to protect against some risk factors for atherosclerosis (40).

Although we are unaware of any studies on the effects of OXE on diabetic complications, inhibition of cataractogenesis has been observed *in vitro* (41); however, several published reports support beneficial effects of flavonoids against diabetic complications (42,43).

In our study, the effects of TAU administration on AGE accumulation in skin and in kidney and on the renal structural changes associated with long-term diabetes were either negligible or negative. This is at variance with some studies, which have shown TAU-dependent partial prevention of diabetic glomerulopathy (44,45). In one of those studies, however, Trachtman et al. (44) failed to demonstrate *in vitro* inhibition of albumin glycation by TAU. Moreover, although diet supplementation with TAU reduced the morphologic damage to the kidney in rats with 12 months of diabetes, it failed to restrain the accumulation of fructoselysine, pentosidine, and carboxymethyllysine in the kidney (45), which is consistent with our immunohistochemical data.

A major point of contrast between our data and those of Trachtman's group is the variation in glomerular size associated with TAU treatment of diabetic rats. Whereas Trachtman et al. (45) reported a reduction in the glomerular planar area in rats with 6 months of diabetes treated with TAU, we found an additional increase in MGV in this

group in comparison with UD rats. However, tissue processing and size calculation protocols were considerably different in these two studies. On the one hand, methacrylate embedding, which is used in our laboratory, minimizes tissue distortion, whereas paraffin embedding, which was used by Trachtman, is associated with considerable size artifacts. On the other hand, glomerular volume estimated from the harmonic mean of glomerular profile areas is a more reliable indicator of size than a simple mean of planar area (32).

We have no conclusive interpretation of the mechanisms implicated in the MGv increase associated with TAU treatment of diabetic rats. One hypothesis is based on the role of this amino acid as an organic osmolyte. Within the physiological pH range, TAU is a zwitterion that penetrates cell membranes (46); in the kidney, TAU works as an osmolyte (47). Although its concentration is normally regulated by proximal tubule reabsorption, TAU concentration increases in the kidney in response to diet supplementation or in pathological conditions such as diabetes (19,45). A rise in glomerular TAU concentration could alter cell volume regulation and induce cell swelling. The subsequent increase in lysosomal pH may account for the inhibition of the proteolysis of growth factors, such as TGF- β (48); this may lead to the increased formation of extracellular matrix (49). Another hypothesis is that the effect of an increased concentration of TAU could have negative effects because the antioxidant activity of TAU is not complete and its chloramine derivative is still a weak oxidant (50).

The negative effects of TAU administration were suppressed by the combined N+T treatment protocol. Indeed, N+T provided significant protection against several of the parameter assessed in the skin and in the kidney. We postulate that NAC inhibits the residual oxidative activity of taurine chloramine. Accordingly, TAU might exert a positive effect only in association with a chaperon molecule such as NAC.

The concomitant protection against glomerular CML accumulation and glomerular apoptosis exhibited by NAC, OXE, and N+T suggests the possibility that glycoxidation and cell regulation in the glomerulus are related. A corollary observation was that all treatments, including TAU only, markedly reduced CML accumulation in erythrocytes. This discrepancy between kidney and erythrocytes for the effects of TAU treatment on CML accumulation could be related to the affinity of the drug for the renal tissue (45) and to the different cell and matrix turnover of the relevant structures. A pertinent consideration is that TAU treatment reduced GHb levels in diabetic rats. Finally, it is worth noting that the level of fluorescent products in the skin correlated with the structural changes in the kidney; skin pentosidine, a recognized marker of AGE accumulation, also turned out to be a reliable index of kidney morphological damage.

In conclusion, we believe that our study provides valuable information that supports the possibility of preventing—or at least attenuating—glomerular damage in diabetes by diet supplementation with specific antioxidants; diabetic nephropathy might be delayed or slowed down by such treatments. The slight decrease in mean glycemic levels that we observed in the treated diabetic

rats in comparison with the UD group, although significant, in our opinion is sufficient neither to account for the reduction of fluorescence and pentosidine accumulation in the skin nor to provide the protection against the glomerular damage observed in all treated groups except TAU; moreover, if the reduction of hyperglycemia had been the only cause of such protection, then even TAU treatment would have proved useful, which was not the case. We suggest that the antioxidant-mediated protection against diabetes-dependent damage is the consequence of global beneficial effects of the antioxidant treatments on the metabolic balance (which is testified to by the reduced hyperglycemia) and on the tissue glycoxidative modifications (which is testified to by the restricted accumulation of fluorescence and pentosidine in the skin). It is conceivable that TAU was not able to provide beneficial effects because of either residual oxidant properties of TAU derivatives (50) or unfavorable osmotic side effects in the kidney. The observation that N+T led to some of the best results suggests that associating antioxidants may be a useful procedure in the trials for protection against diabetes-dependent nephropathy. Further investigation is needed to discover the best associations and the best ratios between the dosages of the different antioxidants.

ACKNOWLEDGMENTS

This work was supported by a grant from University of Genova, MIUR Cofin 2001 no. 2001064293-005, and FIRB 2002 Coord. Scient. Naz. Prof. G. Poli. We thank Dr. A.L. Furfaro for help in the immunohistochemistry experiments.

REFERENCES

1. Monnier VM, Bautista O, Kenny D, Sell DR, Fogarty J, Dahms W, Cleary PA, Lachin J, Genuth S: Skin collagen glycation, glycoxidation, and crosslinking are lower in subjects with long-term intensive versus conventional therapy of type 1 diabetes: relevance of glycated collagen products versus HbA1c as markers of diabetic complications. DCCT Skin Collagen Ancillary Study Group. *Diabetes Control and Complications Trial. Diabetes* 48:870–880, 1999
2. Kislinger T, Fu C, Huber B, Taguchi A, Yan SD, Hofmann M, Yan SF, Pischetsrieder M, Stern D, Schmidt AM: N-(carboxymethyl)lysine adducts of proteins are ligands for receptor for advanced glycation end products that activate cell signalling pathways and modulate gene expression. *J Biol Chem* 274:31740–31749, 1999
3. Scivittaro V, Ganz MB, Weiss MF: AGE induce oxidative stress and activate protein kinase C- β (II) in neonatal mesangial cells. *Am J Physiol* 278:F676–F683, 2000
4. Heilig CV, Riser B, Sastry S, Cortes P: Identification of facilitative glucose transporters in mesangial cells. *J Am Soc Nephrol* 3:758, 1992
5. Chin E, Zama AM, Landau D, Gronbeck H, Flyvbjerg A, LeRoith D, Bondy CA: Changes in facilitative glucose transporter messenger ribonucleic acid levels in the diabetic rat kidney. *Endocrinology* 138:1267–1275, 1997
6. Beisswenger PJ, Moore LL, Brink-Johnsen T, Curphey TJ: Increased collagen-linked pentosidine levels and advanced glycosylation end products in early diabetic nephropathy. *J Clin Invest* 92:212–217, 1993
7. Horie K, Miyata T, Maeda K, Miyata S, Sugiyama S, Sakai H, Strihou CY, Monnier VM, Witztum JL, Kurokawa K: Immunohistochemical co-localization of glycoxidation products and lipid peroxidation products in diabetic renal glomerular lesions: implication for glycoxidative stress in the pathogenesis of diabetic nephropathy. *J Clin Invest* 100:2995–3004, 1997
8. Li YM, Steffes M, Donnelly T, Liu C, Fuh H, Basgen J, Bucala R, Vlassara H: Prevention of cardiovascular and renal pathology of aging by the advanced glycation inhibitor aminoguanidine. *Proc Natl Acad Sci U S A* 93:3902–3907, 1996
9. Kern TS, Engerman RL: Pharmacological inhibition of diabetic retinopathy: aminoguanidine and aspirin. *Diabetes* 50:1636–1642, 2001
10. Aruoma OI, Halliwell B, Hoey BM, Butler J: The antioxidant action of

- N-acetylcysteine: its action with hydrogen peroxide, hydroxyl radical, superoxide and hypochlorous acid. *Free Radic Biol Med* 6:593-597, 1989
11. Aluigi MG, De Flora S, D'Agostini F, Albini A, Fassina G: Antiapoptotic and antigenotoxic effects of N-acetylcysteine in human cells of endothelial origin. *Anticancer Res* 20:3183-3187, 2000
 12. Cabassi A, Dumont EC, Girouard H, Bouchard JF, Le Jossec M, Lamontagne D, Besner JG, de Champlain J: Effects of chronic N-acetylcysteine treatment on the actions of peroxynitrite on aortic vascular reactivity in hypertensive rats. *J Hypertens* 19:1233-1244, 2001
 13. Sagara M, Satoh J, Wada R, Yagihashi S, Takahashi K, Fukuzawa M, Muto G, Muto Y, Toyota T: Inhibition of development of peripheral neuropathy in streptozotocin-induced diabetic rats with N-acetylcysteine. *Diabetologia* 39:263-269, 1996
 14. Rice-Evans C: Flavonoid antioxidants. *Curr Med Chem* 8:797-807, 2001
 15. Hanasaki Y, Ogawa S, Fukui S: The correlation between active oxygen scavenging and antioxidative effects of flavonoids. *Free Radic Biol Med* 16:845-850, 1994
 16. Okuda J, Miwa I, Inagaki K, Horie T, Nakayama M: Inhibition of aldose reductases from rat and bovine lenses by flavonoids. *Biochem Pharmacol* 31:3807-3822, 1982
 17. Krupinski K, Giedrojć J, Bielawiec M: Effect of troxerutin on laser-induced thrombus formation in rat mesenteric vessels, coagulation parameters and platelet function. *Pol J Pharmacol* 48:335-339, 1996
 18. Asgary S, Naderi G, Sarrafzadegan N, Ghassemi N, Bostham M, Rafie M, Arefian A: Anti-oxidant effect of flavonoids on hemoglobin glycosylation. *Pharm Acta Helv* 73:223-226, 1999
 19. Wright CE, Tallan HH, Lin YY: Taurine: biological update. *Annu Rev Biochem* 55:427-453, 1986
 20. Devamanoharan PS, Ali AH, Varma SD: Prevention of lens protein glycation by taurine. *Mol Cell Biochem* 177:245-250, 1997
 21. Tanji N, Markowitz GS, Fu C, Kislinger T, Taguchi A, Pischetsrieder M, Stern D, Schmidt AM, D'Agati VD: Expression of advanced glycation end products and their cellular receptor RAGE in diabetic nephropathy and nondiabetic renal disease. *J Am Soc Nephrol* 11:1656-1666, 2000
 22. Fu MX, Requena JR, Jenkins AJ, Lyons TJ, Baynes JW, Thorpe SR: The advanced glycation end product, Nepsilon-(carboxymethyl)lysine, is a product of both lipid peroxidation and glycoxidation reactions. *J Biol Chem* 271:9982-9986, 1996
 23. Mauer SM, Steffes MW, Ellis EN, Sutherland DE, Brown DM, Goetz FC: Structural-functional relationships in diabetic nephropathy. *J Clin Invest* 74:1143-1155, 1984
 24. Kuan C-J, Al-Douahji M, Shankland SJ: The cyclin kinase inhibitor p21WAF1, CIP1 is increased in experimental diabetic nephropathy: potential role in glomerular hypertrophy. *J Am Soc Nephrol* 9:986-993, 1998
 25. Pesce C, Menini S, Pricci F, Favre A, Leto G, DiMario U, Pugliese G: Glomerular cell replication and cell loss through apoptosis in experimental diabetes mellitus. *Nephron* 90:484-488, 2001
 26. Odetti P, Travero N, Cosso L, Noberasco G, Pronzato MA, Marinari UM: Good glycaemic control reduces oxidation and glycation end-products in collagen of diabetic rats. *Diabetologia* 39:1440-1447, 1996
 27. Monnier VM, Kohn RR, Cerami A: Accelerated age-related browning of human collagen in diabetes mellitus. *Proc Natl Acad Sci U S A* 81:583-587, 1984
 28. Sell DR, Monnier VM: Isolation, purification and partial characterization of novel fluorophores from aging human insoluble collagen-rich tissue. *Connect Tissue Res* 19:77-92, 1989
 29. Chiarpotto E, Scavazza A, Leonarduzzi G, Camandola S, Biasi F, Teggia PM, Garavoglia M, Robecchi A, Roncari A, Poli G: Oxidative damage and transforming growth factor beta 1 expression in pretumoral and tumoral lesions of human intestine. *Free Radic Biol Med* 22:889-894, 1997
 30. Stegemann H, Stalder K: Determination of hydroxyproline. *Clin Chim Acta* 18:267-273, 1967
 31. Odetti P, Fogarty J, Sell DR, Monnier VM: Chromatographic quantitation of plasma and red blood cell pentosidine in diabetic and uremic subjects. *Diabetes* 41:153-159, 1992
 32. Pesce C: Glomerular number and size: facts and artefacts. *Anat Rec* 251:66-71, 1998
 33. Kannan K, Jain SK: Oxidative stress and apoptosis. *Pathophysiology* 7:153-163, 2000
 34. Tashiro K, Makita Y, Shike T, Shirato I, Sato T, Cynshi O, Tomino Y: Detection of cell death of cultured mouse mesangial cells induced by oxidized low-density lipoprotein. *Nephron* 82:51-58, 1999
 35. Park SH, Choi HJ, Lee JH, Woo CH, Kim JH, Han HJ: High glucose inhibits renal proximal tubule cell proliferation and involves PKC, oxidative stress, and TGF-beta 1. *Kidney Int* 59:1695-1705, 2001
 36. Studer RK, Craven PA, DeRubertis FR: Antioxidant inhibition of protein kinase C-signaled increases in transforming growth factor-beta in mesangial cells. *Metabolism* 46:918-925, 1997
 37. Wilmer WA, Dixon CL, Hebert C: Chronic exposure of human mesangial cells to high glucose environments activates the p38 MAPK pathway. *Kidney Int* 60:858-871, 2001
 38. Belcaro G, Rulo A, Candiani C: Evaluation of the microcirculatory effects of Venoruton in patients with chronic venous hypertension by laser Doppler flowmetry, transcutaneous PO2 and PCO2 measurements, leg volumetry and ambulatory venous pressure measurements. *Vasa* 18:146-151, 1989
 39. Shukla VK, Sethi AK, Garg SK, Ganguly NK, Kulkarni SK: Effect of venoruton on hypoxic stress-induced neurotoxicity in mice and oxygen free radical generation by human neutrophils. *Arch Int Pharmacodyn Ther* 299:127-133, 1989
 40. Olszewski AJ, Szostak WB, Bialkowska M, Rudnicki S, McCully KS: Reduction of plasma lipid and homocysteine levels by pyridoxine, folate, cobalamin, choline, riboflavin, and troxerutin in atherosclerosis. *Atherosclerosis* 75:1-6, 1989
 41. Kilic F, Bhardwaj R, Trevithick JR: Modelling cortical cataractogenesis. XVIII. In vitro diabetic cataract reduction by venoruton: a flavonoid which prevents lens opacification. *Acta Ophthalmol Scand* 74: 372-378, 1996
 42. Lim SS, Jung SH, Ji J, Shin KH, Keum SR: Synthesis of flavonoids and their effects on aldose reductase and sorbitol accumulation in streptozotocin-induced diabetic rat tissues. *J Pharm Pharmacol* 53:653-668, 2001
 43. Exner M, Hermann M, Hofbauer R, Kapiotis S, Quehenberger P, Speiser W, Held I, Gmeiner BM: Genistein prevents the glucose autooxidation mediated atherogenic modification of low density lipoprotein. *Free Radic Res* 34:101-112, 2001
 44. Trachtman H, Futterweit S, Prenner J, Hanon S: Antioxidants reverse the antiproliferative effect of high glucose and advanced glycosylation end products in cultured rat mesangial cells. *Biochem Biophys Res Commun* 199:346-352, 1994
 45. Trachtman H, Futterweit S, Maesaka J, Ma C, Valderrama E, Fuchs A, Tarectecan AA, Rao PS, Sturman JA, Boles TH, Fu MX, Baynes J: Taurine ameliorates chronic streptozotocin-induced diabetic nephropathy in rats. *Am J Physiol* 269:F429-F438, 1995
 46. Trachtman H, Lu P, Sturman JA: Immunohistochemical localization of taurine in rat renal tissue: studies in experimental disease states. *J Histochem Cytochem* 41:1209-1216, 1993
 47. Nakanishi T, Uyama O, Sugita M: Osmotically regulated taurine content in rat renal inner medulla. *Am J Physiol* 261:F957-F962, 1991
 48. Waldegger S, Steuer S, Rislis T, Heidland A, Capasso G, Massry S, Lang F: Mechanisms and clinical significance of cell volume regulation. *Nephrol Dial Transplant* 13:867-874, 1998
 49. Morocutti A, Earle KA, Rodemann HP, Viberti GC: Premature cell ageing and evolution of diabetic nephropathy. *Diabetologia* 40:244-246, 1997
 50. Carr AC, Hawkins CL, Thomas SR, Stocker R, Frei B: Relative reactivities of N-chloramines and hypochlorous acid with human plasma constituents. *Free Radic Biol Med* 30:526-536, 2001