

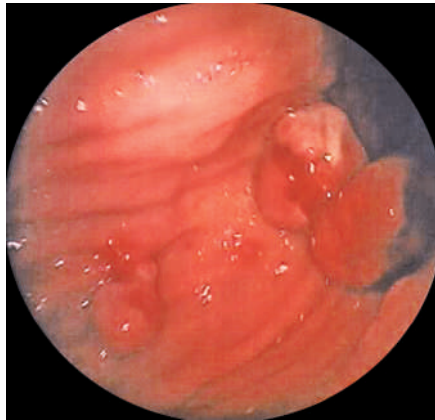Figure 1 Endoscopic view of bleeding polypoid lesions in the stomach.

Metastatic tumors of the stomach are very rare. We report here a case of successful endoscopic treatment of gastrointestinal hemorrhage from gastric metastases of a renal cell carcinoma (RCC), 5 years after radical resection.

A 78-year-old man was admitted because of anemia. His medical history was noteworthy for radical resection of an RCC 5 years earlier. Upper gastrointestinal endoscopy showed three actively bleeding polypoid lesions of 2–3 cm within the body of the stomach (Figure 1). The polyps were removed by electrosurgical snare resection after injection of epinephrine solution in the stalk. No further bleeding was observed after the procedure.

Unexpectedly, at histological examination of the polyps, clear cells were seen, suggesting a metastasis of an RCC (Figure 2). The patient was referred to the oncology department and died 6 months later but he did not present other bleeding episodes during that period.

The incidence of metastatic involvement of the stomach is extremely low (0.2%–0.7%) even in autopsy studies [1–2]. The majority of the patients described had an ulcer-like bleeding lesion and were treated with embolization [3], with epinephrine injection [4], or surgically [2]; we are not aware of any other report of endo-

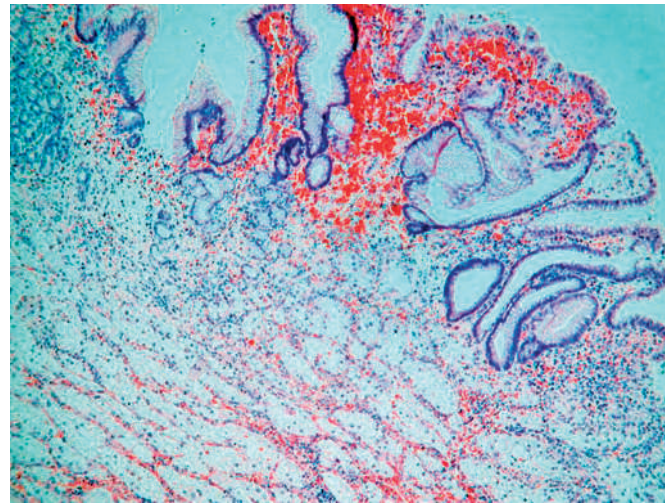


Figure 2 Histological examination showing clear cell kidney carcinoma associated with gastric mucosa (hematoxylin and eosin; × 140).

scopic resection of gastric metastases. We performed this procedure because our patient's lesions looked like bleeding polyps and we did not suspect their histological nature. Nevertheless this treatment was effective in stopping the bleeding, and we avoided surgical resection in this patient with disseminated RCC and at high operative risk. For patients with metastatic gastric tumors, surgical resection is still recommended in selected cases as an effective palliation [2–5], but endoscopic therapy of these lesions seems a reasonable option for those patients not eligible for surgery, as was shown in our patient.

Endoscopy_UCTN_Code_CCL_1AB_2AD_3AB

A. Pezzoli, V. Matarese, S. Boccia, L. Simone, S. Gullini

Department of Gastroenterology and Gastrointestinal Endoscopy, University Hospital, Ferrara, Italy.

References

- Linda K. Hematogenous metastasis to the stomach. *Cancer* 1990; 65: 1596–1600
- Kobayashi O, Murakami H, Yoshida T et al. Clinical diagnosis of metastatic gastric tumors: clinicopathologic findings and prognosis on nine patients in a single cancer center. *World J Surg* 2004; 28: 548–551
- Blake M, Owens A, O'Donoghue DP, MacErlan DP. Embolotherapy for massive upper gastrointestinal haemorrhage secondary to metastatic renal cell carcinoma: report of three cases. *Gut* 1995; 37: 835–837
- Picchio M, Paoletti A, Santini E et al. Gastric metastasis from renal cell carcinoma fourteen years after radical nephrectomy. *Acta Chir Belg* 2000; 100: 228–230
- Ihde JK, Coit DG. Melanoma metastatic to stomach, small bowel, or colon. *Am J Surg* 1991; 162: 208–211

Corresponding author

A. Pezzoli, MD

Department of Gastroenterology and Gastrointestinal Endoscopy
University Hospital Sant'Anna
Corso Giovecca 203
44100 Ferrara
Italy
Fax: +39-05-32236932
Email: a.pezzoli@ospfe.it