

Atypical epigastric pain: Case Report

Fabio Pulighe^{1*}, Gian Pietro Gusai¹ and Alejandro Serrablo Requejo²

¹Ospedale San Francesco, Nuoro, Italy

²Hospital Miguel Servet, Zaragoza, Spain

Case report

A 23-year-old man, with no history of medical or surgical disease arrive to our hospital with the presence of epigastric abdominal pain after a car accident. On examination, he was afebrile with an epigastric localized visceral pain and mild tenderness in the same area. His laboratory studies showed normal level of haemoglobin, white blood cell count of 14,400/mm³ with 86% neutrophils and a C-reactive protein of 11.6 mg/ dL.

The patient was then submitted to a CT scan (Figure 1) that showed a large, irregularly shaped deep ulceration on the second duodenum (Figure 2). What is the most likely diagnosis and hoe should it be managed?

Discussion

The patient was then submitted to ad urgent surgery and treated with a complete gastric exclusion performed with Billroth II gastro-enteric bypass, suture of duodenum and bilious exclusion with positioning of Kehr drainage (Figure 3).

The patient had uneventful postoperative course and was discharged at twelve postoperative day. I was then submitted to a Kehr removal after 1 month later.

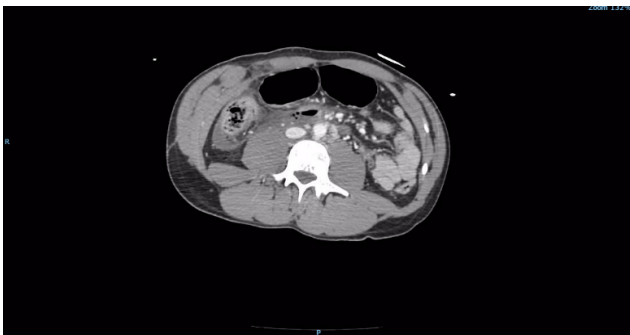

Figure 1. Duodenal Trauma – 1

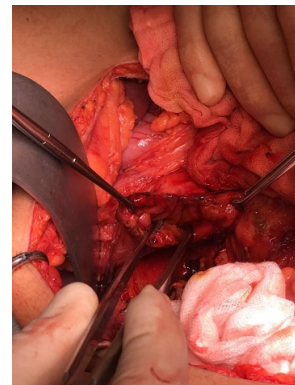


Figure 2. Duodenal Trauma – 2

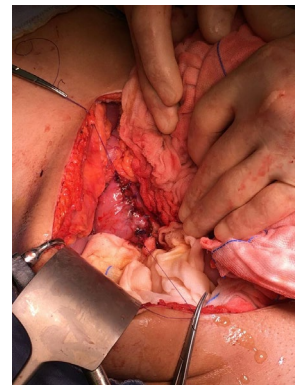


Figure 3. Duodenal Trauma - 3

Conflict of Interest

Fabio Pulighe and Gian Pietro Gusai contributed to the writing of the text.

Prof. Serrablo contributed to the revision and correction of English

The authors declare no conflict of interest

Copyright: ©2020 Pulighe F. This is an open-access article distributed under the terms of the Creative Commons Attribution License, which permits unrestricted use, distribution, and reproduction in any medium, provided the original author and source are credited.

***Correspondence to:** Fabio Pulighe, Ospedale San Francesco, Nuoro, Italy, E-mail: fabiopulighe@gmail.com

Received: February 01, 2020; **Accepted:** February 11, 2020; **Published:** February 14, 2020