

## Proposal for bail-out procedures - Vascular thoracic Ruptured aortic arch aneurysm: transposition of aortic arch branches after insertion of thoracic endovascular stent with extra-anatomic brain perfusion

Roberto Coppola<sup>a</sup>, Raffaele Bonifazi<sup>a,\*</sup>, Marco Gucciardo<sup>a</sup>, Paolo Pantaleo<sup>b</sup>

<sup>a</sup>Department of Cardiac Surgery, Villa Azzurra Hospital, Via Ernesto Cabrana, 21 – 16035 Rapallo (Ge), Italy

<sup>b</sup>Department of Interventional Cardiology, Villa Azzurra Hospital, Via Ernesto Cabrana, 21 – 16035 Rapallo (Ge), Italy

Received 28 November 2006; received in revised form 27 January 2007; accepted 31 January 2007

### Abstract

Conventional surgical treatment of a ruptured aortic arch aneurysm is a challenging approach with a high rate of adverse outcomes. The midsternotomy can be complicated by total aortic disruption with often fatal massive hemorrhage. A preliminary cardiopulmonary bypass with peripheral cannulation and cooling is often preferred. Endovascular stents have been used in patients with thoraco-abdominal aneurysms, with good results. Its lone utilization for rupture of aortic arch aneurysm is not feasible because of the unavoidable occlusion of cerebral vessels' origins. A previous aorto-bicarotid bypass is mandatory and it requires the midsternotomy. Hence, we developed a combined technique. We performed a hybrid approach in a 74-year-old patient, affected by an aortic arch aneurysm, ruptured in its antero-inferior portion. First we ensured brain perfusion with a temporary surgical extra-anatomic (femoral-bicarotid) bypass. Then an endovascular stent graft was expanded from the distal portion of ascending aorta to the proximal one of the thoracic aorta, thus excluding the ruptured portion of the aortic arch. Then the patient underwent the definitive aorto-carotid bypass. This specific combined technique allows the complete treatment of a ruptured arch aneurysm, lowering the risks connected with sternothomic approach, mainly with previous cardiopulmonary bypass and deep hypothermic circulatory arrest.

© 2007 Published by European Association for Cardio-Thoracic Surgery. All rights reserved.

**Keywords:** Aortic arch aneurysm; Aortic dissection; Endovascular stent; Aorto-carotid bypass; Endovascular treatment; Cardiac surgery

### 1. Introduction

Rupture of an aortic arch aneurysm (AAA) is a serious, life-threatening event requiring an emergency treatment. Conventional technique is the surgical replacement of ascending aorta and aortic arch. In some cases, because of the particular anatomy (false aneurysm adjacent to the overlying sternum), there exists a significant risk of massive hemorrhage during sternotomy. The risk is higher for redo surgery, but in literature are described cases of fatal and total aortic rupture even for patients undergoing first surgical intervention [1]. This major complication is associated with a high mortality. Its management requires extramediastinal cannulation and deep hypothermia (DH). Cardiopulmonary bypass (CB) and cooling before sternal entry would ensure time and exposure to control bleeding, but circulatory arrest (CA) or low-flow state can be unavoidable [2, 3]. CB, DH and CA are associated with a high morbidity rate because of neurological, renal and pulmonary adverse outcomes [4, 5].

Recently, the introduction of endovascular stents in the treatment of thoracic and abdominal aneurysms of the aorta has resulted, and is associated with a lower mortality

and morbidity than surgery [6]. Its application in the case of ruptured aneurysms could be promising allowing to exclude the damaged portion of the aortic wall but, obviously, lone stent insertion is not feasible in the aortic arch because of the origin of cerebral vessels. A combined approach is then required [7–10].

We describe a technique to ensure brain perfusion with extra-anatomical grafting during endostent expansion, in the case of a ruptured aortic arch aneurysm (judged at high risk of acute bleeding during sternotomy), followed by aortic arch branch transposition in off-pump, without requiring pre-operative femoro-femoral bypass DH and CA.

### 2. Patient

A 74-year-old man with hypertension, diabetes mellitus type II, chronic pulmonary disease and dysphonia for 4–5 months presented with chest pain. A first spiral computed tomography (CT) showed an AAA (4.5 cm) with parietal thrombosis. One month later a new CT was performed, showing worsening of AAA: increase of dimensions (6.5 cm) and rupture (pseudoaneurysm) limited to the proximal portion and to the anterior aortic wall. The exam did not reveal aneurysmatic involvement of the supra-aortic vessels.

\*Corresponding author. Tel.: +39-0185-21311; fax: +39-0185-260973.

E-mail address: bgiava@tin.it (R. Bonifazi).

### 3. Technique

In the hemodynamic laboratory, after achievement of general anesthesia and moderate heparinization (ACT levels: 250–300 s), the left common femoral artery (CFA) and the right and left common carotid artery (CCA), were surgically exposed. Three Dacron conduits (8 mm) were anastomosed to each vessel. The Dacron prosthesis was connected (Y shape) using a Sylastic conduit. The CCAs were proximally clamped (to avoid flow competition which could be responsible of an intra-graft clotting), appreciating a good pulsation distally to the anastomoses (perfusion from CFA) and monitoring for each carotid artery, an adequate blood pressure (mean arterial pressure 60–70 mmHg) through needles 22 G directly inserted into the vessels with continuous blood pressure monitorization (Fig. 1).

After having established this temporary femoral-bicarotid bypass, the endovascular stent graft system (Zenith Thoracic Endovascular Graft) was inserted through the right femoral artery. It was expanded from the distal portion of the ascending aorta to the proximal portion of the thoracic aorta. Angiography documented the correct positioning of the vascular stent and revealed no residual endoleak.

The patient was then transferred to the operating room. Median sternotomy was uneventful. After the exposure of the aorta and partial clamping in its ascending portion, a Dacron graft (8 mm) was anastomosed. The distal end of the graft was anastomosed (end to end) to the brachiocephalic trunk and this was proximally ligated. A second Dacron graft (8 mm) was sutured to the first one creating a Y graft (proximal end) and then was anastomosed to the left carotid artery (distal end). The left carotid artery was ligated to the origin (Fig. 2).

Finally, we removed the previous femoral-bicarotid bypass.

### 4. Results

The patient had an uneventful postoperative course. He was extubated on the first postoperative day. There were no cerebrovascular, renal or respiratory complications. No

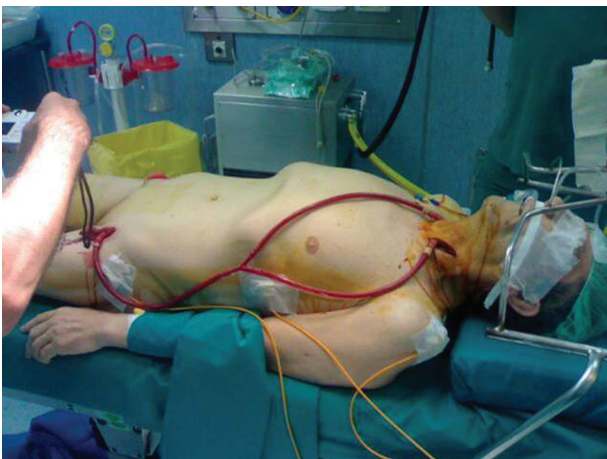

Fig. 1. The patient in hemodynamic laboratory. A view of the extra-anatomical femoro-bicarotid conduit.

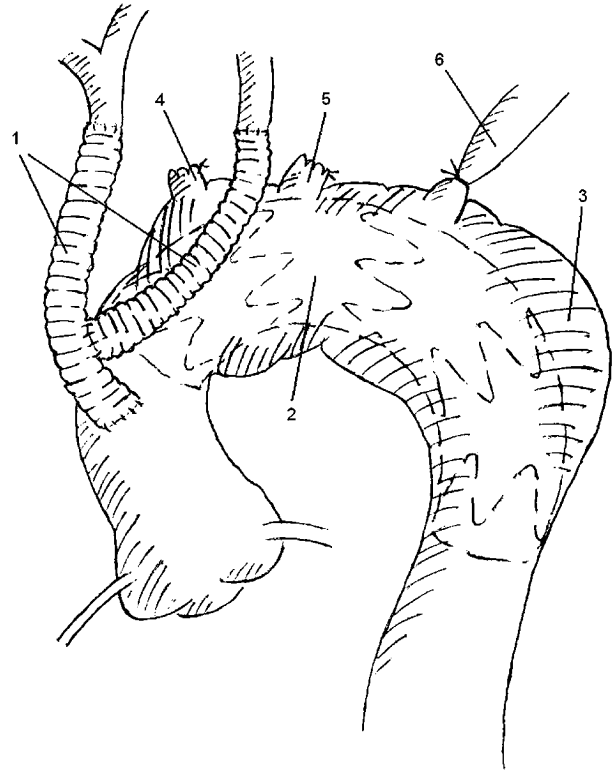


Fig. 2. The picture shows the aorto-bicarotid bypass and the position of endostent. 1, Aorto-carotid bypass; 2, Endovascular stent; 3, Ruptured aortic arch aneurysm; 4, Brachiocephalic trunk; 5, Left carotid artery; 6, Left subclavian artery.

supranormal bleeding was detected (overall bleeding was 450 cc). The patient was discharged on postoperative day eight.

A CT scan after one week showed correct positioning of the endostent, with complete exclusion of the aneurysm and its total thrombosis; no back flow from the left subclavian artery was detected.

### 5. Discussion

Surgical correction of a ruptured aortic arch is a challenging procedure. Conventional surgical approach is commonly related to many serious complications. Among these, the total aneurysm rupture during sternal entry is often fatal. Even if controlled, it would require an emergent beginning of femoro-femoral CPB and deep hypothermic circulatory arrest or bilateral carotid cannulation. Some authors suggest to begin cardiopulmonary bypass and cooling before opening the sternum.

In literature there are no series about rupture of pseudoaneurysms of the thoracic aorta or of the aortic arch during sternotomy at the time of first intervention, but there are isolated reports. In a case estimated at high risk of acute rupture we have chosen a hybrid technique.

Utilization of covered endovascular graft in the aortic arch obviously requires the surgical transposition of the supra-aortic branches (SAB). Usually through midsternotomy, the ascending aorta is exposed and anastomosed to SAB. Then the endovascular stent can be positioned through femoral approach or even through the ascending aorta

itself. To avoid the high risks strictly connected in this case with the sternotomic approach, we decided to establish pre-operatively a brain protecting perfusion arising from the common femoral artery. In this way the endovascular stent delivery caused no neurological complications.

Moreover, excluding the aortic ruptured portion with the expanded endostent, the risk of acute and total aortic disruption from the sternotomy result is significantly lowered.

Subsequently, after the uneventful sternal entry, a Y-graft in Dacron was created to connect the aorta to SAB.

This technique allows treatment of an urgent and really serious event to a relatively low operative risk, without the use of cardiopulmonary bypass. The entire technique appears relatively invasive however, ensuring a complete treatment of the aortic arch disease.

## References

- [1] Pansini S, Gagliardotto PV, Pompei E, Parisi F, Bardi G, Castenetto E, Orzan F, Di Summa M. Early and risk factors in surgical treatment of acute type A aortic dissection. *Ann Thorac Surg* 1998;66:779–784.
  - [2] Villavicencio MA, Orszulak TA, Sundt TM, Daly RC, Dearani JA, McGregor CG, Mullany CJ, Puga FJ, Zehr KJ, Schaff HV. Thoracic aorta false aneurysm: what surgical strategy should be recommended? *Ann Thorac Surg* 2006;82:81–89.
  - [3] Katsumata T, Moorjani N, Vaccari G, Westaby S. Mediastinal false aneurysm after thoracic aortic surgery. *Ann Thorac Surg* 2000;70:547–552.
  - [4] Bickerstaff LK, Pairolo PC, Hollier LH, Melton LJ, Van Peenen HJ, Cherry KJ, Joyce JW, Lie JT. Thoracic aortic aneurysm: a population-based study. *Surgery* 1982;92:1103–1108.
  - [5] Doss M, Balzer J, Martens S, Wood JP, Wimmer-Greinecher G, Fieguth HG, Moritz A. Surgical versus endovascular treatment of acute thoracic aortic rupture: a single center experience. *Ann Thorac Surg* 2003;76:1465–1470.
  - [6] Grabenwöger M, Hutschala D, Ehrlich MP, Cartes-Zumelzu F, Thurnher S, Lammer J, Wolner E, Havel M. Thoracic aortic aneurysm: treatment with endovascular self-expandable stent grafts. *Ann Thorac Surg* 2000;69:441–445.
  - [7] Matalanis G, Durairaj M, Brooks M. A hybrid technique of aortic arch branch transposition and antegrade stent graft deployment for complete arch repair without cardiopulmonary bypass. *Eur J Cardiothorac Surg* 2006;29:611–612.
  - [8] Nitta Y, Tsuru Y, Yamaya K, Akasaka J, Oda K, Tabayashi K. Endovascular flexible stent grafting with arch vessel bypass for a case of aortic arch aneurysm. *J Thorac Cardiovasc Surg* 2003;126:1186–1188.
  - [9] Kato M, Kaneko M, Kuratani T, Horiguchi K, Ikushima H, Ohnishi K. New operative method for distal aortic arch aneurysm: combined cervical branch bypass and endovascular stent-graft implantation. *J Thorac Cardiovasc Surg* 1999;117:832–834.
  - [10] Czerny M, Zimpfer D, Fleck T, Hoffmann W, Schoder M, Cejna M, Stampfl P, Lammer J, Wolner E, Grabenwöger M. Initial results after combined repair of aortic arch aneurysm by sequential transposition of the supra-aortic branches and consecutive endovascular stent-graft placement. *Ann Thorac Surg* 2004;78:1256–1260.
- doi:10.1510/icvts.2006.149260A
- eComment:** The authors presented a very interesting case of contemporary management of aortic arch aneurysm using hybrid technique (a combined surgical and endovascular approach) [1]. The strategy considerably reduces the risk of hemorrhage from the damaged portion of aortic arch and complications associated with cardiopulmonary bypass and hypothermic circulatory arrest. The reported original method allowed the authors to perform surgery avoiding complications, thereby significantly decreasing the length of intensive care and hospital stay with good immediate outcome.
- However, there are some points we would like to be addressed.
- In order to initially define the dangers of sternotomy, that in turn made the authors seek the original decisions, it would be interesting and important to demonstrate the angiographic and CT findings. This would allow for the determination of the local anatomy of the aortic arch aneurysm and its branches as well as its interrelations with ascending and descending parts and the sternum.
  - It is not clear whether or not the mycotic origin of the aneurysm was ruled out, since it is a common source of false aneurysms and ruptured aortic arch aneurysms. This is of central importance as it is known that in case of infected aneurysms it seems more reasonable to establish an extra-anatomic aortic and brachiocephalic bypass. Endovascular repair of the mycotic aneurysms is controversial [2] and may cause adverse septic complications requiring reoperations.
  - The original approach reported by the authors appears attractive, considering its advantages such as avoiding the use of cardiopulmonary bypass and hypothermic circulatory arrest as well as lowering the risk of hemorrhage from the aortic arch aneurysm. On the other hand, there are some disadvantages connected with the use of temporary surgical extra-anatomic bypass (lack of control on brain perfusion parameters; risk of thrombotic complications on account of extended circuit and time-consuming procedures; the need for additional reconstructive carotid surgery and performing the main part of the operative intervention in the state of full heparinization).
- In the last 2 years in the Vascular Department of the Bakoulev Scientific Center of Cardiovascular Surgery, Russian Academy of Medical Sciences, 3 operations were performed in cases of mycotic aneurysms of the aortic arch and descending thoracic aorta using an original method. One patient following endovascular repair of the descending thoracic aorta had developed sepsis, as a result of stent-graft infection. Another patient, who had had salmonella infection, presented with false aortic arch aneurysm with signs of progressive expansion located at the level of origins of the left common carotid artery and subclavian artery. The cause of the mycotic aneurysm in the third case was not identified. In all three patients as a first stage procedure an extra-anatomic ascending-to-descending aortic bypass via right thoracotomy was performed (without the use of cardio-pulmonary bypass) [3]. After that, an adjunct cardio-pulmonary bypass (partial femoro-femoral bypass) was established and via left thoracotomy the aneurysm was exposed and repaired. It was possible to maintain the part of aortic arch and the adjacent brachiocephalic branches in all our cases. Due to this, additional interventions on the aortic arch and its branches were not required. In summary, the problem of surgical repair of the aortic arch aneurysms and their ruptures is vital and the reported method by Roberto Coppola et al. is contemporary, interesting and original. Nevertheless, the existing disadvantages necessitate further trials to optimize the treatment options for this complex group of patients.

## References

- [1] Coppola R, Bonifazi R, Gucciardo M, Pantaleo P. Ruptured aortic arch aneurysm: transposition of aortic arch branches after insertion of thoracic endovascular stent with extra-anatomic brain perfusion. *Interact CardioVasc Thorac Surg* 2007;6:376–378.
- [2] Smith JJ, Taylor PR. Endovascular treatment of mycotic aneurysms of the thoracic and abdominal aorta: the need for level I evidence. *Eur J Vasc Endovasc Surg* 2004;27:569–570.
- [3] Arakelyan V, Spiridonov A, Bockeria L. Ascending-to-descending aortic bypass via right thoracotomy for complex (re-)coarctation and hypoplastic aortic arc. *Eur J Cardiothorac Surg* 2005;27:815–820.

## ICVTS on-line discussion A

**Title:** Commentary to the case study

**Authors:** Leo A. Bockeria, Bakoulev Center for Cardiovascular Surgery, Moscow 121552, Russia; Valery Arakelyan