

# Bipolar Electrocautery

## A Rodent Model of Sunderland Third-degree Nerve Injury

Arash Moradzadeh, MD; Michael J. Brenner, MD; Elizabeth L. Whitlock, BA; Alice Y. Tong, MS; Janina P. Luciano, BS; Daniel A. Hunter, RA; Terence M. Myckatyn, MD; Susan E. Mackinnon, MD

**Objective:** To determine the Sunderland classification of a bipolar electrocautery injury.

**Methods:** Twenty-two rats received crush (a reproducible Sunderland second-degree injury) or bipolar electrocautery injury and were evaluated for functional, histomorphometric, and immunohistochemical recovery at 21 or 42 days. Animal experiments were performed between July 3 and December 12, 2007. Axonal regeneration and end plate reinnervation were evaluated in double transgenic cyan fluorescent protein–conjugated Thy1 and green fluorescent protein–conjugated S100 mice.

**Results:** Compared with crush injury, bipolar electrocautery injury caused greater disruption of myelin and neurofilament architecture at the injury site and decreased

nerve fiber counts and percentage of neural tissue distal to the injury ( $P=.007$ ). Complete functional recovery was seen after crush but not bipolar electrocautery injury. Serial live imaging demonstrated axonal regeneration at week 1 after crush and at week 3 after bipolar electrocautery injury. Qualitative assessment of motor end plate reinnervation at 42 days demonstrated complete neuromuscular end plate reinnervation in the crush group and only limited reinnervation in the bipolar electrocautery group.

**Conclusion:** Bipolar electrocautery injury in a rodent model resulted in a Sunderland third-degree injury, characterized by gradual, incomplete recovery without intervention.

*Arch Facial Plast Surg.* 2010;12(1):40-47

### Author Affiliations:

Department of Otolaryngology–Head & Neck Surgery (Drs Moradzadeh and Mackinnon) and Department of Surgery, Division of Plastic and Reconstructive Surgery (Mss Whitlock, Tong, and Luciano, Mr Hunter, and Drs Myckatyn and Mackinnon), Washington University School of Medicine, St Louis, Missouri; and Department of Surgery, Division of Otolaryngology–Head & Neck Surgery, Southern Illinois University School of Medicine, Springfield (Dr Brenner).

**B**IPOLAR ELECTROCAUTERY, which was originally developed to avoid injury to the central nervous system during neurosurgical procedures,<sup>1</sup> has proven valuable in decreasing the risk of iatrogenic damage to peripheral nerve associated with unipolar cautery.<sup>2</sup> Nonetheless, reconstructive surgeons will occasionally encounter a patient in whom misidentified neural tissue was inadvertently cauterized.

The clinical course of burn injuries to the peripheral nerve is variable because of the heterogeneity of the injuries, influenced by both the intensity and duration of the exposure, as well as the intrinsic properties of the nerve that sustains the injury. Part of the difficulty in managing such injuries regards the relative paucity of experimental research that compares bipolar nerve injury to more thoroughly characterized models of traumatic injury.<sup>3</sup>

Sunderland classified 5 degrees of peripheral nerve injury in a seminal 1951 article.<sup>4</sup> His classification ranged from first degree (neurapraxia), which resulted in a

simple conduction block, to fifth degree, which corresponded to full discontinuity of all nerve components (ie, transection). This classification system has implications for clinical management. For example, a second-degree injury (axonotmesis, as occurs with a crush injury) requires no operative reconstruction; in contrast, a fourth-degree injury (axonotmesis with major disruption of internal structure and near-complete axonal block) mandates surgical excision and reanastomosis to achieve useful recovery. Third-degree injury is perhaps the most ambiguous. Characterized by discontinuity of endoneurial tubes but patent perineurial structure, fiber disorganization may be compounded by intraneural fibrosis and retrograde axonal regeneration. Sunderland describes this injury as having a recovery time longer than that of a second-degree injury and ultimately producing a residual functional deficit; however, operative intervention is neither necessary nor recommended unless it localizes to a known area of nerve compression, in which case a simple nerve decompression is performed.

Seddon<sup>5</sup> described this type of injury as well in his earlier report, where he stated that patients with axonotmetic injuries could recover completely (Sunderland second-degree injury) or incompletely (Sunderland third-degree injury). It is this third-degree injury that is a frequently disputed medicolegal issue; patients with first-degree and second-degree injuries recover completely without damage, whereas fourth-degree and fifth-degree injuries require surgical repair. Patients with third-degree injuries, by contrast, have less than complete recovery and their injuries are associated with a slow rate of recovery that renders the extent of injury and the long-term prognosis indeterminate.

Although some aspects of the pathophysiology of bipolar nerve injury have been reported previously,<sup>6</sup> the quantitative histologic and functional outcomes after sciatic crush vs bipolar electrocautery injury have not been directly compared. Previous research suggests that bipolar electrocautery induces perineurial destruction similar to a Sunderland fourth-degree injury,<sup>6</sup> whereas sciatic crush results in a more limited injury characterized by simple axonotmesis (Sunderland second-degree injury).<sup>3</sup> If bipolar cautery results in a fourth-degree injury, management would require operative resection of the damage and repair of the nerve. This approach is at odds with the usual clinical observation of bipolar electrocautery injuries. A third-degree injury, by contrast, will recover some function spontaneously. Differentiation between these 2 injuries could guide clinical management of iatrogenic bipolar electrocautery nerve injury and also provide a new animal model to investigate potential therapeutic modalities.

The rodent sciatic nerve crush injury model has been used extensively to evaluate nerve regeneration and test various therapeutic modalities. To determine the Sunderland classification of a bipolar electrocautery injury, we compared this injury to a crush injury in both rat and mouse models. Functional and histomorphometric recovery and immunohistochemical staining of nerve tissues were assessed in rats. Fluorescent staining for neuromuscular junctions and serial live imaging of axonal behavior during postinjury regeneration was evaluated in double-transgenic mice with fluorescent chromophores that allow for real-time assessment of axonal elongation and reinnervation.

## METHODS

### EXPERIMENTAL DESIGN

Twenty-two adult male Lewis rats (Harlan Laboratories Inc, Indianapolis, Indiana) underwent either bipolar electrocautery or crush injury to the sciatic nerve. Sixteen of these animals were killed on day 21 for histomorphometric analysis and immunohistochemical staining for neurofilament protein and myelin basic protein. The other 6 animals, 3 per group, were harvested at a 42-day end point for the same immunohistochemical evaluation. Serial walking track measurements were performed weekly for each group until death, thereby providing a measure of functional recovery.

In addition, 6 cyan fluorescent protein (CFP)-conjugated Thy1 and green fluorescent protein (GFP)-conjugated S100

**Table 1. Experimental Design**

End Point, wk	Injury	No.	Evaluation
<b>Rat</b>			
3	Crush	8	Walking track analysis
	Cautery <sup>a</sup>	8	Histomorphometric analysis Immunohistochemical analysis
6	Crush	3	Walking track analysis
	Cautery <sup>a</sup>	3	Immunohistochemical analysis
<b>Mouse</b>			
6	Crush	3	Serial live imaging
	Cautery <sup>a</sup>	3	Neuromuscular junction staining Whole-mount nerve imaging

<sup>a</sup>Refers to bipolar electrocautery injury.

double-transgenic mice were randomly assigned to undergo crush or bipolar electrocautery injury. These mice produce native fluorescence in their axons as a result of the CFP-conjugated Thy1 promoter. Fluorescence is also expressed by their Schwann cells, adipocytes, and some other cell populations as a result of the GFP-conjugated S100 promoter. They have been previously used to image axonal Schwann cell relationships.<sup>7</sup> Mice received serial live imaging to track axonal regeneration and Schwann cell behavior at the injury site. At the 6-week end point, they were evaluated with neuromuscular junction staining and whole-mount imaging of the injured nerve.

**Table 1** summarizes the experimental design.

All animals were housed in a central animal facility and given a rodent diet (PicoLab Rodent Diet 20 5053; Purina Mills Incorporated Nutrition International, St Louis, Missouri) and water ad libitum. Surgical procedures and perioperative care were approved by the Washington University Institutional Animal Studies Committee and performed in strict accordance with National Institutes of Health guidelines. Animal experiments were performed at Washington University School of Medicine from July 3 to December 12, 2007.

### OPERATIVE PROCEDURES

All animals were anesthetized by subcutaneous injection with 75 mg/kg of ketamine hydrochloride (Pfizer Inc, New York, New York) and 0.5 mg/kg of medetomidine hydrochloride (Orion Corporation, Espoo, Finland). The hindquarters were shaved and sterilized with iodine. With the aid of an operating microscope, a gluteal muscle-splitting approach was used to expose the right sciatic nerve. An electrocautery generator connected to a timer (Bard System 5000; DRE Veterinary, Louisville, Kentucky) was used to produce bipolar electrocautery injury. For rats, nerves in the bipolar electrocautery group were subjected to 30 W of current (in coagulation mode) through microbipolar forceps for exactly 1 second. Because of the smaller caliber of the mouse sciatic nerve, less current (15 W) was applied to induce a similar injury. The injury was placed approximately 5 mm proximal to the sciatic trifurcation in both rats and mice. Nerves in the crush group were injured by firm application of the same microbipolar forceps tips without any current for 30 seconds. The proximal and distal extent of visible nerve injury was marked with 10-0 nylon epineurial sutures, and muscle and skin were closed in layers using 6-0 polyglactin and 4-0 nylon sutures, respectively. For postoperative pain control, animals were given 0.01 to 0.05 mg/kg of subcutaneous buprenorphine hydrochloride (Hospira Inc, Lake Forest, Illinois). Anesthesia was reversed with 0.2 mg/kg of atipamezole hydrochloride, and animals were allowed to recover on a heated bed before being returned to a central animal care facility.

For mice receiving serial live imaging, the operative site was reopened on postoperative weeks 1, 2, 3, and 6 in a sterile fashion with mice under anesthesia. With a fluorescence-enabled dissecting microscope, a previously described imaging regimen<sup>7</sup> was used to photograph the sciatic nerve under 488 nm (GFP; Schwann cells) and 450 nm (CFP; axons) fluorescent cubes with a monochromatic charge-coupled device and MetaMorph imaging software (version 6.2; Universal Imaging Corporation, Downingtown, Pennsylvania). Images taken at the 2 wavelengths were merged with Adobe Photoshop (version 7.0; Adobe Systems Inc, San Jose, California). After imaging, the incision was closed, and mice were allowed to recover.

### WALKING TRACKS

As previously described,<sup>8</sup> the hind feet of the rat were coated with x-ray film developer and the rat was allowed to walk down a track covered with exposed, undeveloped x-ray film, producing clear hind footprints. Loss of sciatic nerve function results in unopposed dorsiflexion with corresponding elongation of the print length. The print length factor is a normalized index of this functional impairment and decreases over time as function is restored. The print length factor was determined with the following formula: (experimental print length - normal print length)/normal print length, where experimental print length and normal print length are the measured footprint lengths of experimentally injured feet and healthy, unaffected feet, respectively.

### IMMUNOHISTOCHEMICAL ANALYSIS

Three or 6 weeks after injury, animals whose tissue would be used for immunohistochemical analysis were reanesthetized and underwent intracardiac perfusion with phosphate-buffered saline with heparin and 4% paraformaldehyde. The operative incision was reopened and the injury site was harvested, along with a 5- to 6-mm length of nerve proximal and distal to the site of injury. The extensor digitorum longus muscle was also harvested whole from mice in this study.

For nerve immunohistochemical analysis, which was performed for some rats, resected nerve segments were snap frozen in optimal cutting temperature compound after overnight fixation in cold buffered 4% paraformaldehyde. Next, 15- $\mu$ m longitudinal cryosections were obtained from the injured site by use of a cryostat (Leitz Cryostat 1720, Wetzlar, Germany). Sections were immunolabeled with rabbit anti-human myelin basic protein polyclonal antibody (Chemicon AB980; Millipore, Billerica, Massachusetts) followed by an Alexa 488-conjugated secondary antibody and mouse monoclonal anti-pan-axonal neurofilament (SMI312; Covance, Princeton, New Jersey) followed by a Cy3-conjugated secondary. Using a fluorescent microscope at 488 nm for myelin basic protein and 594 nm for neurofilament, we examined images at  $\times 600$  magnification.

For labeling of neuromuscular junctions, whole mounts of mouse extensor digitorum longus muscle were soaked for 30 minutes in a solution with  $\alpha$ -bungarotoxin (1  $\mu$ g/mL; Life Technologies Corporation, Carlsbad, California) conjugated to Alexa 594 fluorophores, then thoroughly washed with phosphate-buffered saline. Fluorescent components were imaged using a confocal microscope (Fluoview FV1000; Olympus Corporation, Tokyo, Japan) with lasers at 488 nm for Schwann cells (S100-GFP), 450 nm for axons (Thy1-CFP), and 594 nm for neuromuscular junctions ( $\alpha$ -bungarotoxin-Alexa 594). Whole-mount nerves were imaged at 450 nm to detect a Thy1-CFP signal.

### HISTOMORPHOMETRIC ANALYSIS

At the 3-week end point, those animals whose sciatic nerve would be evaluated with quantitative histomorphometric analysis were reanesthetized, the operative incision was reopened, and the sciatic injury site was harvested in continuity with a 1-cm segment of tibial nerve distal to the sciatic trifurcation. Resected nerve segments were fixed in cold, electron microscopy-grade 3% glutaraldehyde solution, postfixed with 1% osmium tetroxide, and embedded in epoxy resin (Araldite 502, Structure Probe Incorporated, West Chester, Pennsylvania). Light microscopy was used to evaluate toluidine blue-stained sections. Microscopic images were examined by means of a digital image-analysis system linked to morphometric software as previously described.<sup>9</sup> At  $\times 1000$  magnification, 6 to 8 randomly selected fields per nerve, or a minimum of 500 myelinated fibers, were measured to determine fiber number, fiber diameter, and percentage of neural tissue.

### STATISTICAL ANALYSIS

All data appear as mean (SD). Significant differences in histologic parameters and serial walking track analysis between groups were detected by pairwise 2-tailed *t* tests by the use of Statistica (version 7.0; Stat Soft, Tulsa, Oklahoma). *P* < .05 was considered to indicate a statistically significant difference.

## RESULTS

One rat in the crush group from the 42-day end point died of unknown causes on postoperative day 23. Two rats, 1 from each of the 42-day crush and bipolar electrocautery groups, demonstrated autotomy of denervated digits and were euthanized. All other animals survived the study period without evidence of excessive weight loss, infection, or autotomy.

### GROSS OBSERVATIONS AND SERIAL LIVE IMAGING

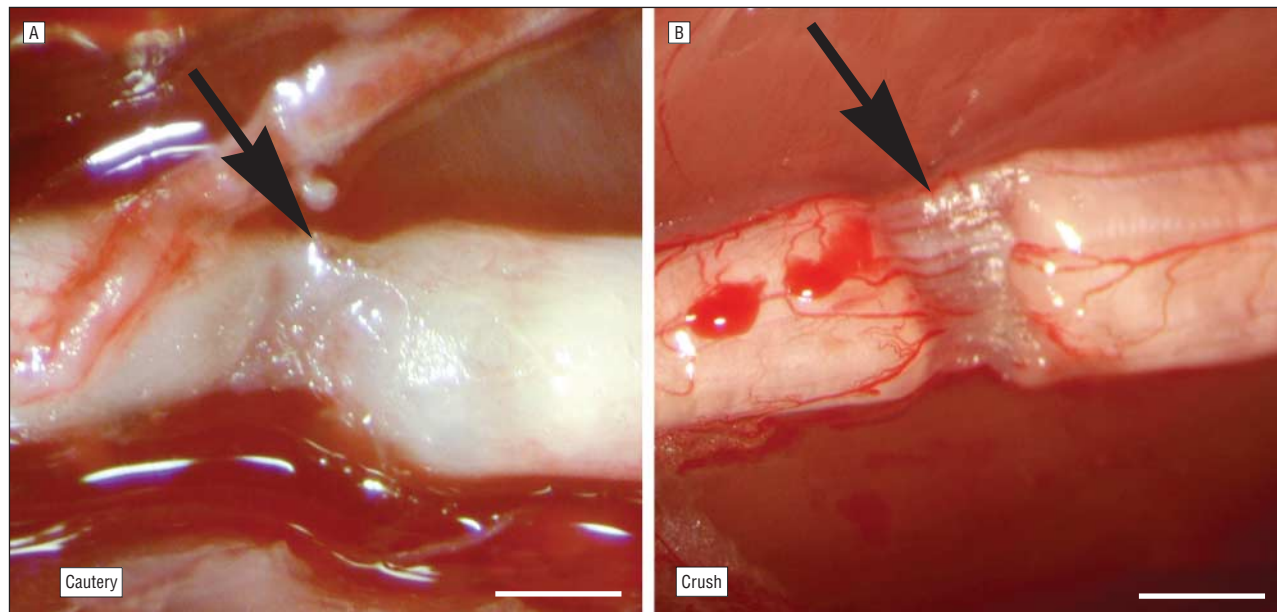
Grossly, nerves injured by bipolar electrocautery appeared desiccated, occasionally with small areas of brown, burnt tissue. Minor epineurial changes were evident in nerves injured by bipolar electrocautery, whereas the crush site had a normal gross appearance (**Figure 1**).

Weekly serial live imaging on double transgenic mice demonstrated earlier axonal regeneration across the defect in crush-injured animals. Regeneration of CFP-positive profiles (axons) distal to the marked injury site was evident at 1 week postoperatively in crush-injured mice but not until week 3 in those receiving bipolar electrocautery injuries (**Figure 2**).

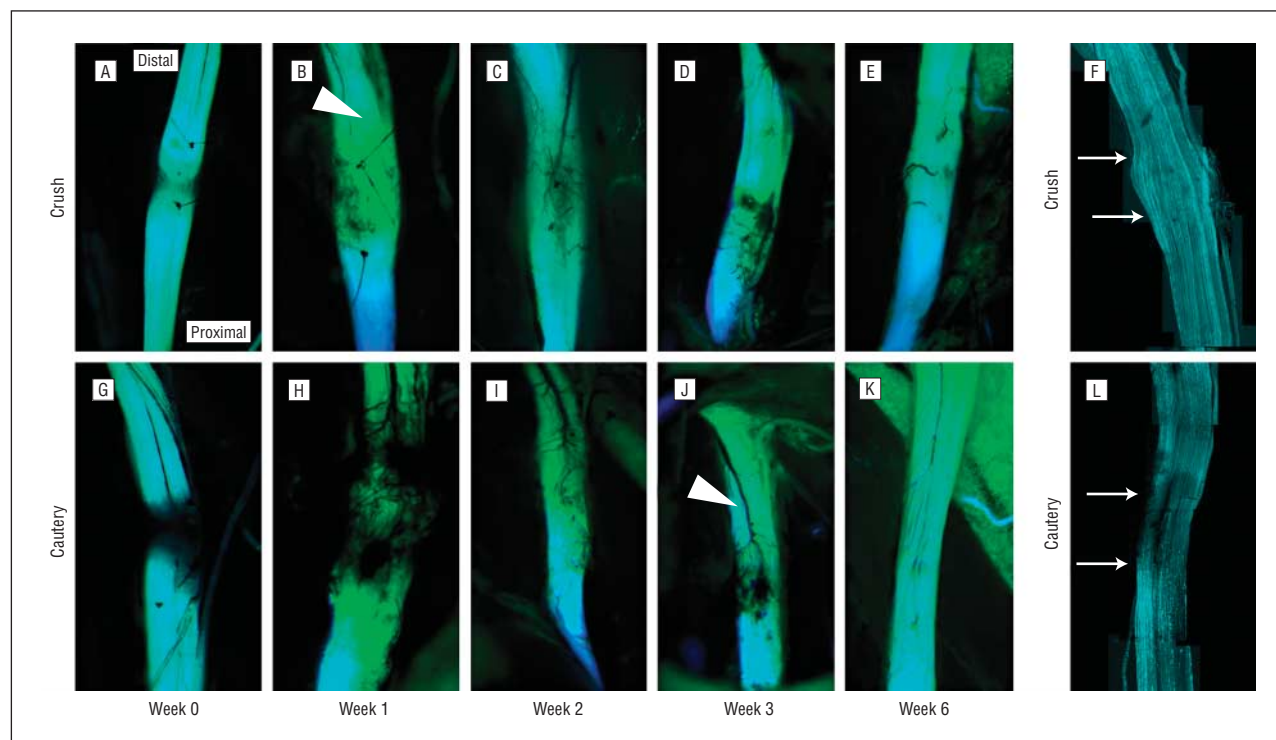
### ANALYSIS AT AND DISTAL TO THE INJURY SITE

Immunohistochemical staining at injury sites demonstrated marked disruption of myelin and neurofilament architecture in both bipolar electrocautery and crush groups compared with healthy controls at both 21 and 42 days (**Figure 3**). At 21 days, histologic sections taken from the bipolar electrocautery injury site showed neu-





**Figure 1.** Intraoperative photographs that demonstrate gross appearance of injuries. A, Bipolar electrocautery injury; B, crush injury. Arrows indicate the midpoint of the injury site. Scale bars: 1 mm.

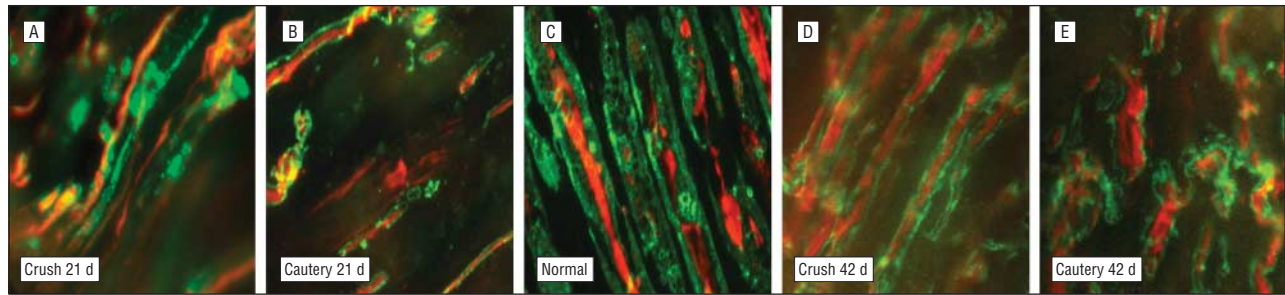


**Figure 2.** Serial live imaging and harvest end point confocal microscopy findings in sciatic nerve from cyan fluorescent protein (CFP)-conjugated Thy1 and green fluorescent protein (GFP)-conjugated S100 double transgenic mice. Sutures demarcate proximal and distal extent of grossly visible injury from crush or bipolar electrocautery. Green indicates S100 (Schwann cells and adipocytes); blue, Thy1 (axons); and cyan, overlap between the 2 fluorescent markers. A-F, Crush-injured nerves; G-L, bipolar electrocautery-injured nerves. Crush-injured nerves had visible axonal regrowth across the injured site by week 1 (B; arrowhead). In contrast, bipolar electrocautery-injured nerves exhibited no CFP-positive axons distal to the cautery injury until week 3 (J; arrowhead). F and L, whole-mount confocal microscope images demonstrate individual CFP-positive axons that cross the crush and cautery injury sites at 42 days. Arrows indicate proximal and distal extent of injury site; orientation is as in preceding fluorescent in situ images.

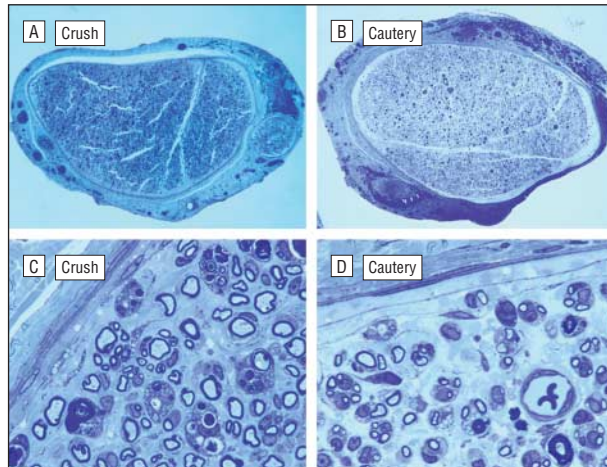
ral edema and hypervascularity, but perineurial damage was limited to edema and local thinning (**Figure 4**). Crush sites had an intact perineurium with only modest edema. At the injury site, morphometric parameters, including myelinated fiber number, fiber area, and per-

centage of neural tissue, were similar between groups (**Figure 5**).

Bipolar electrocautery injury significantly retarded nerve regeneration distal to the site of injury when compared with the crush injury group based on histomor-



**Figure 3.** Immunohistochemical staining of representative axonal-myelin relationships at the injury site in rats. Images were taken at  $\times 600$  magnification with a fluorescence-enabled light microscope. Green indicates myelin basic protein (myelin sheath); red, neurofilament (axon). A, Crush-injured nerve at 21 days; B, bipolar electrocautery-injured nerve at 21 days; C, healthy nerve; D, crush-injured nerve at 42 days; E, bipolar electrocautery-injured nerve at 42 days. Disruption persists in both injury models, but the specimens from crush-injured rats are more disordered than specimens from the bipolar electrocautery group.



**Figure 4.** Histologic cross-sections from the injury site. Whole-nerve images (A and B) are taken at  $\times 40$  magnification; sections that show details of perineurium and myelination are at  $\times 1000$  (C and D). Note perineurial continuity in all 4 specimens. Perineurium is relatively thinned but intact in cautery-injured specimens.

phometric parameters. Nerves subjected to bipolar electrocautery had decreased myelinated fiber counts and decreased percentage of neural tissue (fiber counts: 5540 [1983] for crush, 1794 [2229] for bipolar electrocautery,  $P = .007$ ; percentage of neural tissue: 13.0 [4.3] for crush, 4.8 [6.4] for bipolar electrocautery,  $P = .048$ ). The mean fiber widths for the crush and bipolar electrocautery groups were 3.09 (0.22)  $\mu\text{m}$  and 2.53 (0.63)  $\mu\text{m}$ , respectively ( $P = .053$ ) (Figure 5). The histologic appearance of the actual crush and bipolar electrocautery injury sites was similar.

### FUNCTIONAL RECOVERY

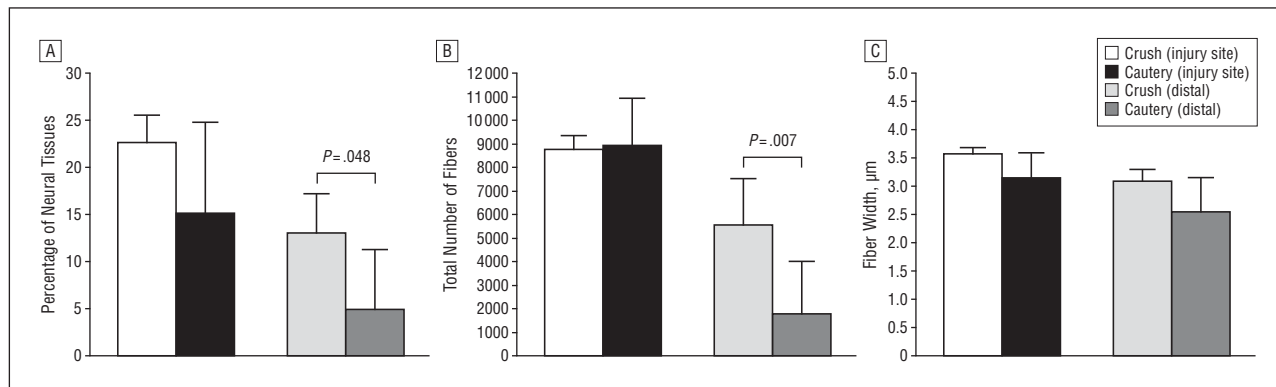
Walking track analysis performed in rat groups revealed a return to baseline functional performance after 6 weeks in animals who received crush injury. No statistically significant recovery was observed after bipolar electrocautery, although a trend toward recovery was discernible at the 6-week end point (Figure 6). Neuromuscular junction staining performed on whole-mount mouse extensor digitorum longus muscles demonstrated functional reinnervation in both the bipolar electrocautery and crush-injured groups but with far fewer reinnervated end plates in the bipolar electrocautery group (Figure 7).

### COMMENT

We found that bipolar electrocautery induced a more durable injury than crush in a sciatic nerve model. Our observation of spontaneous regeneration by a substantial axon population, by both serial live imaging and histomorphometric analysis, suggests a Sunderland third-degree injury. Currently, there is little consensus on the management of bipolar electrocautery injuries. Clinical teaching dictates that the treatment of nerve injuries depends on prognosis: if a patient is not expected to recover from an injury spontaneously, timely reconstruction is indicated to maximize the chance of an acceptable functional result. Conversely, if the natural history of an injury is usually complete recovery, observation is appropriate. Conversion of a nonneurotmetic injury with the potential for spontaneous recovery into a full-discontinuity lesion should be discouraged. The Sunderland classification of neural injury is frequently used to correlate histologic findings with eventual functional outcomes (Table 2).

Prolonged exposure to local hyperthermia is known to cause damage to the rat sciatic nerve without disruption of endoneurial tubes,<sup>10</sup> similar to a crush model.<sup>11</sup> Sensory fibers are more sensitive to heat than motor fibers,<sup>12</sup> although the latter are more susceptible to secondary ischemia after hyperthermia.<sup>13</sup> More severe nerve injury occurs at higher temperatures, such as those that occur with electrocautery.<sup>14</sup> Notably, whereas most experimental crush injuries produce similar outcomes,<sup>3</sup> bipolar electrocautery injuries may be more heterogeneous, depending on the duration and intensity of the electrical impulse. In this study, a standardized bipolar electrocautery injury was used to minimize differences between the 2 groups of animals, as previously described.<sup>6</sup>

The Sunderland classification integrates 2 aspects of nerve injury: histologic findings and functional recovery. Histologic assessment performed at 3 weeks after injury demonstrated mild perineurial injury but maintenance of perineurial patency in bipolar electrocautery-injured specimens. Descriptive axonal parameters, including myelinated fiber number, fiber width, and percentage of neural tissue, were not significantly different between crush and bipolar electrocautery groups at the injury site, which demonstrates that many mature



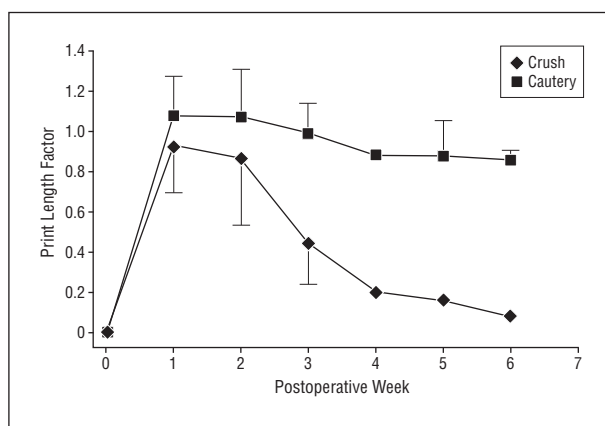
**Figure 5.** Quantitative histomorphometry findings. A, Percentage of neural tissue; B, total number of fibers; C, fiber width. No significant differences were found between crush-injured and bipolar electrocautery-injured specimens at the injury site; distal to the injury, percentage of neural tissue and total number of fibers were significantly different. Error bars indicate SD.

axons were able to spontaneously cross the injury site by 21 days in both groups. This was confirmed qualitatively by serial live imaging performed in a mouse model of bipolar electrocautery injury, where axons were noted to cross a crush injury site by 1 week after injury and a bipolar electrocautery injury site by 3 weeks.

Distal to the site of injury, nerves subjected to bipolar electrocautery injury had significantly fewer myelinated fibers and a lower percentage of neural tissue than crush-injured nerves. These 2 injuries, therefore, do not recover in an equivalent manner; histomorphometric recovery across a cauterized site is delayed and incomplete relative to crush. However, the perineurial disruption described in Sunderland fourth-degree injuries was not found here; only mild perineurial thinning and disorganization were seen. These findings are consistent with the histologic features of a Sunderland third-degree injury, in which axonal regeneration occurs spontaneously but to a lesser degree than after crush injury and the perineurium is essentially intact.

The second facet of the Sunderland classification is functional recovery. Walking track analysis demonstrated full recovery in crush-injured animals by 6 weeks, consistent with a second-degree injury. There was no significant reduction in print length factor in bipolar electrocautery-injured animals over time, although a trend toward recovery was noted. The tendency for functional recovery to lag behind histomorphometric findings is well described.<sup>15,16</sup> Qualitative serial live imaging studies and neuromuscular junction staining in the mouse model, as well as quantitative histomorphometric analysis in the rat model, indicated that a substantial number of nerve fibers were able to spontaneously cross the bipolar electrocautery injury defect, which may have led to eventual functional recovery in later weeks.

On the basis of the findings of the present study, we conclude that bipolar injury is most consistent with a Sunderland third-degree injury. Although this conclusion differs from that of Hnatuk et al,<sup>6</sup> who concluded that bipolar electrocautery induces a Sunderland fourth-degree injury, we suggest that the data from both studies favor the third-degree classification. Hnatuk et al reported improvement in muscle weight and contractile force during the 8-week recovery period in their study,



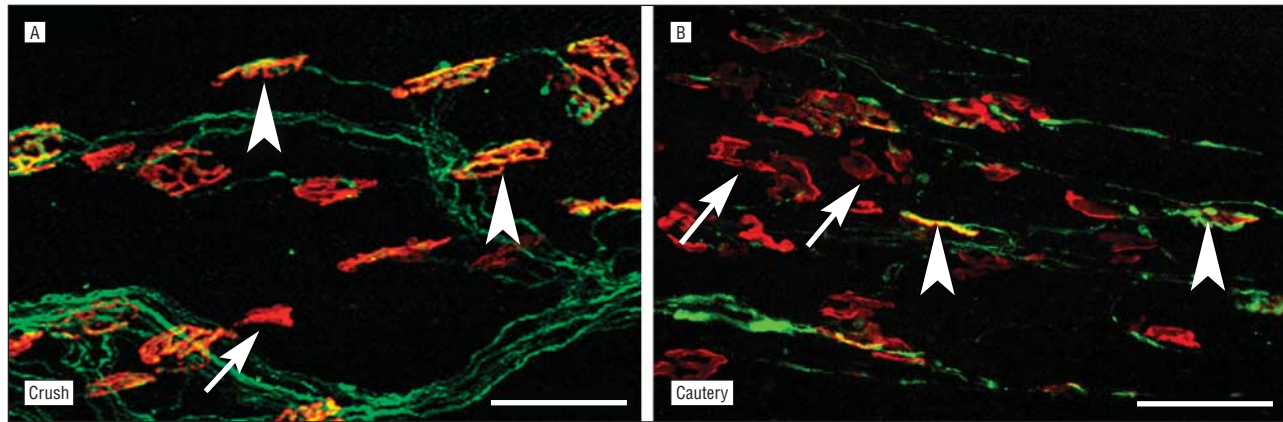
**Figure 6.** Walking track analysis. Functional recovery, as measured by print length factor, was significantly greater in crush-injured rats starting at postoperative week 3. Because of attrition owing to autotomy,  $n=1$  or 2 for crush and bipolar electrocautery, respectively, at weeks 4 through 6. Error bars represent SD, where appropriate.

which suggests that moderate functional recovery could be expected without operative intervention, consistent with a third-degree injury. The trend toward functional recovery seen in our rats at 6 weeks after injury may be the beginning of a return to limited function, consistent with the mouse model findings.

Future research is needed to investigate this injury in a higher animal model. It has been shown that rodents are able to overcome injury paradigms that would be insurmountable in a human<sup>17</sup>; functional and histomorphometric recovery has been demonstrated distal to untreated allografts,<sup>18</sup> and the rat's tissue is able to regenerate spontaneously into an unfilled nerve gap to a distance of 2.4 cm after 5 months.<sup>19</sup> There is a concern, therefore, in this model that although a rodent's tissue is able to regenerate spontaneously through the area of damage induced by bipolar electrocautery, the more limited regenerative capacity of a human would fail. Thorough evaluation of the prognosis of a bipolar electrocautery injury would enable surgeons to more appropriately counsel patients with regard to treatment options.

In conclusion, bipolar electrocautery results in a more profound impairment of sciatic nerve function than a standard crush model, with mild perineurial damage and spon-





**Figure 7.** Neuromuscular junction (NMJ) staining in double transgenic mice. A, Crush injury; B, bipolar electrocautery injury. Arrowheads indicate reinnervated NMJs, distinguished by the yellow overlap between  $\alpha$ -bungarotoxin staining (red) and native axonal cyan fluorescent protein (green); arrows point to nonreinnervated NMJs. Scale bars are 50  $\mu$ m. Specimens from mice who received crush injury demonstrated reinnervation of nearly all NMJs; for illustrative purposes, a field that contains a nonreinnervated junction is shown.

**Table 2. Sunderland Classification of Neural Injury<sup>a</sup>**

Injury Class	Histologic Findings	Functional Recovery	Management
First degree (neurapraxia)	Perhaps normal; conduction block	Spontaneous and complete	Nonoperative
Second degree (axonotmesis)	Axons do not survive below the level of injury; wallerian degeneration; endoneurial tubes remain intact	Spontaneous, although requires axonal regrowth at a rate of approximately 1 in per month, with full return to function	Nonoperative <sup>b</sup>
Third degree	Wallerian degeneration, some intraneural fibrosis, plus disorganization within perineurial boundaries and discontinuity of endoneurial tubes; perineurium may show minor changes	Axonal obstruction and/or misdirection results in partial but spontaneous functional recovery, more delayed than would be expected for a second-degree injury	Nonoperative <sup>b</sup>
Fourth degree	Disorganization of all components, with severe intraneural disruption but maintained epineurial continuity	Will not proceed to a useful degree without intervention	Operative excision of affected segment and primary repair
Fifth degree (neurotmesis)	Loss of continuity of all nerve components, ie, severed nerve	None without surgical repair; even with repair, recovery is incomplete	Operative repair

<sup>a</sup>Adapted from Sunderland.<sup>4</sup>

<sup>b</sup>Management of these injuries is nonoperative, unless the injury localizes to a known area of nerve entrapment. In that case, operative decompression may be performed, but excision of neural tissue is unnecessary.

taneous histomorphometric recovery at the injury site at 3 weeks but significant residual functional impairment at 6 weeks. These functional and histologic characteristics indicate that bipolar electrocautery induces a Sunderland third-degree peripheral nerve injury in the rodent model. To our knowledge, we now have the first animal model of a third-degree nerve injury, which will advance peripheral nerve research. Further studies are necessary to elucidate the effect on human neural tissue, with the ultimate goal of defining treatment paradigms for this uncommon but disabling injury.

**Accepted for Publication:** February 20, 2009.

**Correspondence:** Susan E. Mackinnon, MD, Division of Plastic and Reconstructive Surgery, 660 S Euclid Ave, Box 8238, St Louis, MO 63110 (mackinnon@wudosis.wustl.edu).

**Author Contributions:** *Study concept and design:* Moradzadeh, Brenner, Whitlock, Myckatyn, and Mackinnon. *Acquisition of data:* Moradzadeh, Whitlock, Tong, Luciano, Hunter, and Myckatyn. *Analysis and interpre-*

*tation of data:* Moradzadeh, Brenner, Whitlock, Hunter, Myckatyn, and Mackinnon. *Drafting of the manuscript:* Moradzadeh and Brenner. *Critical revision of the manuscript for important intellectual content:* Moradzadeh, Whitlock, Tong, Luciano, Hunter, Myckatyn, and Mackinnon. *Statistical analysis:* Moradzadeh and Hunter. *Obtained funding:* Myckatyn. *Administrative, technical, and material support:* Brenner, Whitlock, Tong, Luciano, and Myckatyn. *Study supervision:* Moradzadeh, Myckatyn, and Mackinnon.

**Financial Disclosure:** None reported.

**Funding/Support:** This work was funded by a generous donation to our department from Jaqueline and Moshe Tal, Jean Agatstein, and Leslie F. Loewe and by a Leslie Bernstein Investigator Development Grant from the Educational and Research Foundation for the American Academy of Facial Plastic and Reconstructive Surgery.

**Role of the Sponsor:** Our departmental funding source had no role in the design and conduct of the study; in the collection, analysis, and interpretation of the data; or in the preparation, review, or approval of the manuscript.

**Additional Contributions:** Vinay Puppala, MD, provided assistance with preliminary animal work in this study.

## REFERENCES

1. Greenwood J. Two point coagulation: a new principle and instrument for applying coagulation current in neurosurgery. *Am J Surg.* 1940;50(2):267-270.
2. Zohar Y, Sadov R, Strauss M, Djaldetti M. Ultrastructural study of peripheral nerve injury induced by monopolar and bipolar diathermy. *Ann Otol Rhinol Laryngol.* 1996;105(9):673-677.
3. Bridge PM, Ball DJ, Mackinnon SE, et al. Nerve crush injuries: a model for axonotmesis. *Exp Neurol.* 1994;127(2):284-290.
4. Sunderland S. A classification of peripheral nerve injuries producing loss of function. *Brain.* 1951;74(4):491-516.
5. Seddon HJ. The use of autogenous grafts for the repair of large gaps in peripheral nerves. *Br J Surg.* 1947;35(138):151-167.
6. Hnatuk LA, Li KT, Carvalho AJ, Freeman JL, Bilbao JM, McKee NH. The effect of bipolar electrocautery on peripheral nerves. *Plast Reconstr Surg.* 1998;101(7):1867-1874.
7. Hayashi A, Koob JW, Liu DZ, et al. A double-transgenic mouse used to track migrating Schwann cells and regenerating axons following engraftment of injured nerves. *Exp Neurol.* 2007;207(1):128-138.
8. Brown CJ, Mackinnon SE, Evans PJ, et al. Self-evaluation of walking-track measurement using a Sciatic Function Index. *Microsurgery.* 1989;10(3):226-235.
9. Hunter DA, Moradzadeh A, Whitlock EL, et al. Binary imaging analysis for comprehensive quantitative histomorphometry of peripheral nerve. *J Neurosci Methods.* 2007;166(1):116-124.
10. Wondergem J, Haveman J, Rusman V, Sminia P, Van Dijk JD. Effects of local hyperthermia on the motor function of the rat sciatic nerve. *Int J Radiat Biol Relat Stud Phys Chem Med.* 1988;53(3):429-438.
11. Hoogeveen JF, Troost D, Wondergem J, van der Kracht AH, Haveman J. Hyperthermic injury versus crush injury in the rat sciatic nerve: a comparative functional, histopathological, and morphometrical study. *J Neurol Sci.* 1992;108(1):55-64.
12. Eliasson SG, Monafo WW, Nussbaum G, Olsen L. Differential effects of in vitro heating on rat sciatic nerve branches and spinal nerve roots. *Exp Neurol.* 1986; 93(1):57-66.
13. Xu D, Pollock M. Experimental nerve thermal injury. *Brain.* 1994;117(pt 2):375-384.
14. Donzelli J, Leonetti JP, Bergstrom R, Wurster RD, Young MR. Thermoprotective mechanisms of irrigation during bipolar cautery. *Otolaryngol Head Neck Surg.* 1998;119(3):153-158.
15. Lee M, Doolabh VB, Mackinnon SE, Jost S. FK506 promotes functional recovery in crushed rat sciatic nerve. *Muscle Nerve.* 2000;23(4):633-640.
16. Munro CA, Szalai JP, Mackinnon SE, Midha R. Lack of association between outcome measures of nerve regeneration. *Muscle Nerve.* 1998;21(8):1095-1097.
17. Brenner MJ, Moradzadeh A, Myckatyn TM, et al. Role of timing in assessment of nerve regeneration. *Microsurgery.* 2008;28(4):265-272.
18. Calvert GT, Doolabh VB, Grand AG, Hunter DA, Mackinnon SE. Rat-strain differences in recovery following peripheral-nerve allotransplantation. *J Reconstr Microsurg.* 2001;17(3):185-191.
19. Mackinnon SE, Hudson AR, Hunter DA. Histologic assessment of nerve regeneration in the rat. *Plast Reconstr Surg.* 1985;75(3):384-388.

## Announcement

Visit [www.archfacial.com](http://www.archfacial.com). As an individual subscriber you may view articles by topic. Topic Collections group articles by topic area within a journal and across *JAMA* and the *Archives Journals*. The Topic Collections displayed on each journal site show the topic areas most relevant to that journal's readership. You may use the Topic Collections list in 3 ways:

1. From the Collections page, select the topic of interest to view all articles in that topic in 1 journal or all journals.
2. From an article page, click on the topic collections associated with that article to view other articles on that topic.
3. Sign up to receive an alert when new articles in *JAMA* and the *Archives Journals* are published on the topics of your choice.