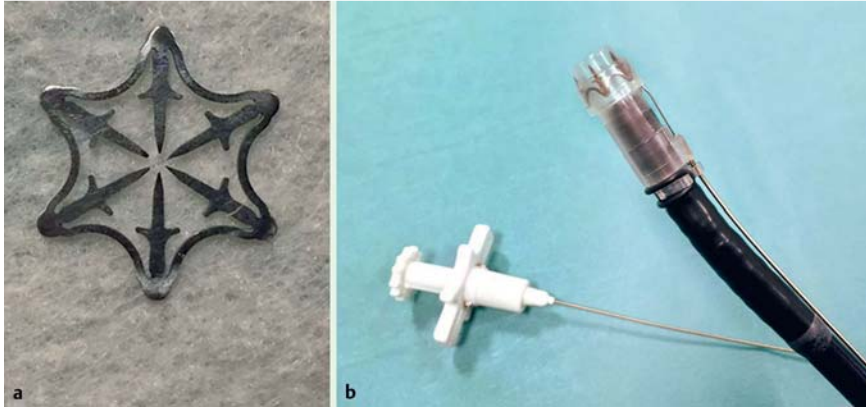
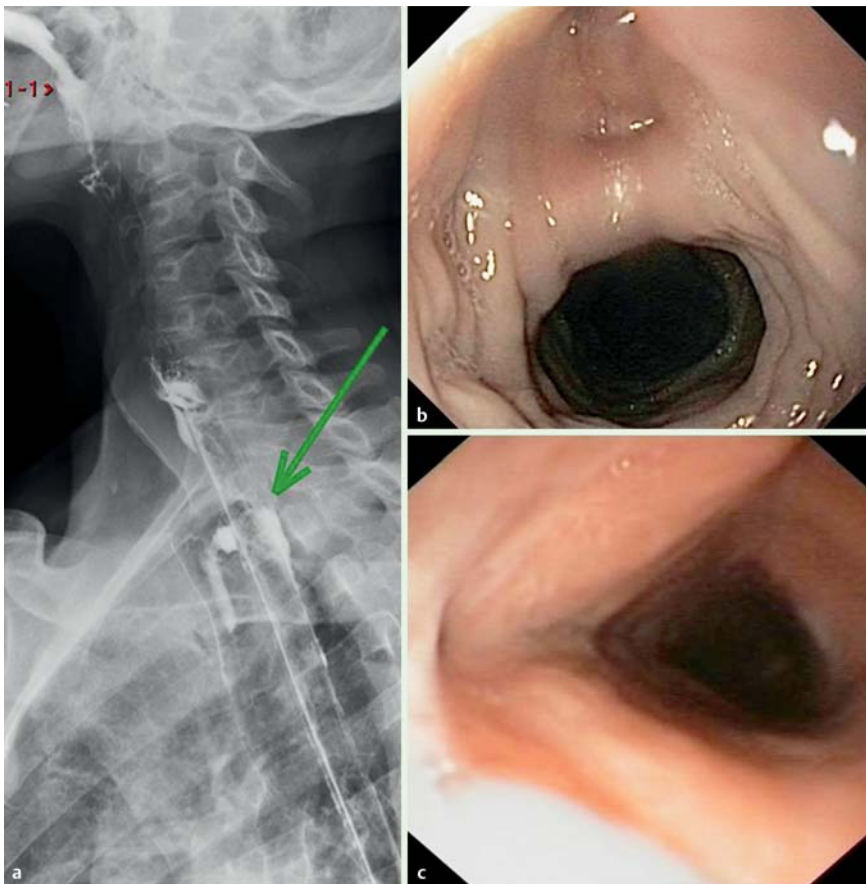


## New endoscopic over-the-scope clip system for treatment of a chronic post-surgical tracheo-esophageal fistula



**Fig. 1** Photographs showing: **a** the new Padlock Clip; and **b** its extrascopic Lock-It delivery system.



**Fig. 2** The tracheo-esophageal fistula seen on: **a** radiological view (fistula indicated by green arrow); **b** endoscopic view; **c** bronchoscopic view.

Acquired tracheo-esophageal fistula is a rare condition, often linked to malignancy, trauma, or iatrogenic cuff-related injury. Poor nutrition, infection, radiotherapy, and steroid use are predisposing factors. Surgical management is difficult, time-consuming, and associated with significant morbidity and mortality [1]. Conservative endoscopic therapeutic options, such as self-expandable metal stents, clips, and sealants have been investigated with satisfactory results.

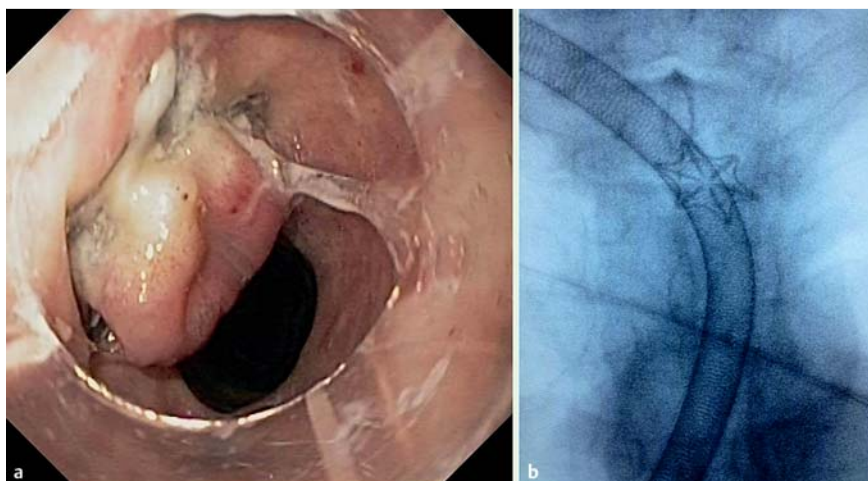
In recent years, over-the-scope clip (OTSC) systems have shown good technical and clinical success as a result of their more vigorous closure than regular through-the-scope clips and because of their wider mouths and ability to grip larger amounts of tissue [2].

Recently a novel tissue-closure device (Padlock Clip; Aponos Medical, Kingston New Hampshire, USA) has been developed and tested in porcine models, providing secure closure of full-thickness wall defects [3]. It consists of a hexagonal nitinol ring with six inner needles and is pre-assembled on an applicator cap. It is thumb-press deployed by the Lock-It delivery system, which is located parallel to the working channel or other instruments (● **Fig. 1**). Simple suction is enough to obtain tissue adhesion to the instrument tip. When deployed, the ring instantly springs back to its original form.

In 2007, a 60-year-old man underwent laryngectomy for laryngeal cancer followed by chemoradiotherapy. In March 2014, he was admitted to our hospital because of recurrent bronchitis and cough. Computed tomography (CT) scanning, Gastrografin esophagography, and endoscopy showed a tracheo-esophageal fistula (● **Fig. 2**). Several unsuccessful treatments were attempted, including surgery, salivary bypass stenting, and endoscopic clipping.

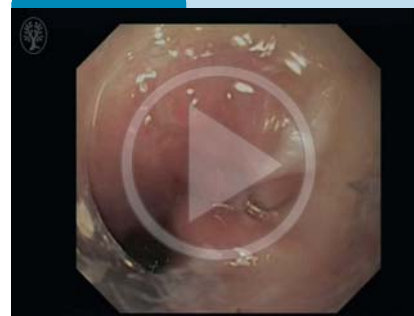In September 2014, we decided to try placing a Padlock Clip. Using endoscopic and fluoroscopic control, we successfully deployed the clip at the esophageal edge of the fistula (● **Video 1**; ● **Fig. 3**). The patient did well after treatment and no immediate or delayed complications occurred. After 5 months of follow-up, he is feeding normally and no recurrence of symptoms has been reported.

To our knowledge, this is the first clinical experience of closure of a tracheo-esophageal fistula using a Padlock Clip.



**Fig. 3** The tracheoesophageal fistula after closure with the Padlock Clip on: **a** endoscopic view; **b** fluoroscopic image.

#### Video 1



Endoscopy showing the tracheoesophageal fistula and its successful closure with a Padlock Clip.

Endoscopy\_UCTN\_Code\_TTT\_1AO\_2AI

**Competing interests:** None

**Elia Armellini, Stefano F. Crinò, Marco Orsello, Marco Ballarè, Silvia Saettone, Roberto Tari, Pietro Occhipinti**

Azienda Ospedaliero Universitaria  
"Maggiore della Carità", Novara, Italy

#### References

- 1 Reed MF, Mathisen DJ. Tracheoesophageal fistula. *Chest Surg Clin N Am* 2003; 13: 271–289
- 2 Haito-Chavez Y, Law JK, Kratt T et al. International multicenter experience with an over-the-scope clipping device for endoscopic management of GI defects (with video). *Gastrointest Endosc* 2014; 80: 610–622
- 3 Desilets DJ, Romanelli JR, Earle DB et al. Gastrotomy closure with the lock-it system and the Padlock-G clip: a survival study in a porcine model. *J Laparoendosc Adv Surg Tech A* 2010; 20: 671–676

#### Bibliography

**DOI** <http://dx.doi.org/10.1055/s-0034-1392673>  
*Endoscopy* 2015; 47: E437–E438  
 © Georg Thieme Verlag KG  
 Stuttgart · New York  
 ISSN 0013-726X

#### Corresponding author

**Elia Armellini, MD**  
 Department of Gastroenterology  
 Azienda Ospedaliero Universitaria  
 "Maggiore della Carità"  
 Corso Mazzini 18  
 28100 – Novara  
 Italy  
 Fax: +39-3213-733345  
[elia\\_armellini@hotmail.com](mailto:elia_armellini@hotmail.com)