

# Early antithrombotic therapy and COVID-19: a better clinical course? New evidences from real-life cases

Matteo Casale<sup>a</sup>, Egidio Imbalzano<sup>b</sup>, Claudia Morabito<sup>b</sup>,  
Marianna Gigliotti De Fazio<sup>b</sup>, Pasquale Crea<sup>b</sup>, Maurizio Mezzetti<sup>a</sup>,  
Paolo Busacca<sup>a</sup>, Michele Correale<sup>c</sup>, Salvatore Santo Signorelli<sup>d</sup>,  
Giuseppe Dattilo<sup>b</sup>

<sup>a</sup> Operative Unit of ICCU and Cardiology, Hospital "S. Maria della Misericordia", ASUR Marche – Area Vasta 1, Urbino, Italy

<sup>b</sup> Department of Clinical and Experimental Medicine, University of Messina, Messina, Italy

<sup>c</sup> Operative Unit of ICCU and Cardiology, University Hospital, Foggia, Italy

<sup>d</sup> Department of Clinical and Experimental Medicine, University of Catania, Catania, Italy

---

## ARTICLE INFO

### Article history:

Submitted: 21. 5. 2020

Accepted: 22. 5. 2020

Available online: 22. 5. 2020

### Klíčová slova:

COVID-19

DOAC

Edoxaban

Nízkomolekulární heparin

Tromboembolismus

### Keywords:

COVID-19

DOAC

Edoxaban

Low molecular weight heparin

Thromboembolism

---

## SOUHRN

Recentní onemocnění COVID-19 přináší možné rizikové faktory žilního tromboembolismu a horší klinický průběh u některých pacientů má spojitost s trombózou. Zatímco nízkomolekulární hepariny jsou zkoumány s ohledem na vhodnou dávku, ostatní elementy mohou být užitečné. Sdílíme naši zkušenost týkající se dvou pacientů s neočekávaným klinickým průběhem.

© 2020, ČKS.

---

## ABSTRACT

The recent COVID-19 carries potential risk factors for VTE and worse clinical course in some patients has an association with thrombosis. While low molecular weight heparins are under investigation for appropriate dosage, other elements could be useful. We share our experience about two patients with unexpected clinical course.

---

**Address:** Matteo Casale, MD, Hospital S. Maria della Misericordia of Urbino, Operative Unit of ICCU and Cardiology, ASUR Marche – Area Vasta 1, Italy,  
e-mail: mat.casale@gmail.com

**DOI:** 10.33678/cor.2020.053

## Introduction

Venous thromboembolism (VTE) in critically ill patients with an infection is a well-known condition.<sup>1</sup>

The recent pandemic due to coronavirus (COVID-19), especially in severe forms, carries several potential risk factors for VTE: pro-thrombotic state due to inflammation, immobilization, respiratory failure, mechanical ventilation and placement of central venous catheters.<sup>2</sup> There is increasing evidence that anticoagulant therapy with low molecular weight heparins (LMWH) appears to be associated with a better prognosis in patients with COVID-19 who meet SIC criteria or with markedly high D-dimer.<sup>3</sup>

In a subject with sudden clinical deterioration it seems that pulmonary thromboembolism plays a central role in the evolution and, in fact, in literature, there are growing evidences of interstitial pneumonia due to COVID-19 with concomitant pulmonary embolism.<sup>4</sup>

## Personal experience

We describe the case of 2 patients, husband and wife, who were affected by COVID-19 and who had different clinical courses.

The 76-year-old wife had a history of chronic kidney failure, hyperuricemia, paroxysmal atrial fibrillation, mitral and tricuspid mild insufficiency, reduced ejection fraction (EF 40%), dysthyroidism; moreover she had an implantable cardioverter defibrillator (ICD) in secondary prevention because of a syncope caused by ventricular tachycardia, detected by a loop recorder. She was in therapy with Furosemide 25 mg od, Olmesartan 20 mg, Allopurinol 300 mg, Levothyroxine 100 µg, Bisoprolol 3,75 mg and Edoxaban 60 mg od.

The husband, 80 years old, was affected by arterial hypertension without organ damage, treated with Olmesartan 20 mg; EF was 60% and there were no other comorbidities.

Few days after a contact with a patient with a diagnosis of COVID-19 both of them developed high fever (39 °C). They asked their general practitioner and local health authorities for advice, with indication to assume only Paracetamol as symptomatic therapy and to maintain a quarantine at home.

Five days later, fever was still high despite Paracetamol. For both of them nasopharyngeal swab was positive for COVID-19 but the husband was hospitalized because of worsening dyspnea. His blood tests at admission were: Hb 14.3 gr%, WBC 11000 mmc, PLT 102000 mmc, creatinine 1.9 mg/dl, CPK 2910 U/L, Myoglobin 2383 ng/ml, Na 128 mmol/L, K 4,4 mmol/L, D-dimer >4 µg/mL, PCT 14.7 ng/ml, CRP 12.7 mg/dl, INR 1.23, PTT 39.7 s, AT III 75%, fibrinogen 632 mg/dl. Blood gas analysis during oxygen support by Ventimask with a FiO<sub>2</sub> 35% showed: pH 7.47, PaO<sub>2</sub> 81 mmHg, PaCO<sub>2</sub> 28 mmHg, SO<sub>2</sub> 98%, HCO<sub>3</sub><sup>-</sup> 22 mmol/L, P/F 232. Treatment with lopinavir/ritonavir 200 mg od, empirical antimicrobial therapy with piperacillin/tazobactam 4.5 gr tris in die, fondaparinux 2.5 mg was started. Two days later his clinical status worsened and the blood gas analysis showed: pH 7.54, PaO<sub>2</sub> 43 mmHg, PaCO<sub>2</sub> 26 mmHg, P/F 72, SO<sub>2</sub> 85% HCO<sub>3</sub><sup>-</sup> 25 mmol/L with FiO<sub>2</sub> 60%), CRP was almost doubled (25 mg/dl), WBC increased (23400 mmc), TC 39 °C. It was necessary to start invasive ventilation and to bring him in Intensive Care Unit. A chest X-ray showed multiple and bilateral areas of interstitial involvement (Fig. 1C). One week later hemodialysis was started because of concomitant acute kidney failure. Few days after D-dimer, PLT and PCT normalized, while other blood tests remained stable over time; other two COVID-19 tests were performed by bronchoalveolar lavages performed from the chest tube, confirming COVID-19. Two weeks after, no amelioration was observed, with a worsening of the lung involvement at bedside chest X-ray (Fig. 1D). It was not possible to extubate him because of lack of spontaneous breathing and today he is still hospitalized in Intensive Care Unit.

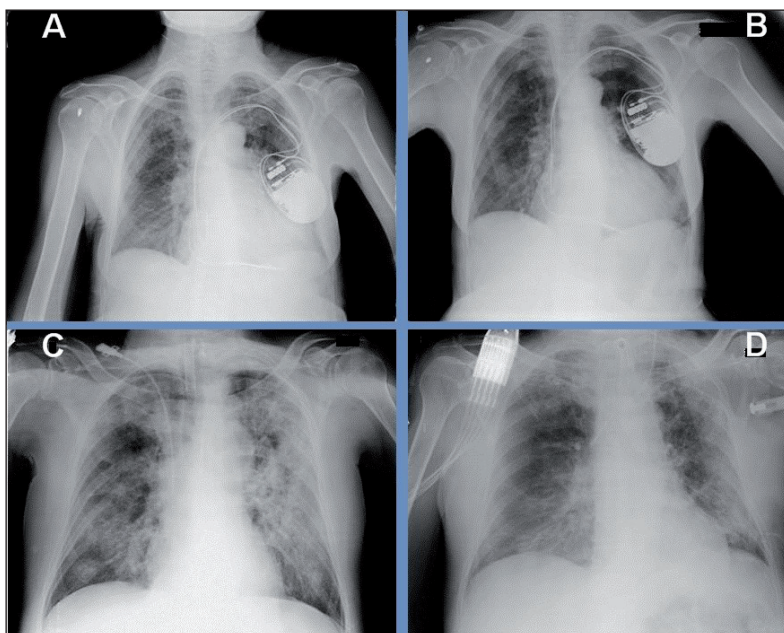


Fig. 1 – (Panel A) Chest X-ray of the wife at hospital admission showing mild interstitial involvement bilaterally and thickening of basal lung fields, heart increased in size, presence of ICD on the left. (Panel B) Chest X-ray of the wife 10 days after showing improvement of the previous lung findings. (Panel C) Chest X-ray of the husband immediately after intubation and central venous catheter placement. There is diffuse clouding due to multiple confluent bilateral pulmonary thickenings. (Panel D) Chest X-ray of the husband after two weeks from intubation does not show improvement.

The day after husband's hospital admission even his wife remained symptomatic receiving hospitalization. Her clinical course was good; blood tests remained normal and stable: Hb 12.9 gr%, WBC 3600 mmc, PLT 175000 mmc, CRP 0.29 mg/dl, PCT 0.08 ng/ml, PT 74%, INR 1.16, PTT 31.6 s, D-dimer 0.27 µg/mL, Fibrinogen 373 mg/dl. Chest X-ray showed minimal bilateral interstitial involvement (Fig. 1A). Because one day her PTT increased to 180 s, INR to 2.10 and PT to 30%, Edoxaban was temporarily suspended but just for one day. Her saturation remained always >92% without needing oxygen therapy; fever disappeared after 4 days from admission only by Paracetamol and, 10 days later, chest X-ray improved (Fig. 1B). After 3 weeks she was discharged, when 2 consecutive nasopharyngeal swabs were found to be negative for COVID-19.

---

## Discussion

Our experience shows an important difference in clinical course between two patients with COVID-19. These spouses have been infected in the same time but had a different clinical course. The most important element is that a worse clinical course was expected for the woman because of her severe cardiovascular disease and because of her cardiovascular risk factors. Instead for her husband, who had only arterial hypertension (with a good control at home), with neither structural cardiac diseases nor other comorbidities, a poor clinical prognosis is currently expected. While at the beginning of the pandemic some argued a potential risk for ACE/ARB users, other evidences denied this possibility, highlighting instead a protective effect.<sup>5</sup> In our patients this possible confounding factor was overcome because both were taking the same drug at the same dosage with good pressure control at home. Because currently there is not, in literature, involvement for other pharmacological agents the only drug which could improve wife's prognosis, in our opinion, was Edoxaban.

In fact there are increasing evidences of an association between COVID-19 and thromboembolism and literature in this field is currently growing. Cui et al. retrospectively studied COVID-19 patients with severe pneumonia finding an incidence of 25% of thromboembolism in a small cohort of 81 patients.<sup>6</sup> Despite high incidence it is difficult to ascertain the exact number of patients with thromboembolism exclusively due to COVID-19. Other evidence supporting a central role of COVID-19 in thromboembolism was recently published by Tang et al.<sup>3</sup> The Authors found in their large retrospective study that 28-day mortality of heparin users was lower than nonusers in patients with SIC score >4 or D-dimer >3 µg/ml. Furthermore Wang et al. published a case series in which a better clinical course was present in those patients with ARDS by COVID-19 receiving tissue plasminogen activator.<sup>7</sup> These data support the hypothesis that a severe course is associated with thromboembolism. In fact diffuse pulmonary embolism, by microvascular obstruction, impairs blood oxygenation in alveolar capillaries, leading to progressive desaturation: the more parenchymal impairment

the more incorrigible desaturation, leading to death.<sup>7</sup> Several evidences suggest that inflammatory diseases associated with a pro-thrombotic state could easily impact the patient prognosis<sup>8</sup> and, in particular, patients with cardiovascular disease and COVID-19 have an increased mortality risk among all other COVID-19 patients.<sup>2</sup> Between patients with heart disease those ones with arrhythmias or a CIED could take an unpredictable clinical course.<sup>9-11</sup> In our patients, however, the clinical course was completely different from the expectations. An analysis of our patients' characteristics shows that the husband had a rapid clinical deterioration with high D-dimer (considered at the beginning only as a finding compatible with the infection), assuming the significance of pulmonary thromboembolism,<sup>3</sup> which was normal for the wife instead of him. Moreover among the drugs received by both patients the only one which could influence the clinical course was Edoxaban. We suppose that this drug, already tested both for atrial fibrillation and for VTE<sup>12</sup> and chronically assumed from the wife, played a protective role against the thrombotic state due to COVID-19. On the other hand Fondaparinux 2,5 mg in the husband probably was not sufficient to protect him from thrombosis. With the obvious limit of a personal experience and of the lack of larger evidences we hypothesize that early use of anticoagulant therapy at full dose could contrast coagulum formation, avoiding microvascular obstruction and modifying radically the clinical course. One may even speculate about home self-administration at least in a subset of patients with a nasal swab positive for COVID-19. This could avoid impairment of gas exchanges favoring pulmonary parenchyma healing.

In fact from the beginning of the pandemic use of LMWH has grown, especially for patients in ICU,<sup>13</sup> and currently several trials are ongoing to test the best dose. However we believe that as many strategies are investigated and available the easier is finding a solution for each patient. In fact in literature there are some reports of LMWH failure.<sup>14,15</sup> It is clearly too early to state that concomitant chronic use of DOAC for atrial fibrillation could play a protective role in patients with COVID-19 but evidences of the role of thromboembolism and the spread of the LMWH use in this context are in constant growth. Probably larger studies in the short term could confirm or deny this hypothesis.

---

## Conclusions

Evidences in literature suggest a pathophysiological rationale in antithrombotic therapy in COVID-19. While a high dose of LMWH is currently not supported for each patient, an early antithrombotic strategy could improve the clinical course at least in some patients. Some areas of uncertainty such as the proper dose of LMWH (e.g. anticoagulation vs thromboprophylaxis) and the possible protective role of DOAC could be clarified in the next future.

## Conflict of interest

None.

**Funding body**

None.

**References**

1. Samama MM, Cohen AT, Darmon J-Y, et al. A comparison of enoxaparin with placebo for the prevention of venous thromboembolism in acutely ill medical patients. *N Engl J Med* 1999;341:793–800.
2. Wang D, Hu B, Hu C, et al. Clinical characteristics of 138 hospitalized patients with 2019 novel coronavirus-infected pneumonia in Wuhan, China. *JAMA* 2020;323:1061–1069.
3. Tang N, Bai H, Chen X, et al. Anticoagulant treatment is associated with decreased mortality in severe coronavirus disease 2019 patients with coagulopathy. *J Thromb Haemost* 2020;18:1094–1099.
4. Danzi GB, Loffi M, Galeazzi G, Gherbesi E. Acute pulmonary embolism and COVID-19 pneumonia: a random association? *Eur Heart J* 2020 Mar 30. pii: ehaa254. doi: 10.1093/eurheartj/ehaa254.
5. Zhang P, Zhu L, Cai J, et al. Association of Inpatient Use of Angiotensin Converting Enzyme Inhibitors and Angiotensin II Receptor Blockers with Mortality Among Patients With Hypertension Hospitalized With COVID-19. *Circ Res* 2020 Apr 17. doi: 10.1161/CIRCRESAHA.120.317134.
6. Cui S, Chen S, Li X, et al. Prevalence of venous thromboembolism in patients with severe novel coronavirus pneumonia. *J Thromb Haemost* 2020 Apr 9. doi: 10.1111/jth.14830. [Epub ahead of print]
7. Wang J, Hajizadeh N, Moore EE, et al. Tissue Plasminogen Activator (tPA) Treatment for COVID-19 Associated Acute Respiratory Distress Syndrome (ARDS): A Case Series. *J Thromb Haemost* 2020 Apr 8. doi: 10.1111/jth.14828.
8. Dattilo G, Borgia F, Guarneri C, et al. Cardiovascular Risk in Psoriasis: Current State of the Art. *Curr Vasc Pharmacol* 2019;17:85–91.
9. Dattilo G, Falanga G, Casale M, et al. Oral Anticoagulants: Old and New Therapy. In: Bernhardt LV (Ed.). *Advances in Medicine and Biology*. New York: Nova Science Publishers, Inc., 2015:13–70.
10. Casale M, Mezzetti M, Tulino V, et al. Therapy Of Cardiac Arrhythmias In Children: An Emerging Role Of Electroanatomical Mapping Systems. *Curr Vasc Pharmacol* 2018;16:528–533.
11. Casale M, Quattrocchi S, Bitto R, Dattilo G. Cardiac implantable devices and Takotsubo syndrome. A rare but potential eventuality. *Cor Vasa* 2018;60:e500–e502.
12. Scarano M, Gizzi G, Mastrodicasa D, Mantini C. Cardiac implantable electronic devices and chemotherapy: A risky combination. *Cor Vasa* 2018;60:e469–e471.
13. Testa S, Paoletti O, Giorgi-Pierfranceschi M, Pan A. Switch from oral anticoagulants to parenteral heparin in SARS-CoV-2 hospitalized patients [published online ahead of print, 2020 Apr 15]. *Intern Emerg Med* 2020;1–3. doi: 10.1007/s11739-020-02331-1
14. Tulino D, Imbalzano E, Casale M, et al. Treatment failure of low molecular weight heparin in diabetic patient. *Int J Cardiol* 2013;168:e63–e64.
15. Dattilo G, Lamari A, Di Bella G, et al. Treatment failure of low molecular weight heparin bridging therapy. *Int J Cardiol* 2013;167:e106–e107.