

## Symptomatic Ulcerative Carotid Plaque

Nicola Mumoli, MD; Marco Cei, MD; Claudio Invernizzi, MD

A 65-year-old man with a history of smoking, hypertension, and diabetes mellitus presented because of sudden-onset left hemiparesis. On admission, neurological examination disclosed a mild left-sided weakness, a normal consciousness level, and a right carotid bruit. The blood pressure, ECG, echocardiogram, and laboratory studies were all unremarkable. He was taking daily aspirin, enalapril, and metformin. Magnetic resonance imaging of the brain revealed a right small cerebral infarct.

Intracranial stenotic lesion was not detected by magnetic resonance angiography. Carotid ultrasonography showed a large heterogeneous plaque with ulceration (arrow) and stenosis of 70% at the bifurcation of the right common carotid artery (Figure 1). The symptoms and signs improved gradually during a period of 4 days.

Six weeks after the stroke, the patient underwent elective right carotid endarterectomy, and the arteriotomy was closed with a Dacron patch (Figure 2).

No neurological deficits or cranial nerve palsy were noted postoperatively. The patient was discharged, and 11 months after the operation no new neurological events have occurred.

Plaque rupture may play an important role in acute cerebral events,<sup>1</sup> just as it has been shown to play a role in acute coronary syndromes.<sup>2</sup> Recent technological advances

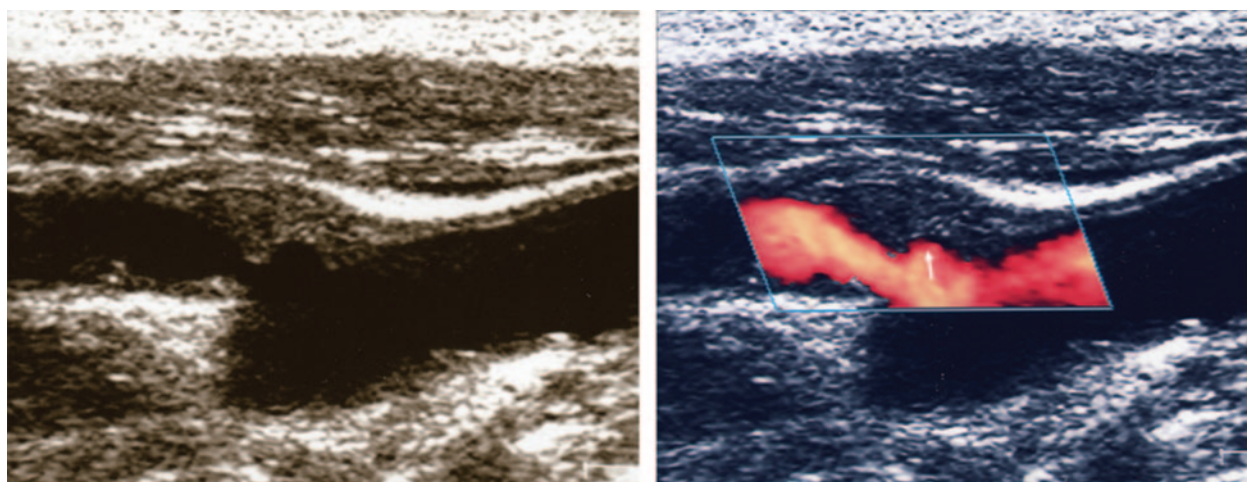
in ultrasonography<sup>3</sup> could provide a noninvasive diagnostic modality of atherosclerotic lesion characterization by clearly visualizing flow conditions and large neck vessel morphology that isn't currently possible in coronary arteries without invasive procedures.<sup>4</sup> Further studies are needed, however, to clarify if the early recognition of carotid plaque rupture should lead to early nonconservative therapeutic strategies.

### Disclosures

None.

### References

1. Eliasziw M, Streifler JY, Fox AJ, Hachinski VC, Ferguson GG, Barnett HJ. Significance of plaque ulceration in symptomatic patients with high-grade carotid stenosis: North American Symptomatic Carotid Endarterectomy Trial. *Stroke*. 1994;25:304–308.
2. Gössl M, Versari D, Hildebrandt H, Mannheim D, Olson ML, Lerman LO, Lerman A. Vulnerable plaque: detection and management. *Med Clin North Am*. 2007;91:573–601.
3. Gillard JH. Advances in atheroma imaging in the carotid. *Cerebrovasc Dis*. 2007;24 (Suppl 1):40–48.
4. Schaar JA, Mastik F, Regar E, den Uil CA, Gijzen FJ, Wentzel JJ, Serruys PW, van der Steen AF. Current diagnostic modalities for vulnerable plaque detection. *Curr Pharm Des*. 2007;13:995–1001.



**Figure 1.** Ultrasound B-mode image (left) and power Duplex image (right) showing a large heterogeneous plaque with ulceration (arrow) and stenosis of 70% at the bifurcation of the right common carotid artery.

From the Departments of Internal Medicine (N.M., M.C.) and Vascular Surgery (C.I.), Ospedale Civile di Livorno, Livorno, Italy.

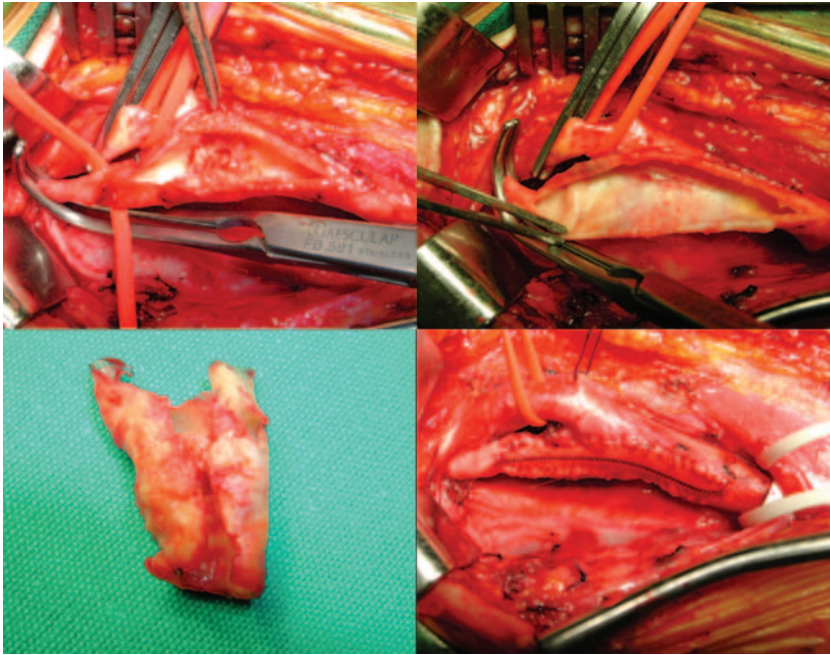
Correspondence to Nicola Mumoli, MD, Department of Internal Medicine, Ospedale Civile di Livorno; viale Alfieri 36, 57100 Livorno, Italy. E-mail [nimumoli@tiscali.it](mailto:nimumoli@tiscali.it)

(*Circulation*. 2008;118:2594–2595.)

© 2008 American Heart Association, Inc.

*Circulation* is available at <http://circ.ahajournals.org>

DOI: 10.1161/CIRCULATIONAHA.108.797977



**Figure 2.** Elective right carotid endarterectomy and closed arteriotomy with a Dacron patch.

## Symptomatic Ulcerative Carotid Plaque Nicola Mumoli, Marco Cei and Claudio Invernizzi

*Circulation*. 2008;118:2594-2595

doi: 10.1161/CIRCULATIONAHA.108.797977

*Circulation* is published by the American Heart Association, 7272 Greenville Avenue, Dallas, TX 75231

Copyright © 2008 American Heart Association, Inc. All rights reserved.

Print ISSN: 0009-7322. Online ISSN: 1524-4539

The online version of this article, along with updated information and services, is located on the  
World Wide Web at:

<http://circ.ahajournals.org/content/118/24/2594>

**Permissions:** Requests for permissions to reproduce figures, tables, or portions of articles originally published in *Circulation* can be obtained via RightsLink, a service of the Copyright Clearance Center, not the Editorial Office. Once the online version of the published article for which permission is being requested is located, click Request Permissions in the middle column of the Web page under Services. Further information about this process is available in the [Permissions and Rights Question and Answer](#) document.

**Reprints:** Information about reprints can be found online at:  
<http://www.lww.com/reprints>

**Subscriptions:** Information about subscribing to *Circulation* is online at:  
<http://circ.ahajournals.org/subscriptions/>