



## On the cutting edge: anterior transpetrosal approach – the middle fossa approach. Clinical application, surgical anatomy, and results

Luciano Mastronardi<sup>1,3,✉</sup>, Luc De Waele<sup>2</sup>, Takanori Fukushima<sup>3</sup>

<sup>1</sup>*Division of Neurosurgery, Department of Surgical Specialties, San Filippo Neri Hospital/ASL Roma, Italy  
Via Giovanni Martinotti, 20 – 00135 Roma, Italy*

<sup>2</sup>*F.R.I.E.N.D.S. International Education Group, Ghent, Belgium  
S'Gravenstraat nr., 188 9810 Nazareth, Belgium*

<sup>3</sup>*Department of Neurosurgery, Carolina Neuroscience Institute, Raleigh, North Carolina, USA  
4030 Wake Forest Rd, Raleigh, NC 27609, USA*

### Abstract

Nowadays, the middle cranial fossa approach (MFA) is one of the most useful operative procedures in skull base surgery. When performed properly, it provides a relevant adjunct to treating complex skull base lesions. MFA allows one to resect the anterior petrous bone (anterior petrosectomy), open the internal auditory canal (IAC), and access the lateral wall of the cavernous sinus and the infratemporal fossa. Knowledge of the anatomical structures of the middle cranial fossa and cavernous sinus is mandatory to perform this approach. We report in detail the standard extradural subtemporal route for the anterior petrosectomy and MFA. The main indications for this approach are intradural lesions localized medially to the trigeminal nerve, subtemporal interdural and extradural tumours and neoplasms involving the IAC (including IAC pathology). Moreover, we describe the extended middle fossa approach, consisting in the anterior extension of MFA, indicated for intradural tumours of the superior cerebello-pontine angle and of prepontine clivus (retroclival lesions, ventral brainstem tumours, and cavernomas), for infratemporal fossa lesions, and cavernous sinus pathologies. Even if the anatomical landmarks of the middle cranial fossa and lateral skull base are well known, training with cadaver dissection is necessary for any skull-base surgeon to perform an optimum MFA. The cadaver-lab dissections simplify the learning of anatomical structures, and prepare the surgeon properly for this technically challenging approach.

**Keywords:** skull base surgical anatomy; anterior petrosal approach; middle fossa approach; cavernous sinus; clinical application

#### MeSH terms:

CRANIAL FOSSA, MIDDLE – ANATOMY & HISTOLOGY

CRANIAL FOSSA, MIDDLE – SURGERY

**For citation:** Mastronardi L., De Waele L., Fukushima T. On the cutting edge: anterior transpetrosal approach – the middle fossa approach. Clinical application, surgical anatomy, and results. *Sechenov Medical Journal*. 2021; 12(4): 19–28. <https://doi.org/10.47093/2218-7332.2021.12.4.19-28>

#### CONTACT INFORMATION:

**Luciano Mastronardi**, MD, PhD, Division of Neurosurgery, Department of Surgical Specialties, San Filippo Neri Hospital / ASL Roma, Italy.

**Address:** Via Reno 14, 00198, Roma, Italy.

**Tel.:** +39 06 33062318

**E-mail:** [mastro@tin.it](mailto:mastro@tin.it)

**Conflict of interests.** The authors declare that there is no conflict of interests.

**Financial support.** The study was not sponsored (own resources).

**Received:** 16.07.2021

**Accepted:** 23.08.2021

**Date of publication:** 29.11.2021

## На переднем крае: передний транспетрозальный доступ – доступ к средней черепной ямке. Клиническое применение, хирургическая анатомия и результаты

Л. Мастронарди<sup>1,3,✉</sup>, Л. де Ваэль<sup>2</sup>, Т. Фукушима<sup>3</sup>

<sup>1</sup> Отделение нейрохирургии, отделение хирургических специальностей, больница «Сан Филиппо Нери» / ASL Рим

Ул. Джованни Мартинонни, 20 – 00135 Рим, Италия

<sup>2</sup> Международная образовательная группа F.R.I.E.N.D.S., Гент, Бельгия  
Гравенстаат № 188 9810 Назарет, Бельгия

<sup>3</sup> Отделение нейрохирургии Института нейронаук штата Северная Каролина, Роли  
4030 Уэйк Форест роуд, Роли, Северная Каролина 27609, США

### Аннотация

В настоящее время доступ к средней черепной ямке (СЧЯ) является одним из наиболее эффективных в хирургии основания черепа. При правильном выполнении этот доступ является важной опцией хирургического лечения сложной патологии основания черепа.

Доступ к СЧЯ позволяет провести резекцию переднего края каменистой части височной кости (передняя петрозэктомия), открыть внутренний слуховой проход (ВСП), получить доступ к латеральной стенке кавернозного синуса и подвисочной ямке. Знание анатомических структур СЧЯ и кавернозного синуса является обязательным для выполнения этого доступа. Мы подробно описываем стандартный экстрадуральный субтемпоральный доступ для проведения передней петрозэктомии к СЧЯ. Основными показаниями для этого доступа являются интрадуральные поражения, локализованные медиально к тройничному нерву, субтемпоральные интрадуральные и экстрадуральные опухоли и новообразования, вовлекающие ВСП (включая и его патологию). Кроме того, мы описываем расширенный доступ к СЧЯ, заключающийся в ее переднем расширении, который показан при интрадуральных опухолях верхней части мосто-мозжечкового угла и препонтинной части ската (ретрокливальные поражения, вентральные опухоли ствола мозга и каверномы), при поражениях подвисочной ямки и патологии кавернозного синуса. Даже если анатомические ориентиры СЧЯ и латерального основания черепа хорошо изучены, для наиболее качественного выполнения доступа к СЧЯ любому хирургу, специализирующемуся на вмешательствах в области основания черепа, необходимо обучение на диссекционных кадавер-курсах. Отработка практических навыков на кадаверном материале значительно упрощает изучение анатомических структур, должным образом подготавливая специалиста к этому технически сложному доступу.

**Ключевые слова:** хирургическая анатомия основания черепа; передний петрозальный доступ; доступ к средней черепной ямке; кавернозный синус; клиническое применение

### Рубрики MeSH:

ЧЕРЕПНАЯ ЯМКА СРЕДНЯЯ – АНАТОМИЯ И ГИСТОЛОГИЯ

ЧЕРЕПНАЯ ЯМКА СРЕДНЯЯ – ХИРУРГИЯ

**Для цитирования:** Мастронарди Л., де Ваэль Л., Фукушима Т. На переднем крае: передний транспетрозальный доступ – доступ к средней черепной ямке. Клиническое применение, хирургическая анатомия и результаты. Сеченовский вестник. 2021; 12(4): 19–28. <https://doi.org/10.47093/2218-7332.2021.12.4.19-28>

### КОНТАКТНАЯ ИНФОРМАЦИЯ:

**Мастронарди Л.**, MD, PhD, руководитель отделения нейрохирургии, отделение хирургических специальностей, больница «Сан Филиппо Нери» / ASL Рим, Италия

**Адрес:** ул. Джованни Мартинонни, 20 – 00135 Рим, Италия

**Тел.:** +39 06 33062318

**E-mail:** [mastro@tin.it](mailto:mastro@tin.it)

**Конфликт интересов.** Авторы заявляют об отсутствии конфликта интересов.

**Финансирование.** Исследование не имело спонсорской поддержки (собственные ресурсы).

Поступила: 16.07.2021  
 Принята: 23.08.2021  
 Дата печати: 29.11.2021

### List of abbreviations

AE – arcuate eminence  
 CSF – cerebrospinal fluid  
 CT – computed tomography

GG – geniculate ganglion  
 GSPN – greater petrosal superficial nerve  
 MFA – middle fossa approach  
 MMA – middle meningeal artery

HIGHLIGHTS	КЛЮЧЕВЫЕ ПОЛОЖЕНИЯ
The middle cranial fossa approach is one of the most useful operative procedures in skull base surgery. It provides a relevant adjunct for treating complex skull base lesions.	Доступ к средней черепной ямке является одним из наиболее эффективных в хирургии основания черепа. Этот доступ является важной опцией хирургического лечения сложной патологии основания черепа.
The middle cranial fossa approach allows one to resect the anterior petrous bone (anterior petrosectomy), open the internal auditory canal, and access the lateral wall of the cavernous sinus and the infratemporal fossa.	Доступ к средней черепной ямке позволяет провести резекцию переднего края каменистой части височной кости (передняя петрозэктомия), открыть внутренний слуховой проход, получить доступ к латеральной стенке кавернозного синуса и подвисочной ямке.
The main indications for this approach are intradural lesions localized medially to the trigeminal nerve, subtemporal interdural and extradural tumours and neoplasms involving the internal auditory canal.	Основными показаниями для этого доступа являются интрадуральные поражения, локализованные медиально к тройничному нерву, субтемпоральные интрадуральные и экстрадуральные опухоли и новообразования, вовлекающие внутренний слуховой проход.
The extended middle fossa approach, consisting in the anterior extension of the middle cranial fossa approach, indicated for intradural tumours of the superior cerebello-pontine angle and of prepontine clivus (retroclival lesions, ventral brainstem tumours, and cavernomas), for infratemporal fossa lesions, and for cavernous sinus pathologies.	Расширенный доступ к средней черепной ямке, заключающийся в переднем расширении доступа к ней, показан при интрадуральных опухолях верхней части мосто-мозжечкового угла и препонтиной части ската (ретрокливальные поражения, вентральные опухоли ствола мозга и каверномы), при поражениях подвисочной ямки и патологии кавернозного синуса.

The anterior transpetrosal approach is an extradural subtemporal route and consists of exposure of the middle cranial fossa (middle fossa approach: MFA) and anterior petrosectomy.

### CLINICAL APPLICATION

Intradural lesions medial to the trigeminal nerve and ventral to the internal auditory canal are the most common pathologies treated with the MFA. The pathologies occupying the IAC itself (mostly in patients with normal hearing) are included among the indications [1–7].

The combination of MFA with mastoidectomy, retrosigmoid suboccipital approach, and supramastoid drilling allows one to perform the “combined petrosal approach” to resect petroclival tumours, medial cerebellopontine angle, and posterior cavernous sinus [2, 3, 6, 8]. In particular, the combined petrosal approach is used for:

- large sphenopetroclival meningiomas.
- transtentorial (supra- and infra-tentorial) meningiomas and other tumours, and
- vertebrobasilar aneurysms [1–10].

The “extended middle cranial fossa exposure” consists of the anterior extension of the anterior transpetrosal extradural approach. This extended extradural subtemporal route is indicated for:

- intradural lesions of superior cerebello-pontine angle and prepontine clivus (retroclival tumours, ventral brainstem tumours and cavernomas).
- by-pass of the petrous segment of the internal carotid artery, at the level of Kawase’s triangle of cavernous sinus.
- cavernous sinus tumours [5, 6].

For the training of this technically complex approach and to properly recognize the anatomy, both in cadaverlab hands-on dissections and in the practice on clinical cases, we have developed a schematic method [8], which is useful during the learning-curve period necessary to adequately prepare the anterior transpetrosal subtemporal approach.

### SURGICAL ANATOMY AND TECHNIQUE

Fukushima’s lateral position is our preferred surgical position for several lateral and posterior skull base procedures, including MFA [6]. In particular, the sagittal plane of the head positioned parallel to the floor and three movements of the head are essential: (1) contralateral rotation, (2) mild flexion on the chin, and (3) vertex down.

Supine position is a possible alternative, with the head rotated to the opposite side of the lesion, and as parallel to the floor as possible.

For a standard MFA, an 8–10 cm preauricular linear or “lazy S” incision is performed behind the hairline,

<1 cm anteriorly to the tragus, starting from the inferior border of the root of zygoma. A 2-layer dissection of galea and temporal muscle is performed, preparing a vascularized pericranial flap useful for closure.

A squared craniotomy (maximum 4×4 cm) is obtained, followed by temporal groove drilling [6, 11]. This exposure allows a subtemporal-extradural working route, parallel to the lateral skull base. The extradural and “interdural” [10] exposure of middle fossa nerve and vascular anatomy starts with the identification and elevation of the “dura propria” of the basal portion of the temporal lobe. This is the key-point for the exposure of all anatomical structures in this region.

During the dissection, the dura propria must be separated from a second layer of fibrous dura that covers: a. the superior orbital fissure, b. the second and third branches of trigeminal nerve, and c. the gasserian ganglion. A fatty inner reticular layer (usually not present in the cadaver specimens) is present in this virtual plane between the two layers of dura.

A detailed knowledge of MFA anatomy is essential to avoid damaging any of the neurovascular structures present in this area [6, 8–13]. It is mandatory to recognize the position of:

- superior orbital fissure, containing the 3rd, 4th, and first branch (V1) of 5th cranial nerve;
- C4, C5, and C6 segments of ICA, according to Fukushima’s classification;
- sixth cranial nerve, in-between V1 and V2 (first and second branch of trigeminal nerve), coming from the posterior fossa through the Dorello’s canal at the level of petrous apex and crossing the C4 segment of ICA;
- V1, V2 and V3 (the three branches of trigeminal nerve) and the Gasserian ganglion located in the Meckel’s cave. Gasserian ganglion cover the C5 segment of ICA;
- greater petrosal superficial nerve (GSPN), usually on the dorsal bony canal covering the C6 segment of ICA. GSPN is a motor and parasympathetic branch of the facial nerve and it is essential to identify this landmark as soon as possible. It starts from the geniculate ganglion (GG, located along the arcuate eminence) and runs perpendicularly with the main axis of V3, crossing this branch of trigeminal nerve around halfway point between the Gasserian ganglion and the foramen ovale. GSPN passes ventrally to V3, in the direction of infratemporal fossa to join the deep petrosal nerve. From the union of these two nerves originates the vidian nerve (supplies ganglionic fibres for the lacrimal gland);
- C6 portion of carotid artery is sometime covered by a thin layer of bone, but frequently it is naked and the GSPN runs immediately over it;
- IAC, in the depths of the “rhomboid fossa”.

The middle meningeal artery (MMA) and tensor tympani muscle are two fundamental landmarks for

starting the interdural dissection. And, the MMA must be interrupted to split the dura propria from the dura covering all neuroanatomical structures of the middle fossa. According to El-Khouly et al. [14] the closer the interruption of the MMA to the foramen spinosum, the higher the possibility of a facial nerve ischemic palsy. In accordance with the results observed in the serial cadaveric dissections, the closure of the MMA at more than 10mm from the foramen spinosum allows one to leave the proximal part of MMA attached to bone. This enables the sparing of several petrosal arteries arising within the first 10mm after the exit of the MMA from the foramen spinosum and feeding the facial nerve and the GG. Therefore, the risk of vascular damaging the facial nerve during dura propria elevation could be much lower if the dura is split in two layers, leaving the outer layer attached to the middle fossa floor around the proximal 1cm of MMA, between foramen spinosum (lateral) and the hiatus of GSPN and arcuate eminence (AE) (medial).

Once the MMA has been divided, it is possible to start the interdural dissections [10] and elevate the dura propria from the layer close to the bone and covering the cranial nerves. At this point it is possible to expose the V2, V3 and the GSPN, starting posteriorly from the GG (located on the arcuate eminence), covering the C6 segment of the ICA, and running anteriorly crossing V3.

Attention must be paid required during the interdural dissection of the MFA due to the frequent anatomical variations. At first, GG, GSPN, and C6 segment of ICA are not always covered by bone [6, 11]: GG is not covered by bone in 15–17% of cases and the length of the bony canal covering the GSPN from the GG is very variable, ranging from 0 to 7.6 mm (mean 3.8 mm) [11].

The petrous ICA can be directly exposed along the carotid canal in 20% of cases due to the absence of bone in the canal roof [6, 11], and to safely locate it, the GSPN needs to be searched for just below the posterior border of V3, halfway between foramen ovale (mean distance 7.3 mm) and the gasserian ganglion [6, 11]. The exposure of the GSPN is a crucial landmark: following the nerve posteriorly it is possible to locate the GG and the fallopian hiatus. It is also the best reference for the ICA, covering its horizontal C6 segment. In clinical cases, it is very useful to confirm the ICA with intraoperative micro-doppler.

Going-on with elevation of dura propria, it is possible to expose:

- the AE, that usually overlies the superior semi-circular canal [11, 12];
- the third branch of trigeminal nerve (V3), from the foramen ovale to the gasserian ganglion;
- V2 and V1;
- the porous trigeminus.

We normally suggest that, to mobilize anteriorly the V2 and V3, and minimize their traction and the possible damages of their fibres, it is important to drill to widen the foramen rotundum and foramen ovale.



The next steps of MFA dissection are to identify the (1) “rhomboid fossa” and (2) position of the IAC (Fig. 1).

The “rhomboid fossa” is a rhomboid-shaped bony area of the middle fossa to be drilled away to remove the bone of petrous apex. Its borders and limits are:

- petrous ridge and superior petrosal sinus, from the porous trigeminus to the AE;
- AE (from the petrous ridge to the GG);
- GSPN (from the intersection with the GG and AE to V3 junction); and
- posterior border of V3 (from the intersection with the GSPN to the porous trigeminus).

Several rules have been proposed to locate the position of the IAC inside the rhomboid fossa [3, 4, 6, 8, 13]. The method suggested by Y. Cokkeser et al. [13] seems to be the safest and easiest to remember (also called “Sanna’s method”). The authors evaluated and measured the medial and lateral ends of the IAC on 20 cadaveric temporal bones [13]. Measurements were obtained at three levels: (1) the width of IAC on the fundus, (2) the width of IAC on the porous, and (3) a safe distance around the IAC on meatal level.

The mean width of the IAC on the porous is over 3-times larger than the mean width at the level of Bill’s bar (between GG and AE). The width of the medial safe area around the IAC is over 7-times the width of the IAC at the lateral end. To obtain a quick and safe direct exposure of the IAC, and minimize the possible handling of the facial nerve and the inner ear structures,

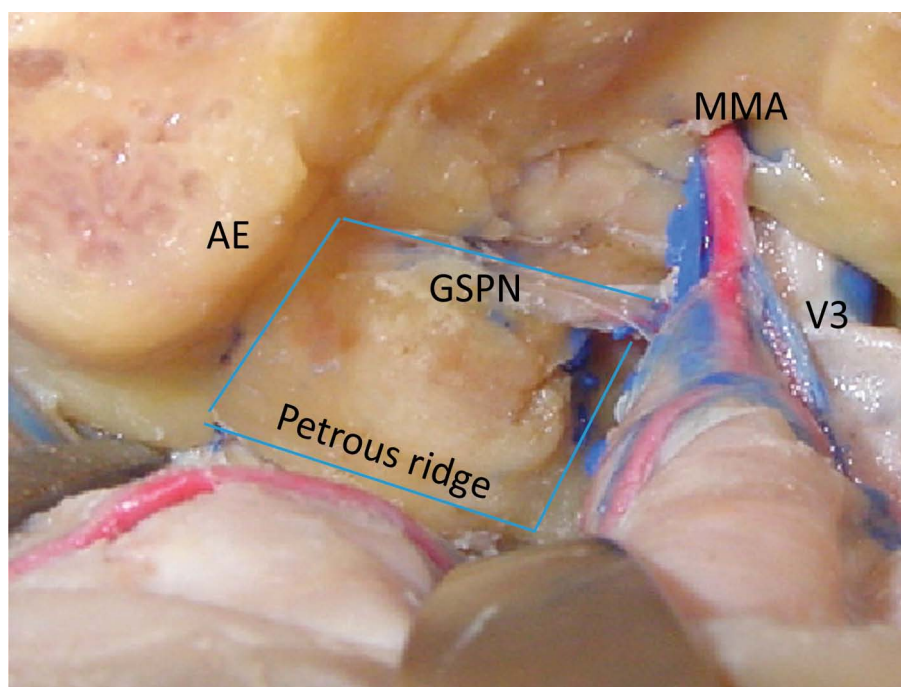
the Sanna’s Group suggested that the drilling of the roof of IAC should start from the medial area (petrous ridge), continuing the unroofing in the lateral direction [13].

Once the unroofing of IAC has been completed, one needs to drill the premeatal triangle (limited anteriorly by posterior border of V3) and the postmeatal triangle (limited posteriorly by the AE), exposing the posterior cavernous sinus (Fig. 2). The cancellous bone of the premeatal triangle must be drilled away until the posterior fossa dura is reached, and the inferior petrous sinus exposed, taking care to maintain the integrity of the cochlea and avoid damaging the ICA.

The cochlea is positioned at the corner between the GG, GSPN and IAC, about 4–5 mm ventral and anterior to the GG, and medial and posterior to the C6 segment of the ICA, at about 1 mm from the genu of intrapetrous horizontal and vertical segments of ICA [6]. The cochlea is covered by hard bone, very different from the cancellous bone of the premeatal triangle, and knowledge of the anatomical details of its position can be very helpful in avoiding damaging it and, making the patient deaf.

At this point, maximal bone removal is extended inferiorly, until the limit of the inferior petrosal sinus, and anteriorly (under the Gasserian ganglion), pointing the petrous apex and the clivus, following the course of ICA as far as the petrous apex (extended MFA) [6].

The dissection inside the cavernous sinus triangles and close to the superior orbital fissure allows

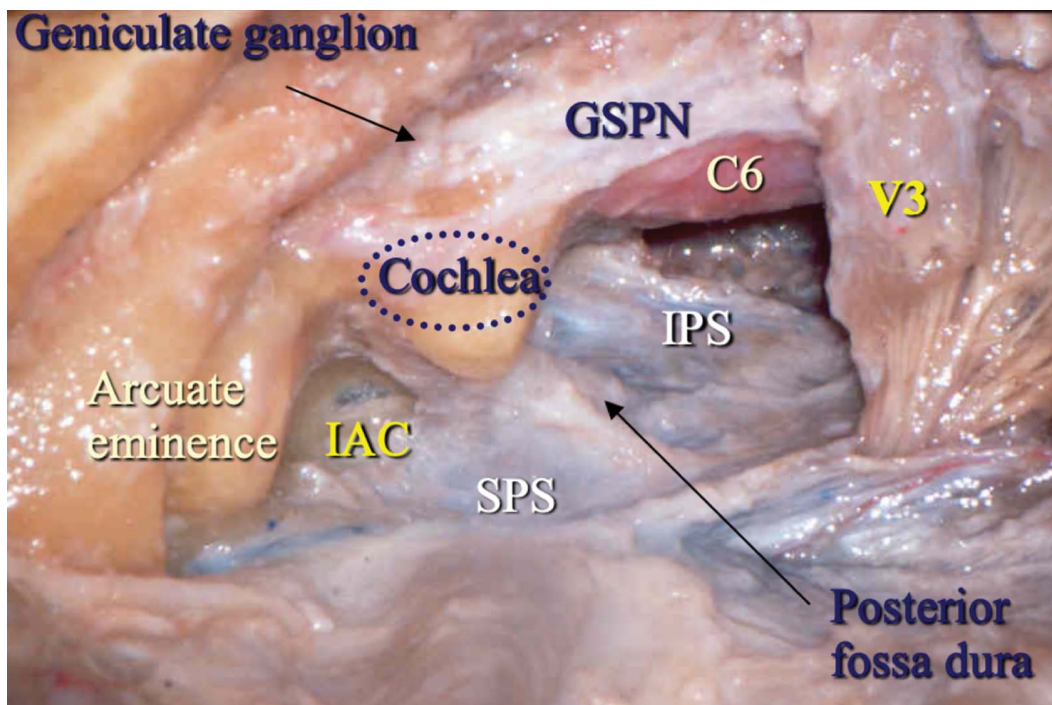


**FIG. 1.** Rhomboid fossa construct [6]

**РИС. 1.** Анатомия ромбовидной ямки [6]

Note: AE – arcuate eminence, GSPN – greater superficial petrosal nerve, MMA – middle meningeal artery, V3 – third branch of trigeminal nerve.

Примечание: AE (arcuate eminence) – дугообразное возвышение, GSPN (greater superficial petrosal nerve) – большой поверхностный каменистый нерв, MMA (middle meningeal artery) – средняя менингеальная артерия, V3 – третья ветвь тройничного нерва.



**FIG. 2.** Cadaveric injected specimen. Cancellous bone of rhomboid fossa drilled away until the petrous apex  
**РИС. 2.** Анатомический препарат с инъекцией сосудов цветным силиконом. Губчатая кость ромбовидной ямки высверлена до вершины пирамиды височной кости

Note: C6 – sixth tract of internal carotid artery, IAC – Internal auditory canal, IPS – inferior petrosal sinus, GSPN– greater superficial petrosal nerve, SPS – superior petrosal sinus, V3 – third branch of trigeminal nerve.

Примечание: C6 – шестой сегмент внутренней сонной артерии, IAC (internal auditory canal) – внутренний слуховой канал, IPS (inferior petrosal sinus) – нижний каменистый синус, GSPN (greater superficial petrosal nerve) – большой поверхностный каменистый нерв, SPS (superior petrosal sinus) – верхний каменистый синус, V3 – третья ветвь тройничного нерва.

visualization of V1, 3rd and 4th cranial nerves and, close to the cavernous segment of the ICA in-between V1 and V2 branches of trigeminal nerve, the 6th cranial nerve.

Both in cadaver specimens and in clinical practice, it is possible to follow the 6th nerve which runs close to the inferior petrosal sinus, inside Dorello's canal, from the posterior petro-sphenoidal (Gruber's) ligament to the superior orbital fissure [2, 3, 5, 6, 9–11].

### CADAVER HEAD STUDY AND TECHNICAL "TRICKS"

This anatomical study was performed in Skull Base Microdissection Laboratories during single dissections and skull-base courses in Florida and Las Vegas (USA), Arezzo and Roma (Italy), and Tyumen (Russia).

Dissections of 30 fixed human cadaver heads and 20 isolated temporal bones were performed to yield 80 sides studied. As described in a previously published article [8], in order to identify and expose all the anatomical structures contained in this anterior transpetrosal approach, two fans bordering each other at 90° can be drawn (Fig. 3) [8].

A simple trick to remember the different segments of the petrous and cavernous ICA, according to Fukushima's classification [6], is the following:

- C6 segment of the ICA lies under the GSPN,
- C5 segment under the 5th cranial nerve (V2–V3 and Gasserian ganglion), and
- C4–C3 segments under trochlear (4th) and the oculomotor (3rd) nerves, respectively (close to the superior orbital fissure).

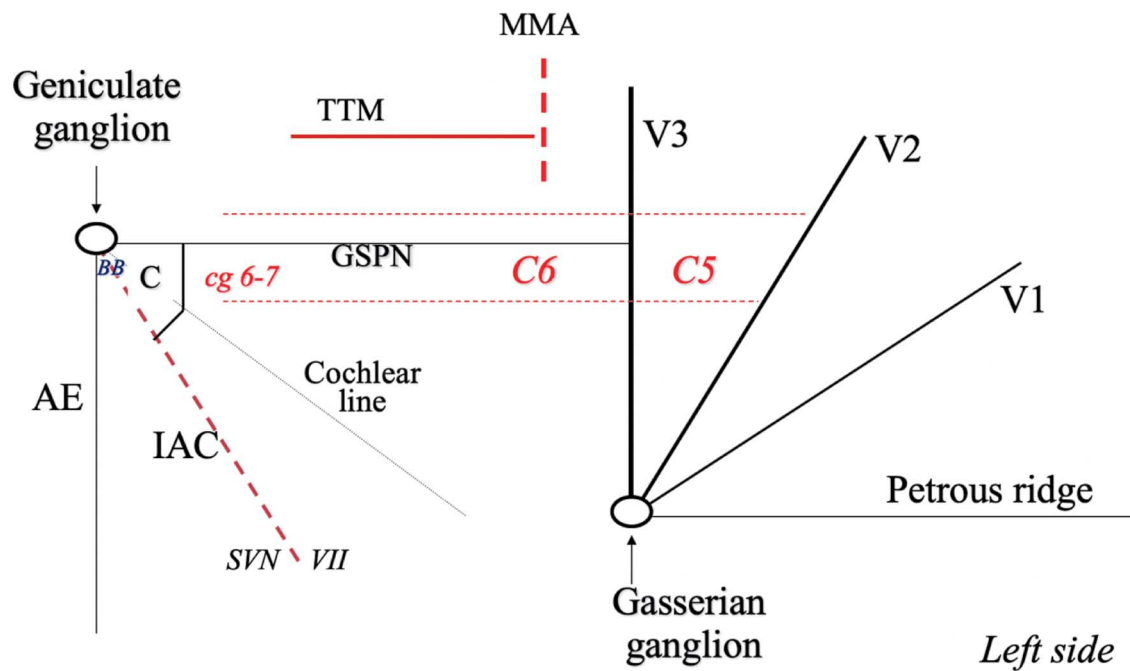
The base of the posterior fan can be the GG, and the base of anterior fan the Gasserian ganglion.

Posterior fan: proceeding in posterior–anterior and medial–lateral directions, the “rays” of the fan are: 0. AE, 1. the line running along the IAC, 2. the cochlear line (an ideal line passing through the cochlea), and 3. the GSPN. The cochlea lies in a deeper plane than the IAC and GSPN, in front of the loop horizontal and vertical segments of ICA [6].

Anterior fan: proceeding in posterior-anterior and medial-lateral directions, the rays are: 0. the petrous ridge, 1. first (V1), 2. second (V2), and 3. third (V3), branches of the trigeminal nerve.

The two fans border the rhomboid fossa in the following way: (1) GSPN–V3 junction; (2) lateral edge of porous trigeminus; (3) intersection of petrous ridge and AE; and (4) intersection of GSPN and AE [3, 4, 6, 8–14].

In conclusion, the anterior transpetrosal approach (MFA) provides a solid adjunct for treating complex



**FIG. 3.** Extradural middle fossa approach. Proposal of a learning method: the “rule of two fans” [8]

**РИС. 3.** Экстрадуральный доступ к средней черепной ямке. Метод обучения: «правило двух вееров» [8]

Note: AE – arcuate eminence, IAC – Internal auditory canal, SVN – superior vestibular nerve, VII – facial nerve, C – cochlea, cg – carotid genu (C6-C7), C6 – sixth tract of internal carotid artery, C5 – fifth tract of internal carotid artery, GSPN – greater petrosal superficial nerve, TTM – tensor tympany muscle, MMA – middle meningeal artery, V3 – third branch of trigeminal nerve, V2 – second branch of trigeminal nerve, V1 – first branch of trigeminal nerve.

Примечание: AE (arcuate eminence) – дугообразное возвышение, IAC (Internal auditory canal) – внутренний слуховой канал, SVN (superior vestibular nerve) – верхний преддверный корешок, VII – лицевой нерв, C – улитка, cg – колено сонной артерии (C6–C7), C6 – шестой сегмент внутренней сонной артерии, C5 – пятый сегмент внутренней сонной артерии, GSPN (greater petrosal superficial nerve) – большой поверхностный каменистый нерв, TTM (tensor tympany muscle) – мышца, напрягающая барабанную перепонку, MMA (middle meningeal artery) – средняя менингеальная артерия, V3 – третья ветвь тройничного нерва, V2 – вторая ветвь тройничного нерва, V1 – первая ветвь тройничного нерва.

skull-based meningiomas and tumours involving the middle fossa and the lateral skull base, and, although the anatomical landmarks of the lateral skull base are well known, our simple rules and tricks could be helpful for recognizing and exposing all vascular, nervous, osseous, and fibrous structures during the approach.

The cochlea, labyrinth, ICA, and 3rd, 4th, 5th, 6th, 7th, and 8th cranial nerves are all at risk during drilling and dissection [3, 6–14]. The practice and training of this technique on injected cadaver heads in the anatomical laboratories is mandatory before clinical application.

### RESULTS

Results of the MFA are strictly related to the pathology treated, to its size, to the WHO tumour grade, and to the possibility of radical removal (around 80% of cases) [1, 3, 4, 6, 7, 10, 15, 16].

The possible postoperative complications of this approach are [1, 3, 4, 6, 7, 10, 15, 16]:

- mortality: very low in experienced hands (< 0,2%);
- severe brain swelling and temporal lobe injuries: rare;
- cerebrospinal fluid (CSF) leakage and wound complications in 4–19% of patients, including cases with pneumocephalus;

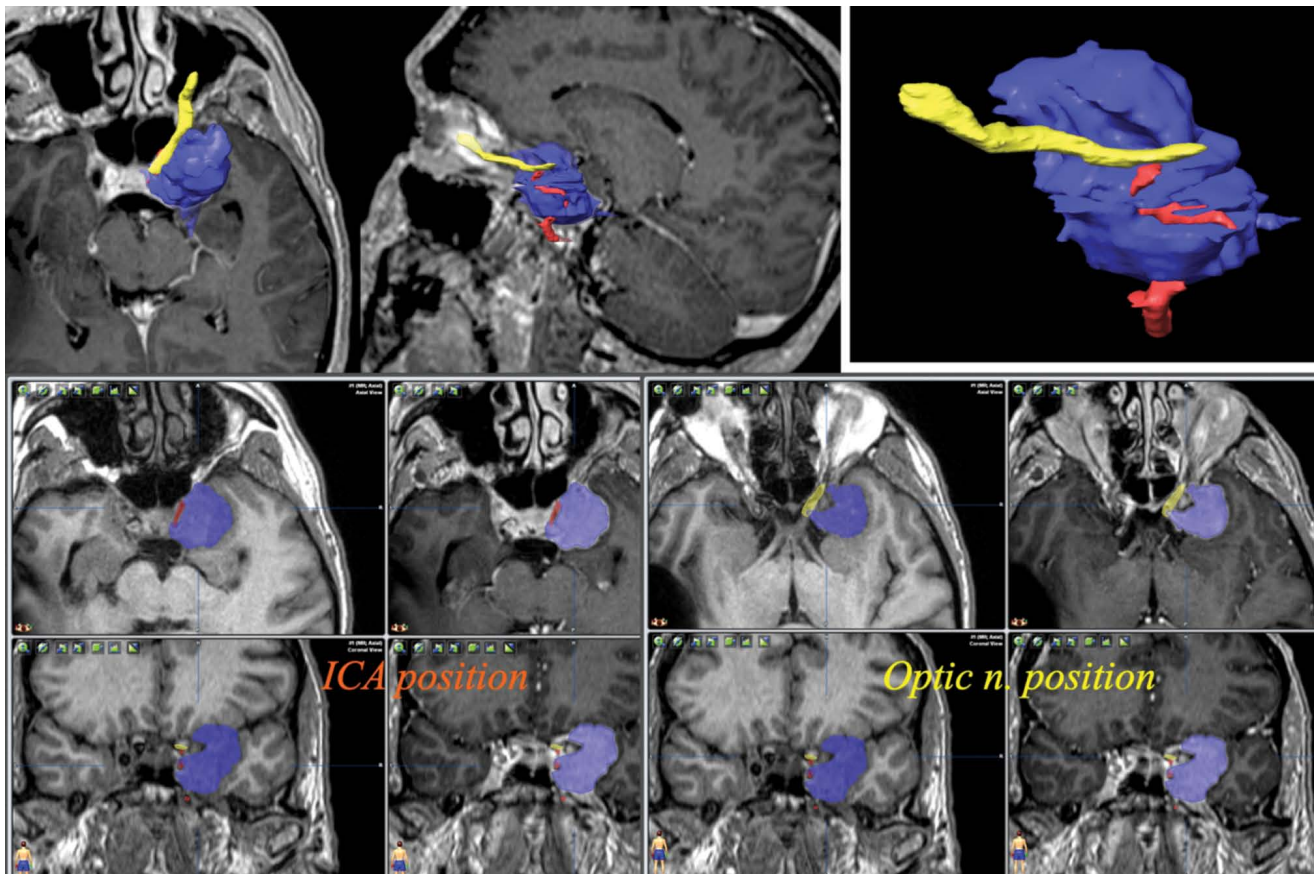
- intracranial subdural, extradural, or intracerebral haemorrhage in 0,4–2%;
- septic or aseptic meningitis: 1–7% of cases;
- deep venous thrombosis: 1–2% of cases;
- complete facial nerve and permanent deficit: 4–5%;
- hearing loss: 50% to 60% of cases with preoperative serviceable or socially useful hearing.
- facial numbness/hypesthesia: up to 2/3 of patients; facial pain: up to 80–90% of cases (both usually transient); permanent in <10% of cases;
- problems in jaw opening for reduced motor function of 5th cranial nerve: <3% of cases;
- diplopia (usually transient): up to 20% of cases, usually from transient palsy of abducens (6th) nerve.

### Intraoperative management

After reviewing the magnetic resonance image (MRI) and computed tomography (CT) scan and other possible exams (e.g., angiography), the positioning is done, a 3-pin head-holder is placed, and operative planning with neuronavigational equipment is performed (Fig. 4).

We place facial nerve free run neuromonitoring, bilateral ABR, endotracheal tube electrodes to map and monitor activities of the 7th, 8th, 9th, 10th cranial nerves





**FIG. 4.** Surgical planning with MRI of a right middle fossa meningioma invading the apex of orbit and cavernous sinus. Designations: Blue mass: tumour; Yellow irregular line: optic nerve; Red lines: different segments of internal carotid artery

**РИС. 4.** Предоперационное планирование с помощью магнитно-резонансной томографии для хирургического лечения менингиомы правой средней черепной ямки, инвазирующей вершину орбиты и кавернозный синус.

Обозначения: опухоль (синий), зрительный нерв (желтый), сегменты внутренней сонной артерии (красный)

intraoperatively. Moreover, SSEP and MEP are used for large tumours reaching the brain stem.

A 2-curved arms brain retractor system is fixed to the head holder. In patients with large tumours, a lumbar drainage is placed for possible multiple CSF-subtractions during surgery. Minimal shave, sterile scrub, and mark incision are performed.

After scalp and muscle incision and removal of bone flap, accurate haemostasis is performed with bipolar. Coagulation of MMA, about 1 cm after its exit from the foramen spinosum, is the first key point of this approach. The rest of the procedure, as described above, is mostly extradural. When we need to open the dura, we check with neuronavigation the position of tumours and cut meninges just close to it.

The removal of the tumour is performed with microsurgical technique, with dedicated dissectors, microscissors, microcurettes (ring and cup), Sonopet ultrasonic aspirator, and Hand-held laser fibre devices. Microdoppler probe is used to locate the position of big vessels, especially cavernous ICA. In some selected cases, a flexible endoscope can assist the microsurgical resection of "hidden" tumour residue. Frequent checks

with a navigational probe are performed during surgery to respect the preoperative planning.

Accurate final haemostasis is always performed. The closure of dura mater, if opened during the procedure, is performed with interrupted 4-0 silk suture. All exposed air cells are sealed with bone wax mixed with antibiotics in powder.

The bone flap is fixed with miniplates and miniscrews, and the muscle and fascia sutured with Vicryl interrupted sutures. The skin is closed with 2-0 or 3-0 reabsorbable or silk sutures. A subcutaneous drain is leaved rarely and removed after 2–3 days.

#### Postoperative care

After surgery, the patient is monitored in the neurosurgical intensive care unit for a minimum 24 hours. Blood pressure is controlled to prevent intracranial haemorrhages, if too high, and possible cranial nerves ischemia, if too low. A Neurologic examination is performed when the patient has recovered from the general anaesthesia and repeated hourly for the first 24 hours to identify any neurologic complication.



When placed in the operating room, the lumbar drain is either removed at the end of surgery or left clamped and removed after several days if there is no sign of CSF leak. High doses of steroids are administered for 48 hours, or extended up to 7 days, in cases of facial paralysis or signs of brain swelling. Prophylaxis of deep venous thrombosis is started the day after surgery. Droperidol or other similar medicines are used to treat possible nausea and vomiting.

After the second postoperative day, bladder catheter, arterial line, and electrocardiogram leads are removed, and the patient is transferred to a neurosurgical ward. Haemoglobin levels are verified every day in cases of significant intraoperative bleeding. When nausea has been resolved, a semi-liquid diet is started and usually well tolerated. A manual compression of both jugular veins (Queckenstedt test) is performed daily; if no CSF rhinorrhoea is present, the patient is allowed to sit up and then progressively encouraged to walk with assistance.

Before discharge, an MRI scan is always obtained to assess the radicality of surgery. The patient can be discharged if they can tolerate a regular diet, walk and have no CSF rhinorrhoea 4 or 5 days after the operation. They are instructed on wound care, daily temperature checks, activity, analgesia, and CSF leak prophylaxis. The patient is then seen at the outpatients' clinic 10 days after surgery to remove the sutures and final neurological examination.

### AUTHOR CONTRIBUTIONS

Luciano Mastronardi: study design, study concept, data extraction, data analysis, manuscript writing. Luc De Waele: study design, study concept. Takanori Fukushima: critical review of the manuscript, study supervision, study design, study concept. All authors participated in the discussion and editing of the work. All authors approved the final version of the publication.

### REFERENCES / ЛИТЕРАТУРА

- 1 *Al-Mefty O., Ayoubi S., Gaber E.* Trigeminal schwannomas: removal of dumbbell-shaped tumours through the expanded Meckel cave and outcomes of cranial nerve function. *J Neurosurg.* 2002 Mar; 96(3): 453–463. <https://doi.org/10.3171/jns.2002.96.3.0453>. PMID: 11883829.
- 2 *Day J.D., Fukushima T., Giannotta S.L.* Microanatomical study of the extradural middle fossa approach to the petroclival and posterior cavernous sinus region: description of the rhomboid construct. *Neurosurgery.* 1994 Jun; 34(6): 1009–1016; discussion 1016. <https://doi.org/10.1227/00006123-199406000-00009>. PMID: 8084385.
- 3 *Day J.D., Fukushima T., Giannotta S.L.* Innovations in surgical approach: lateral cranial base approaches. *Clin Neurosurg.* 1996; 43: 72–90. PMID: 9247796.
- 4 *Day J.D., Fukushima T.* The surgical management of trigeminal neuromas. *Neurosurgery.* 1998 Feb; 42(2): 233–240; discussion 240–241. <https://doi.org/10.1097/00006123-199802000-00015>. PMID: 9482173.
- 5 *Inoue T., Rhoton A.L. Jr, Thee D., Barry M.E.* Surgical approaches to the cavernous sinus: a microsurgical study. *Neurosurgery.* 1990 Jun; 26(6): 903–932. <https://doi.org/10.1097/00006123-199006000-00001>. PMID: 2362670.
- 6 *Sameshima T., Mastronardi L., Friedman A., Fukushima T. (eds)* Middle fossa dissection for extended middle fossa and anterior petrosectomy approach. *Fukushima's microanatomy and dissection of the temporal bone for surgery of acoustic neuroma, and petroclival meningioma, 2007, 2nd edn.* AF Neurovideo, Raleigh. P. 51–83.
- 7 *Samii M., Migliori M.M., Tatagiba M., Babu R.* Surgical treatment of trigeminal schwannomas. *J Neurosurg.* 1995 May; 82(5): 711–718. <https://doi.org/10.3171/jns.1995.82.5.0711>. PMID: 7714594.
- 8 *Mastronardi L., Sameshima T., Ducati A., et al.* Extradural middle fossa approach. Proposal of a learning method: the rule of two fans. Technical note. *Skull Base.* 2006 Aug; 16(3): 181–184. <https://doi.org/10.1055/s-2006-939676>. PMID: 17268592.
- 9 *Day J.D., Kellogg J.X., Tschabitscher M., Fukushima T.* Surface and superficial surgical anatomy of the posterolateral cranial base: significance for surgical planning and approach. *Neurosurgery.* 1996 Jun; 38(6): 1079–1083; discussion 1083–1084. PMID: 8727136.

### Complication management

Possible complications could be [15, 16]: life-threatening epidural hematoma, brain swelling, and pneumocephalus are very rare and must be immediately detected by CT scan. The patient must be treated medically and, if necessary, surgically and monitored in the neurosurgical intensive care unit for at least 24–48 hours.

Temporal lobe injuries with seizures, aphasia (if left-side approach), and other disturbances (auditory hallucinations, drowsiness) are very rare. They must be confirmed by CT scan and treated with antioedema and antiseizures medications.

CSF leak is observed in 10–15% of cases and must be treated with CSF lumbar drain and, in some cases, with revision surgery.

Severe infections (meningitis) are quite rare; diagnosis must be done by lumbar puncture and microbiological analysis of CSF. Prolonged culture-guided antibiotic therapy is always resolute.

Possible wound complications include infection, bleeding, and CSF collection under tension, which are prevented by accurate haemostasis and the closure of anatomical planes and treated with daily medications.


Other complications such as cystitis, deep venous thrombosis, bronchopneumonia, cardiopulmonary and cerebrovascular problems are prevented, diagnosed and treated as usual.


### ВКЛАД АВТОРОВ

Лучано Мастронарди: дизайн исследования, концепция исследования, получение данных, анализ данных, написание рукописи. Люк де Ваэль: дизайн исследования, концепция исследования. Таканори Фукушима: критический обзор рукописи, руководство исследованием, дизайн исследования, концепция исследования. Все авторы участвовали в обсуждении и редактировании работы. Все авторы одобрили окончательный вариант публикации.

- 10 Kawase T., van Loveren H., Keller J.T., Tew J.M. Meningeal architecture of the cavernous sinus: clinical and surgical implications. *Neurosurgery*. 1996 Sep; 39(3): 527–534; discussion 534–536. <https://doi.org/10.1097/00006123-199609000-00019>. PMID: 8875483.
- 11 Maina R., Ducati A., Lanzino G. The middle cranial fossa: morphometric study and surgical considerations. *Skull Base*. 2007 Nov; 17(6): 395–403. <https://doi.org/10.1055/s-2007-991117>. PMID: 18449332.
- 12 Kartush J.M., Kemink J.L., Graham M.D. The arcuate eminence. Topographic orientation in middle cranial fossa surgery. *Ann Otol Rhinol Laryngol*. 1985 Jan-Feb; 94 (1 Pt 1): 25–28. <https://doi.org/10.1177/000348948509400106>. PMID: 3970502.
- 13 Cokkeser Y., Aristegui M., Naguib M.B., et al. Identification of internal acoustic canal in the middle cranial fossa approach: a safe technique. *Otolaryngol Head Neck Surg*. 2001 Jan; 124(1): 94–98. <https://doi.org/10.1067/mhn.2001.111712>. PMID: 11228461.
- 14 El-Khouly H., Fernandez-Miranda J., Rhoton A.L. Jr. Blood supply of the facial nerve in the middle fossa: the petrosal artery. *Neurosurgery*. 2008 May; 62(5 Suppl 2): ONS 297–303; discussion ONS 303–304. <https://doi.org/10.1227/01.neu.0000326010.53821.a3>. PMID: 18596507.
- 15 Scheich M., Ginzkey C., Ehrmann Müller D., et al. Complications of the middle cranial fossa approach for acoustic neuroma removal. *J Int Adv Otol*. 2017 Aug; 13(2): 186–190. <https://doi.org/10.5152/iao.2017.3585>. PMID: 28816690.
- 16 Angeli S. Middle fossa approach: indications, technique, and results. *Otolaryngol Clin North Am*. 2012 Apr; 45(2): 417–438, ix. <https://doi.org/10.1016/j.otc.2011.12.010>. PMID: 22483825.

### INFORMATION ABOUT THE AUTHORS / ИНФОРМАЦИЯ ОБ АВТОРАХ

**Luciano Mastronardi** , MD, PhD, Division of Neurosurgery, Department of Surgical Specialties, San Filippo Neri Hospital / ASL Roma, Italy.  
ORCID: <https://orcid.org/0000-0003-0105-5786>


**Лучано Мастронарди** , доктор медицины, доктор философии, отделение нейрохирургии, департамент хирургических специальностей, госпиталь «Сан-Филиппо Нери»/ASL Рим, Италия.  
ORCID: <https://orcid.org/0000-0003-0105-5786>

**Luc De Waele**, MD, PhD, F.R.I.E.N.D.S. International Educational Group, Ghent, Belgium.  
ORCID: <https://orcid.org/0000-0002-3216-1007>

**Люк де Ваэль**, доктор медицины, доктор философии, Международная образовательная группа F.R.I.E.N.D.S., Гент, Бельгия.  
ORCID: <https://orcid.org/0000-0002-3216-1007>

**Takanori Fukushima**, MD, PhD, Department of Neurosurgery, Carolina Neuroscience Institute, Raleigh, North Carolina, USA.  
ORCID: <https://orcid.org/0000-0001-5586-9238>

**Таканори Фукушима**, доктор медицины, доктор философии, отделение нейрохирургии, Институт нейронаук штата Северная Каролина, г. Роли, США.  
ORCID: <https://orcid.org/0000-0001-5586-9238>

 Corresponding author / Автор, ответственный за переписку