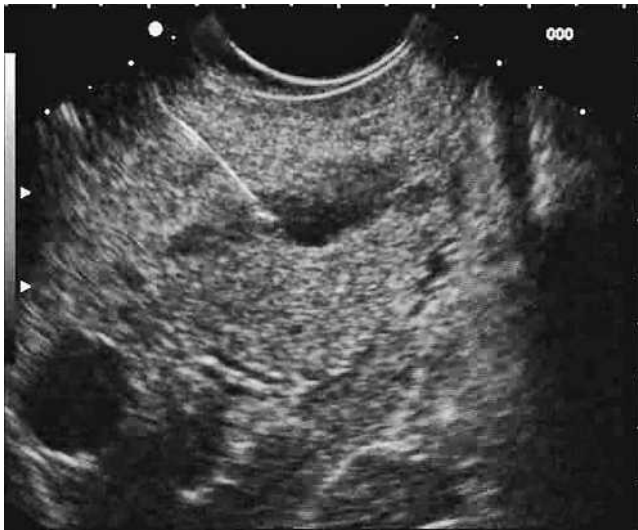

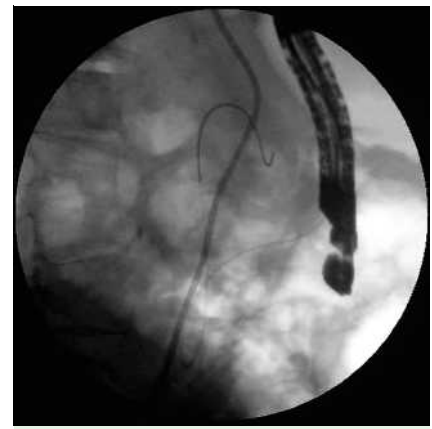
## EUS-guided rendezvous technique for difficult cannulation of an intradiverticular papilla

The intradiverticular papilla is a quite frequent finding, encountered in 5–23% of endoscopic retrograde cholangiopancreatography (ERCP) procedures [1]. When present, it can make cannulation of the common bile duct difficult, especially if the papilla is located deep in the diverticulum [2]. A 69-year-old woman was referred to our center for a second attempt at performance of ERCP after an earlier failure caused by a big duodenal diverticulum with a deeply located papilla. The patient had a diagnosis of intrahepatic abscess between hepatic segments VII and VIII, which had been unsuccessfully treated by antibiotic therapy and percutaneous drainage. With the patient under deep sedation (propofol) we tried to cannulate the papilla, but our attempt too

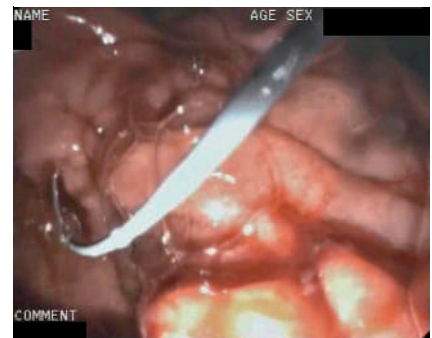was unsuccessful. An endoscopic ultrasound (EUS)-guided rendezvous drainage of the bile duct was performed (FG 36UX echoendoscope; Pentax GmbH, Hamburg, Germany), puncturing the common bile duct with a 22G needle (EUSN 1; Wilson–Cook, Winston Salem, NC, USA) (● Fig. 1). A 0.018-inch guide wire (Pathfinder; Boston Scientific, Natick, MA, USA) was passed through the needle until it reached the duodenum (● Fig. 2). Using a duodenoscope (ED 3480TK; Pentax), the wire was captured with a snare (● Fig. 3) and a 2-mm sphincterotome was placed over the wire (● Fig. 4). After sphincterotomy a 7-Fr pigtail nasobiliary drain was placed for drainage of the bile ducts.



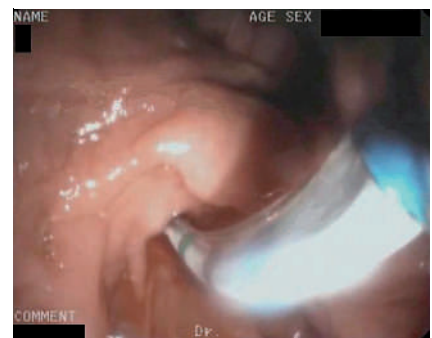**Fig. 1** Common bile duct punctured under endoscopic ultrasound guidance before placement of the guide wire.



**Fig. 2** Echoendoscope removal leaves the guide wire in place before introduction of the duodenoscope.



**Fig. 3** Guide wire inside the duodenum after snare capture.



**Fig. 4** Sphincterotome placed over the wire.

In patients with an intradiverticular papilla, the alternative for obtaining access to the biliary tree after ERCP failure is percutaneous transhepatic cholangiography using the rendezvous technique. This technique is associated with a complication rate ranging from 4% to 30%, with a mortality rate of 5.6% [2]. However, no complications were encountered either in our case or in a previously reported case where EUS-guided rendezvous technique was used [3]. If ERCP fails, EUS-guided rendezvous technique seems a practicable procedure to achieve selective cannulation of the common bile duct.

Endoscopy\_UCTN\_Code\_TTT\_1AS\_2AD

**B. Mangiavillano, P. G. Arcidiacono, S. Carrara, E. Masci, P. A. Testoni**  
Department of Gastroenterology and Gastrointestinal Endoscopy, IRCCS Vita-Salute San Raffaele University, San Raffaele Hospital Scientific Institute, Milan, Italy

#### References

- 1 *Ponchon T, Pilleul F.* Diagnostic ERCP. *Endoscopy* 2002; 34: 29–42
- 2 *Burmester E, Niehaus J, Leineweber T, Huetteroth T.* EUS-cholangio-drainage of the bile duct: report of 4 cases. *Gastrointest Endosc* 2003; 57: 246–251
- 3 *Lai R, Freeman ML.* Endoscopic ultrasound-guided bile duct access for rendezvous ERCP drainage in the setting of intradiverticular papilla. *Endoscopy* 2005; 37: 487–489

#### Bibliography

DOI 10.1055/s-2007-995548  
*Endoscopy* 2008; 40: E87–E88  
© Georg Thieme Verlag KG Stuttgart · New York ·  
ISSN 0013-726X

#### Corresponding author

**B. Mangiavillano, MD**  
Vita-Salute San Raffaele University  
IRCCS San Raffaele Hospital  
Division of Gastroenterology and Gastrointestinal  
Endoscopy  
Via Olgettina 60  
20132 Milan  
Italy  
Fax: +39-02-6432504  
mangiavillano.benedetto@hsr.it