



E-ISSN: 2616-3470

P-ISSN: 2616-3462

© Surgery Science

www.surgeryscience.com

2020; 4(2): 242-244

Received: 20-02-2020

Accepted: 22-03-2020

Ravikumar Gopalakrishnan

Professor and HOD of Plastic and Reconstructive Surgery,
Department of Plastic and Reconstructive Surgery,
Thanjavur Medical College, TN,
Dr. MGR Medical University,
Tamil Nadu, India

Manoharan Rajalingam

Assistant Professor of Plastic and Reconstructive Surgery,
Department of Plastic and Reconstructive Surgery,
Thanjavur Medical College, TN,
Dr. MGR Medical University,
Tamilnadu, India

Balamuralee Rajagunasekaran

Senior Resident in Plastic and Reconstructive Surgery,
Department of Plastic and Reconstructive Surgery,
Thanjavur Medical College., TN,
Dr. MGR Medical University,
Tamilnadu, India

Ramya Esakimuthu

Senior Resident in Plastic and Reconstructive Surgery,
Department of Plastic and Reconstructive Surgery,
Thanjavur Medical College., TN,
Dr. MGR Medical University,
Tamilnadu, India

Corresponding Author:

Ravikumar Gopalakrishnan

Professor and HOD of Plastic and Reconstructive Surgery,
Department of Plastic and Reconstructive Surgery,
Thanjavur Medical College, TN,
Dr. MGR Medical University,
Tamil Nadu, India

Role of post auricular flaps in acquired partial external auricular defects

Ravikumar Gopalakrishnan, Manoharan Rajalingam, Balamuralee Rajagunasekaran and Ramya Esakimuthu

DOI: <https://doi.org/10.33545/surgery.2020.v4.i2d.425>

Abstract

Background: Reconstruction of acquired partial external auricular defects is one of the most challenging procedures in plastic surgery. Acquired segmental defects of the external ear may be due to trauma, burn, previous surgery, or infection.

Aim: The aim of this study is to review the surgical method, its area of application, as well as advantages and pitfalls of reconstruction of the external ear with post auricular flaps.

Materials and Methods: 24 patients with acquired partial defects of external ear were taken up for the study. The defects were classified as upper, middle and lower third defects according to the area of involvement of external ear. All these patients were treated with post auricular flap of different sizes.

Results: 8 patients had upper third and 16 patients had middle third defects of the external ear. These defects were due to road traffic accidents in 18 patients (75%) and the remaining were due to human bites (25%). Most of these patients were under the influence of alcohol at the time of injury. The symmetry of the reconstructed ears was satisfactory, and the cosmetic appearance was acceptable for 18 patients. Three patients had marginal necrosis of the flap and required revision procedures. One patient had infection and graft loss in the donor area.

Conclusions: The post auricular flap is an ideal reconstructive option for partial acquired defects of the external ear because of its texture, matching colour, rich blood supply and proximity to the defect.

Keywords: Ear, Acquired defect, Postauricular Flap

Introduction

A deformity or partial defect of the auricle can detract from facial aesthetics and cause significant psychological morbidity for the patient [1, 2]. Acquired deformities of the ear are most frequently caused by bite injuries (35–72%) and less commonly by blunt trauma, tumors, thermal injury, and complications after otoplasty [3, 4]. Wounds due to human or animal bite is classified as highly contaminated wound and is mandatory to perform a thorough early debridement before definitive reconstruction is done later. Human bite is considered more contaminated than animal bite [5].

Accurate reconstruction of acquired auricular defects is one of the most challenging procedures in plastic surgery due to the unique shape of the auricle, the convexities and concavities of the cartilage, complex tissue structure, and auricle's tenuous blood supply [6, 7]. Consideration must be given not only to the defect size and location, but also to the quality and availability of the surrounding tissues [8].

Post auricular soft tissue is geographically located close to the ear, thus a skin flap of this region can easily be advanced to fill soft tissue defects. This area is well vascularised and its close proximity to the ear enables flap length and movement to be minimised, which reduces the vascular burden of the flap. The flap donor site scar can be easily concealed behind the ear [9].

Methods

This prospective study was conducted in the Department of Plastic and Reconstructive Surgery, Thanjavur Medical College, Tamilnadu, India between January 2017 and December 2019. 24 patients with post traumatic defects of external ear were taken up for the study. Institutional Ethics Committee approval was obtained. Written consent to participate in the study was obtained from all patients, including for the taking and use of photographs.

Detailed history was taken on the mechanism of injury, the time since injury and history of neurological deficits. Then, all the patients were subjected to a full general and local clinical examination to rule out other coexisting injuries. The age, sex, aetiology and mode of injury of the patients with external auricular defects were evaluated. The defects were classified as upper, middle and lower third defects according to the area of involvement of external ear.

All these patients were treated with post auricular flap of different sizes. Templates for ears undergoing reconstruction were tailored to the patient before surgery by placing a sheet of X-ray film against the normal ear to trace its anatomical landmarks and overall size. Missing segments were marked on the template. A two-staged posteriorly based retro auricular flap was designed slightly wider than the wound. In the first stage, a cutaneous advancement flap was created from the posterior scalp and advanced over the lateral aspect of the defect. In three cases of upper third defects conchal cartilage was implanted beneath the advancement flap during this initial procedure. During the second stage (3 -4 weeks later), the flap was divided from the scalp and then folded to cover the medial aspect of the cartilage graft. The postauricular donor site was covered with skin graft.

Postoperative complications like suture dehiscence, hematoma, wound infection, partial or total flap loss and graft loss were being monitored. Patients were on regular follow up from 6 months to 3 years.

Results

The age of the patients ranged from 26 to 55 years (Table 1). 20 patients were males and 4 patients were females (Graph 1). 8 patients had upper third and 16 patients had middle third defects of the auricle. These defects were due to road traffic accidents in 18 patients (75%) and the remaining were due to human bites (25%). Sixteen male patients were under the influence of alcohol at the time of injury.

14 patients had defect in the right ear and 10 patients had left ear defect. The time interval between the injury and reconstruction varied between 10 -21 days. 8 patients had upper third and 16 patients had middle third defects of the external ear. All human bite patients were taken up for reconstruction after adequate control of infection. The defects varied in size between 2.5cm and 3.5 cm and all these were covered with post auricular flaps (Figures. 1, 2, 3, 4).

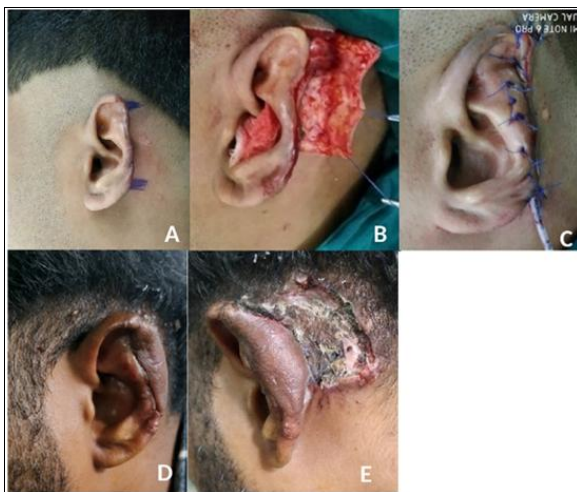

Fig 1: Post auricular flap for acquired middle third defect of external auricle A) Flap design B) Flap elevation C) Flap attachment after first stage D) and E) After second stage-flap division and in setting.

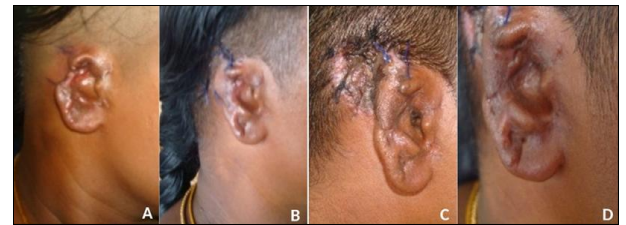

Fig 2: Post auricular flap for acquired upper third defect of external auricle in a female A) Flap design B) Flap attachment after first stage C) and D) After second stage-flap division and in setting.

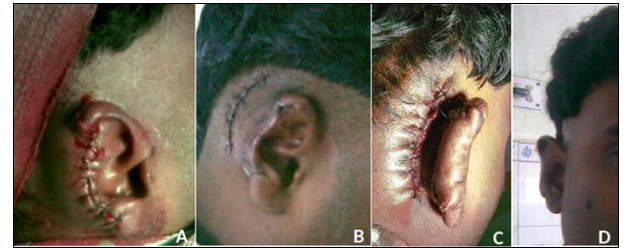

Fig 3: Post auricular flap for acquired middle third defect of right external auricle A) Flap attachment after first stage B) Flap delay C) and D) After second stage-flap division and in setting.

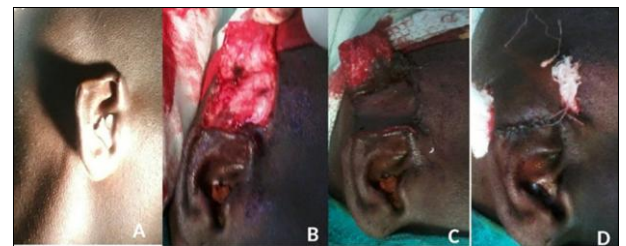

Fig 4: Post auricular flap for acquired upper third defect of right external auricle A) Defect B) Flap elevation C) Skin grafting for the secondary raw area D) Flap attachment.

Two patients had hematoma (8.33%), one patient had marginal flap necrosis (4.16%), three patients had partial loss of skin graft (12.5%) and three patients had infection (12.5%) (Table 2).

Table 1: Age wise distribution of patients

Age group (years)	Number of patients	Percentage
20-30	02	8.33 %
31-40	12	50 %
41-50	06	25 %
51-60	04	16.67 %

Table 2: Type of complications

Type of complications	Number of cases	Percentage
Haematoma	02	8.33%
Marginal flap necrosis	01	4.16%
Skin graft loss	03	12.5%
Infection	03	12.5%

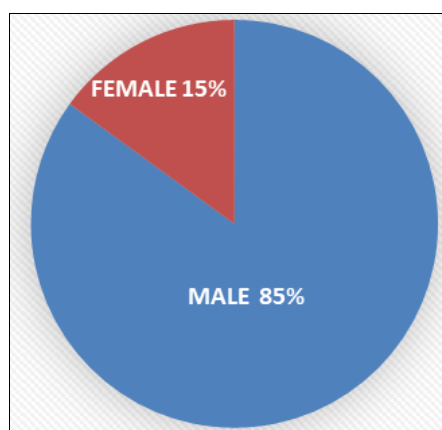
Discussion

Acquired partial defects of external ear are most commonly due to bites followed by road traffic accidents and burns.^[10] Reconstruction is difficult in post-burn deformed ears due to the densely scarred surrounding tissue and the tenuous blood supply^[11]. In our study most of the patients with acquired partial defects of the external ear were due to road traffic accidents. Alcohol abuse plays a major role in rash driving and violent human bites^[12]. In our study two third of the patients were under the influence of alcohol at the time of injury.

Classification of acquired defects of external ear: Various classifications of acquired auricular defects concentrate on either the localisation of the defect or the tissue affected [13]. Louis *et al.* Classified acquired defects of the external ear into cutaneous defects involving only the auricular skin, composite defects with defects of both the skin and the cartilage, and total or near-total defects requiring the reconstruction of the complete auricle. Composite defects can further be divided into marginal and nonmarginal defects; near-total and total auricular defects can be subdivided into those with healthy/intact surrounding tissue versus damaged surrounding tissue [13, 14]. When the defect is more than 2.5 cm skin flap is needed. When there is a loss of cartilage, pinna cartilage can be harvested from contralateral ear. In our study the defects varied in size between 2.5cm and 3.5 cm and all these were covered with post auricular flaps. The post auricular skin is considered a flap bank for ear reconstruction. It is an ideal donor site because it is richly vascularised, it is hidden behind the ear, and it is very similar to the skin of the ear and the face [15].

Learning Points in reconstruction of ear defects with post auricular flaps

- Correct approximation of flap length is important. In general, the flap will need to be at least 2 mm longer than the surgical defect to be filled. However, when it is intended to be rolled up to reconstruct a helical rim defect, it will need to be approximately 4 mm longer than the anticipated length.
- The use of a wide based pedicle will maximise the available blood supply from the richly vascular retro auricular skin.
- The tension placed along the flap can be reduced by immobilising the ear to the mastoid process by suture fixation. This prevents inadvertent pulling of the flap.
- It is important to leave the flap for at least 2 weeks before dividing it and detaching it from the retro auricular skin. This allows for adequate collateral revascularisation, which is essential in preventing flap loss.



Graph 1: Gender wise distribution of patients

Conclusion

Reconstruction of traumatic external auricular defects remains a challenging but rewarding aspect of facial reconstructive surgery. Consideration must be given not only to the defect size and location, but also to the quality and availability of the surrounding tissues. The post auricular flap is an ideal reconstructive option for partial acquired defects of the auricle because of its texture, matching colour, rich blood supply and proximity to the defect.

Acknowledgements

Authors would like to thank Department of Plastic and Reconstructive Surgery, Thanjavur Medical College, Tamilnadu, India.

Declarations

Funding: No funding sources

Conflict of interest: Nil

Ethical approval: The study was approved by the Institutional Ethics Committee

References

1. Horlock N, Vögelin E, Bradbury ET, Grobbelaar AO, Gault DT. Psychosocial outcome of patients after ear reconstruction: a retrospective study of 62 patients. *Ann Plast Surg.* 2005; 54(05):517-524
2. Renner G, Lane RV. Auricular reconstruction: An update. *Current Opinion in Otolaryngology & Head and Neck Surgery.* 2004; 12:277-280.
3. Steffen A, Katzbach R, Klaiher S. A comparison of ear reattachment methods: a review of 25 years since Pennington. *Plast Reconstr Surg.* 2006; 118(06):1358-1364.
4. Pearl RA, Sabbagh W. Reconstruction following traumatic partial amputation of the ear. *Plast Reconstr Surg.* 2011; 127(02):621-629.
5. Intan Friscilla Hakim, Prasetyanugraheni Kreshanti, Siti Handayani, Kristaninta Bangun. Reconstruction of Traumatic Partial Ear Amputations Using Two-Stage Skin Flap Pocket Technique. *Jur.Plast.Rekons.* 2013; 1:6-9.
6. Gault D. Post traumatic ear reconstruction. *J Plast.Reconstr. Aesthet. Surg.* 2008; 61(1):S5e12.
7. Mustafa el-sonbaty, Mohamed makboul, Ahmed kamal, Tarek raief. Surgical Reconstruction for Partial Auricular Defects. *Egypt, J Plast. Reconstr. Surg.* 2015; 39(1):79-84.
8. Brent B. Pickrell, Christopher D. Hughes, Renata S. Maricevich. Partial Ear Defects. *Semin Plast Surg.* 2017; 31:134-140.
9. Peter Kim, Kwan Stephen Lee. Retroauricular cutaneous advancement flap. *Australian Family Physician.* 2012; 41(8):601-2.
10. Shaye D, Sykes M. Reconstruction of acquired auricular deformity. *Operative Techniques in Otolaryngology.* 2011; 22:47-52.
11. Ray E. Review of options for burned ear reconstruction. *J Craniofac. Surg.* 2010; 21(4):1165-9.
12. Monica Rebello Ottat. Partial reconstruction of the external ear after a trauma - simple and efficient techniques. *Braz J Otorhinolaryngol.* 2010; 76(1):7-13.
13. Luo X, Yang Q, Yang Wang X. "Classification and reconstruction of posttraumatic ear deformity," *Journal of Craniofacial Surgery.* 2012; 23(3):654-7.
14. Louis P, Aponte-Wesson R, Fernandes R, Clemow J. "Autogeneous and prosthetic reconstruction of the ear," *Oral and Maxillofacial Surgery Clinics of North America.* 2013; 25(2):271-86.
15. Schonauer F, Gunasaker V, Sergio M, Adriano S, Luigi C, Guido M. Versatility of Posterior Auricular Flap in Partial Ear Reconstruction. *Plastic and Reconstructive Surgery.* 2010, 126(4).