



Ambulant vacuum-assisted closure of skin-graft dressing in the lower limbs using a portable mini-VAC device

G. Sposato, G. Molea*, G. Di Caprio, M. Scioli, I. La Rusca* and P. Ziccardi

*'Salvatore Maugeri' Foundation, Institute of Care and Scientific Research Rehabilitation, Institute of Telesse Terme (Benevento), Telesse Terme (Benevento); and *Institute of Plastic and Reconstructive Surgery, University of Naples 'Federico II', Naples, Italy*

SUMMARY. A skin graft may fail to adhere to the recipient site because of fluid collecting between the graft and the area being treated. We have devised a simple procedure, consisting of a vacuum-sealed dressing, to fix skin grafts on the lower limbs. A fully portable, battery-operated aspirator continuously draws secretions through a vacuum-sealed dressing, preventing accumulation of fluid underneath the graft. Patients are not confined to bed, thus reducing nursing time. The procedure was applied successfully in seven out of nine patients treated for ulcers of the lower limbs. © 2001 The British Association of Plastic Surgeons

Keywords: vacuum-assisted wound closure, lower limb, skin graft.

Although the conditions required for adherence of a skin graft and the techniques for fixing and immobilising the graft on the recipient site are well established, skin grafts can fail to take. The two most frequent causes of skin-graft failure are non-adherence and accumulation of secretions between the graft and the lesion.

Various fixing techniques have been described,^{1–4} but some skin grafts still fail. In addition, the limb being treated must be immobilised and hence the patient is often confined to bed to maximise the probability of the graft taking, the time of immobilisation being about 5 days.

We tried to solve the problem of accumulation of secretions between the graft and the lesion and of the need to immobilise the patient. In the technique described here, uniform negative pressure is applied to the treated area ensuring perfect adhesion of the graft and an aspirator draws off secretions.^{5,6} The battery-operated machine is fully portable, so the patient is free to move and is not confined to bed.

Materials and methods

Equipment

We applied to skin grafting a technique that is widely used to treat ulcers of the lower limbs. The technique is based around a portable machine that creates a vacuum in the area beneath a watertight dressing; the reduced pressure promotes formation of granulation tissue. The apparatus (Mini vacuum-assisted-closure, Mini-VAC)^{7,8} consists of a battery-operated low-voltage aspirator, a one-way container for fluids, a polyethylene tube attached to a polyvinyl sponge pad, a cover plate linked to the tube and an adhesive polyethylene film that covers the plate and adheres to the skin ensuring that the system is watertight.

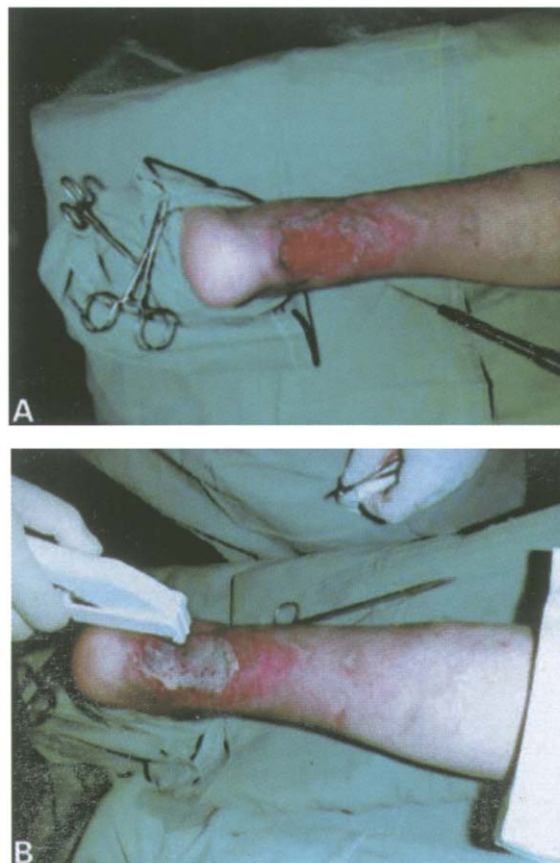


Figure 1—(A) Ulcerated limb; (B) fixing the graft.

Negative pressure (5–15 kPa) is applied continuously or intermittently. Application of negative pressure causes the sponge to contract. This ensures that pressure is

evenly distributed over the whole wound surface, irrespective of any irregularities of the recipient bed. Fluid beneath the graft drains off through the tube attached to the sponge.

Procedure

The skin-grafting procedure is performed under regional anaesthesia.⁹ The skin taken for the graft is fenestrated with a number 11 blade and fixed to the edges of the lesion with either stitches or metal clips (Fig. 1). The graft is covered with vaseline-soaked gauze. The spongy polyvinyl pad, cut to the appropriate shape and size, is placed over the gauze (Fig. 2). The Mini-VAC plate is then placed on the pad and covered with an impervious adhesive film (Fig. 3).

The machine can then be programmed. In our patients, we use a continuous negative pressure of 7.5 kPa for 5 days. During this time the dressing is not changed unless it is no longer watertight.

The machine, attached to a belt, is easily portable and does not impede the patient's daily activities (Fig. 4). After 5 days the dressing is removed. At this stage the graft has usually taken (Fig. 5). Within 14 days the graft is usually stable and perfectly adherent to the surrounding skin.

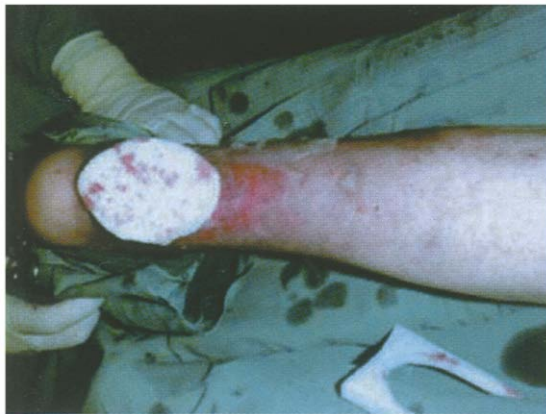

Figure 2—The spongy pad is applied to the graft.

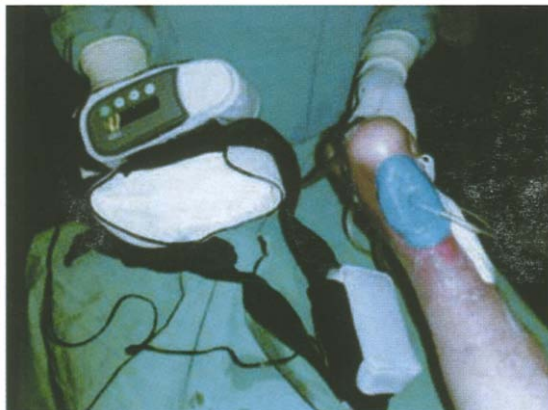


Figure 3—The Mini-VAC apparatus in place.



Figure 4—The patient is encouraged to walk immediately after recovery from anaesthesia.

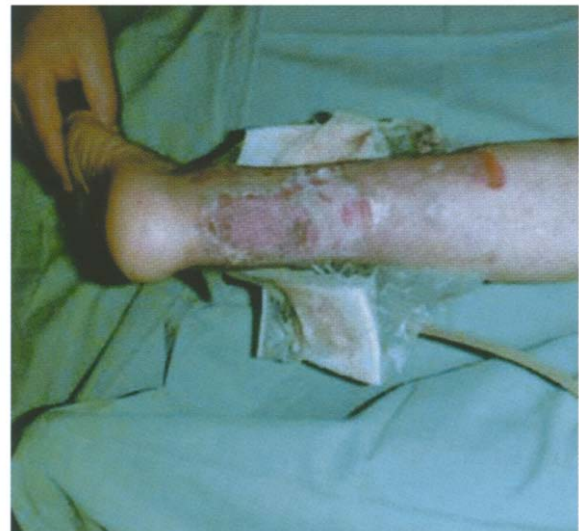

Figure 5—Day 5 after surgery. Note that the graft has 'taken'.

Results

We have used this technique in nine cases in seven patients (Table 1). The graft was completely successful in seven cases. In one case a 95% take was obtained and in one the dressing was removed on the second day because it was no longer watertight.

Table 1 Outcome of the procedure in the nine cases treated

Patient	Sex	Age (years)	Location of lesion and pathology	Outcome (% graft take)
1	M	68	Diabetic plantar ulcer on left leg	95
2	M	48	Post-traumatic ulcer on stump of right leg	100
3 (case 1)	M	62	Ischaemic hypertensive ulcer in the Achillear region of left leg	100
3 (case 2)	M	62	Ischaemic hypertensive ulcer in the exterior overmalleolar region	100
4 (case 1)	M	70	Post-traumatic ulcer in side region of right leg	100
4 (case 2)	M	70	Post-traumatic ulcer in the inner submalleolar region of the right leg	80 ^a
5	F	64	Post-phlebitic ulcer on left leg	100
6	F	58	Post-phlebitic ulcer on left leg	100
7	F	27	Post-traumatic ulcer on right leg	100

^aThe dressing was changed on the 2nd day to restore watertightness.

Discussion

We routinely used the Mini-VAC machine preoperatively in order to remove the secretions typical of ulcers. Unlike other procedures in which a 'bedside' VAC machine is used,^{10,11} during our procedure patients are allowed to walk and carry out their normal daily activities. This prompted us to use this simple technique to immobilise skin grafts on the lower limbs.

The use of a vacuum-sealed dressing ensures perfect adhesion to the recipient area. Because of the negative pressure, adhesion is not affected by movement of the limb. Moreover, secretions are aspirated through the sponge polyvinyl pad, thereby preventing their accumulation underneath the graft. Because patients are not confined to bed, nursing assistance is greatly reduced.

Although the cost of the machine (3900 €) is significant, it is fully off-set by the reduction in nursing time and the comfort of the patient during the 5 days after surgery.

Acknowledgements

We are indebted to Jean Ann Gilder for revising the text.

References

- Balakrishnan C. Simple method of applying pressure to skin grafts of neck with foam dressing and staples. *J Burn Care Rehabil* 1994; 15: 432-3.
- Francis A. Nursing management of skin graft sites. *Nurs Stand* 1998; 12: 41-4.
- Koldas T. A simple method for the classic tie-over dressing. *Ann Plast Surg* 1992; 28: 386-7.
- Wolf Y, Kalish E, Badani E, Friedman N, Hauben DJ. Rubber foam and staples: do they secure skin grafts? A model analysis and

proposal of pressure enhancement techniques. *Ann Plast Surg* 1998; 40: 149-55.

- Deva AK, Siu C, Nettle WJ. Vacuum-assisted closure of a sacral pressure sore. *J Wound Care* 1997; 6: 311-12.
- Morykwas MJ, Argenta LC. Nonsurgical modalities to enhance healing and care of soft tissue wounds. *J South Orthop Assoc* 1997; 6: 279-88.
- Argenta LC, Morykwas MJ. Vacuum-assisted closure: a new method for wound control and treatment: clinical experience. *Ann Plast Surg* 1997; 38: 563-76.
- Collier M. Know how: vacuum-assisted closure (VAC). *Nurs Times* 1997; 93: 32-3.
- Ratner D. Skin grafting. From here to there. *Dermatol Clin* 1998; 16: 75-90.
- Blackburn JH II, Boemi L, Hall WW, et al. Negative-pressure dressings as a bolster for skin grafts. *Ann Plast Surg* 1998; 40: 453-7.
- Schneider AM, Morykwas MJ, Argenta LC. A new and reliable method of securing skin grafts to the difficult recipient bed. *Plast Reconstr Surg* 1998; 102: 1195-8.

The Authors

Giovangustavo Sposato MD, Consultant Plastic Surgeon
Giovanni Di Caprio MD, Specialist in Plastic Surgery
Michelina Sciole MD, Specialist in Plastic Surgery
Pasquale Ziccardi MD, Specialist in Plastic Surgery

'Salvatore Maugeri' Foundation, Institute of Care and Scientific Research Rehabilitation, Institute of Telese Terme (Benevento), Via Bagni Vecchi, Telese Terme (Benevento), Italy.

Guido Molea MD, Professor of Plastic Surgery
Ivan La Rusca MD, Trainee in Plastic Surgery

Institute of Plastic and Reconstructive Surgery, University of Naples 'Federico II', Via S. Pansini 5, Naples, Italy.

Correspondence to Professor Guido Molea.

Paper received 3 March 2000.

Accepted 6 November 2000, after revision.

Published online 23 February 2001.