

Percutaneous transhepatic biliojejunal rendezvous technique for biliary obstruction with Billroth II anatomy

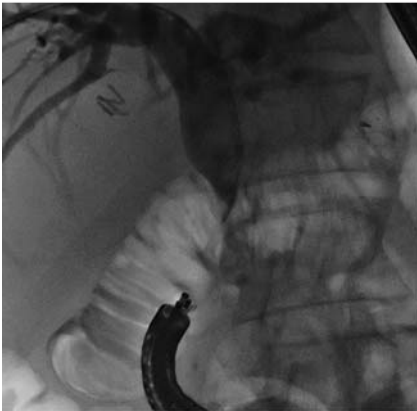


Fig. 1 Abdominal radiograph showing occlusion of the common bile duct with the endoscope in position at the level of the afferent limb.

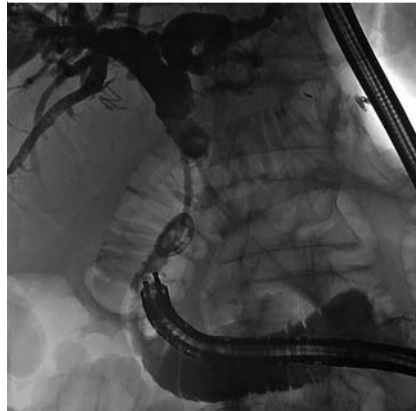


Fig. 4 Abdominal radiograph after the internal-external biliary drain had been positioned.

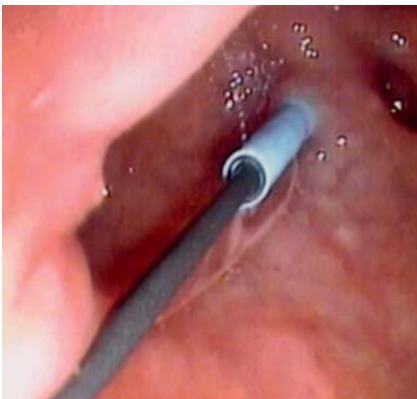


Fig. 2 Endoscopic view of the guidewire and the catheter entering the afferent limb after having been passed through the retroperitoneal space.

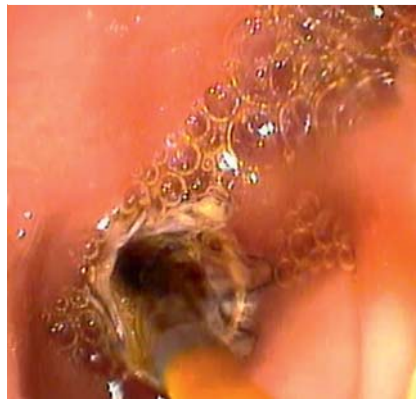

Fig. 5 Endoscopic view after a covered stent had been positioned showing normal passage of bile through the stent.

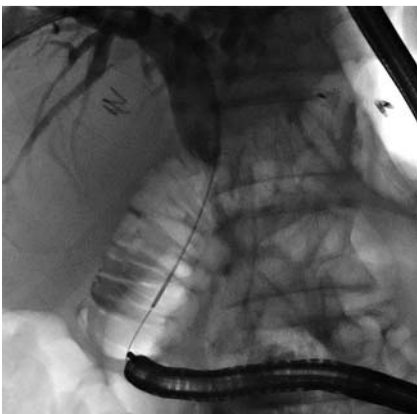


Fig. 3 Abdominal radiograph showing the guidewire being grabbed using the endoscope.

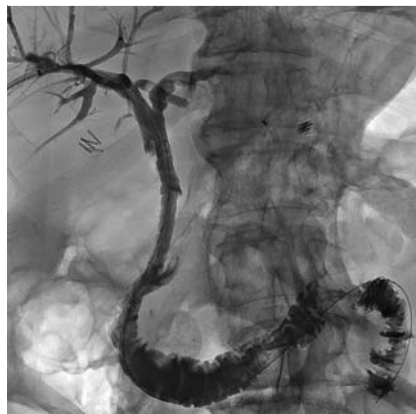

Fig. 6 Final abdominal radiograph showing normal passage of contrast medium from the biliary tree into the afferent limb with no evidence of leakage.

A 92-year-old man underwent a Billroth II procedure with isoperistaltic anastomosis for a distal gastric cancer and cholecystectomy for gallstones. On the second postoperative day, the patient began to develop signs of jaundice. A computed tomography (CT) scan showed iatrogenic common bile duct occlusion. The patient underwent an urgent percutaneous transhepatic cholangiogram (PTC) and had an 8.5-Fr external biliary drain (Cook, Bloomington, Indiana, USA) positioned.

After multidisciplinary consultation, it was decided that the patient was a candidate for a combined radiologic and endoscopic (rendezvous) procedure. With the patient under general anesthesia, an endoscopic retrograde cholangiopancreatography (ERCP) of the afferent limb showed that it was not possible to cannulate the papilla. Therefore, after overdilation of the distal part of the afferent limb, the back part of a 260-cm, 0.035-inch guidewire (Terumo, Tokyo, Japan) was passed through the retroperitoneal space from the distal part of the occluded common bile duct into the afferent limb (▶ Fig. 1 and ▶ Fig. 2). The endoscope was then used to grab the guidewire and an 8.5-Fr internal-external biliary drain was positioned (▶ Fig. 3 and ▶ Fig. 4).

After an ultrasound 1 month after biliary drainage had confirmed fibrosis of the retroperitoneal space at the hepatic hilum, an 8 × 60-mm biliary covered stent (Viabil; Gore, Flagstaff, Arizona, USA) was positioned using the rendezvous technique (▶ Fig. 5). A final check demonstrated good expansion of the biliary covered stent and normal passage of contrast medium from the biliary tract into the afferent limb with no evidence of leakage (▶ Fig. 6). The patient's condition has remained stable during the 4 months of follow-up to date.

Bile duct transection is an infrequent complication of biliary tract surgery, but it carries potentially devastating aftereffects [1]. Combined radiologic and endoscopic procedures are well known, but their use outside the biliary tree to recreate a connection between the bile duct and the bowel has rarely been described in the literature [2–4]. This case demonstrates the feasibility of the rendezvous technique in recreating a direct connection between the biliary tree and the bowel.

Endoscopy_UCTN_Code_TTT_1AR_2AK

Competing interests: None

Umberto G. Rossi¹, Giovanni Rubis Passoni², Paolo Rigamonti¹, Maurizio Cariati¹

¹ Department of Diagnostic Sciences – Division of Radiology and Interventional Radiology, San Carlo Borromeo Hospital, Milan, Italy

² Department of Gastroenterology – Endoscopy Unit, San Carlo Borromeo Hospital, Milan, Italy

References

- 1 *Thompson CM, Saad NE, Quazi RR et al.* Management of iatrogenic bile duct injuries: role of the interventional radiologist. *RadioGraphics* 2013; 33: 117–134
- 2 *Saleem A, Leroy AJ, Baron TH.* Modified rendezvous technique with successful reconnection of completely transected common bile duct using combined endoscopic and radiologic approach. *Endoscopy* 2010; 42 (Suppl. 02): E178–E179
- 3 *Aytekin C, Boyvat F, Yimaz U et al.* Use of the rendezvous technique in the treatment of biliary anastomotic disruption in a liver transplant recipient. *Liver Transpl* 2006; 12: 1423–1426
- 4 *Wai CT, Ngoi SS, Goh PY et al.* Modified rendezvous technique in management of biliary leak in right lobe live donor liver transplant recipients. *Surg Laparosc Endosc Percutan Tech* 2009; 19: e143–e145

Bibliography

DOI <http://dx.doi.org/10.1055/s-0034-1365817>
Endoscopy 2014; 46: E293–E294
© Georg Thieme Verlag KG
Stuttgart · New York
ISSN 0013-726X

Corresponding author

Umberto G. Rossi, MD

Department of Diagnostic Sciences –
Division of Radiology and Interventional Radiology
San Carlo Borromeo Hospital
Via Pio II, 3
20153 Milano
Italy
Fax: +39-02-40222465
urossi76@hotmail.com