

Use of an over-the-scope clip for endoscopic sealing of a gastric fistula after sleeve gastrectomy

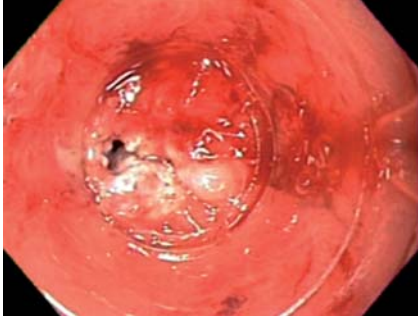


Fig. 1 Endoscopic fistula.

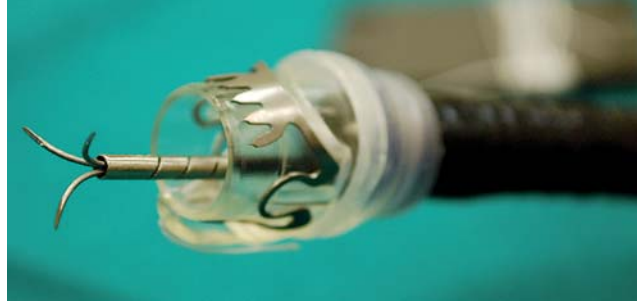

Fig. 3 The over-the-scope clipping system with the anchor catheter.

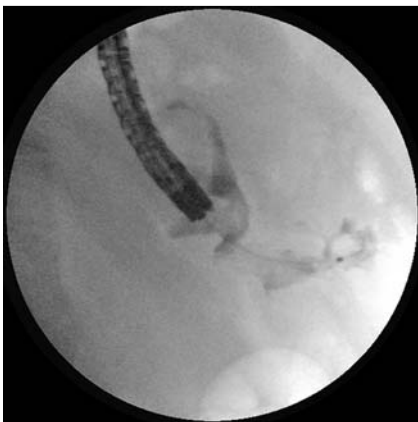

Fig. 2 X-ray examination showing the extravasation of contrast medium.

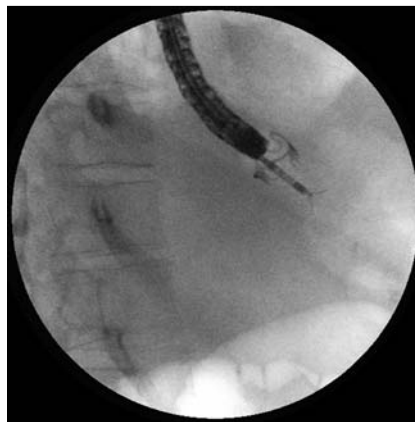


Fig. 4 The anchor catheter introduced through the fistula.

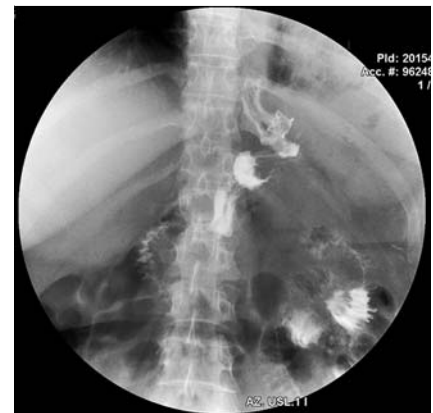

Fig. 5 Fluoroscopic control after treatment with the over-the-scope clipping system.

Perforation or development of a fistula in the gastrointestinal tract is a serious complication. A gastrocutaneous fistula after sleeve gastrectomy is difficult to treat, with a mortality rate of 85% following unsuccessful treatment [1]. These fistulas have been successfully managed with endoscopic fibrin sealing [2]. Preliminary experience with the over-the-scope clipping system (Ovesco, Tubingen, Germany) has shown the efficacy of this intervention in the management of severe bleeding and perforations of the gastrointestinal tract [3–5].

This is the first report of the use of an over-the-scope clipping for the management of a gastric fistula. A 43-year-old woman underwent sleeve gastrectomy for morbid obesity. After 1 week, a fistula developed at the proximal end of the suture, 2 cm distal to the esophagogastric junction. A nasogastric drain and an ultrasound-guided external drain were insert-

ed. Endoscopy showed a 7-mm orifice (Fig. 1). Fig. 2 shows the extravasation of contrast medium, confirming the presence of a fistula. Two attempts to seal the fistula with hemoclips failed.

Placement of a large, colorectal expandable covered stent (Taewoong, Korea) was also attempted. The patient could not eat and complained of severe epigastric pain. The stent was removed 3 weeks later. Surgery was carried out, but the fistula reappeared 1 week later and a gastrocutaneous fistula was diagnosed.

The over-the-scope clipping system was used to overcome the limitations presented by the available hemoclips. The over-the-scope clip is delivered by means of an applicator cap placed on the tip of the endoscope. A catheter with a retractable anchor was introduced through the fistula and the grasped tissue firmly pulled inside the cap (Fig. 3 and 4).

The clip was then released and the fistula successfully closed. The patient was allowed to eat her usual diet 24 hours later after post-treatment evaluation. She was then discharged. The endoscopic and radiologic controls performed after 1 and 2 weeks confirmed sealing of the fistula (Fig. 5).

Endoscopy_UCTN_Code_TTT_1A0_2AI

M. Conio¹, S. Bianchi¹, A. Repici², R. Bastardini¹, G. M. Marinari³

¹ Department of Gastroenterology, General Hospital, Sanremo, Italy

² Digestive Endoscopy Unit, IRCCS Istituto Clinico Humanitas, Milan, Italy

³ Department of Surgery, Unit of Obesity Surgery, AOU S. Martino Hospital, Genova, Italy

References

- 1 *Rolandelli R, Roslyn JJ.* Surgical management and treatment of sepsis associated with gastrointestinal fistulas. *Surg Clin North Am* 1996; 76: 1111–1122
- 2 *Papavramidis TS, Kotzampassi K, Kotidis E et al.* Endoscopic fibrin sealing of gastrocutaneous fistulas after sleeve gastrectomy and biliopancreatic diversion with duodenal switch. *J Gastroenterol Hepatol* 2008; 23: 1802–1805
- 3 *Kratt T, Küper M, Traub F et al.* Feasibility study for secure closure of natural orifice

transluminal endoscopic surgery gastrotomies by using over-the-scope clips. *Gastrointest Endosc* 2008; 68: 993–996

- 4 *Kirschniak A, Kratt T, Stüker D et al.* A new endoscopic over-the-scope clip system for treatment of lesions and bleeding in the GI tract: first clinical experiences. *Gastrointest Endosc* 2007; 66: 162–167
- 5 *Kirschniak A, Traub F, Kueper MA et al.* Endoscopic treatment of gastric perforation caused by acute necrotizing pancreatitis using over-the-scope clips: a case report. *Endoscopy* 2007; 39: 1100–1102

Bibliography

DOI 10.1055/s-0029-1215199
Endoscopy 2010; 42: E71–E72
© Georg Thieme Verlag KG Stuttgart · New York ·
ISSN 0013-726X

Corresponding author

M. Conio, MD
Department of Gastroenterology
C.so Garibaldi 187, 3
Sanremo
Italy
Fax: +39-184-536875
mxconio@tin.it