

Case report

Off pump treatment of aortic arch rupture: extraanatomic hybrid reconstruction

D. Mangino^{a,*}, A. Terrini^a, G. Grassi^b, C. Zussa^a

^aCardiac Surgery Unit, Umberto I Hospital, Via Circonvallazione 50, 30174 Mestre, Venice, Italy

^bCardiology Unit, Umberto I Hospital, Mestre, Venice, Italy

Received 29 June 2004; received in revised form 7 October 2004; accepted 14 October 2004

Abstract

We present a possible alternative technique to treat the rupture of aortic arch aneurysms on beating heart without necessity of cardiopulmonary bypass (CPB), hypothermic circulatory arrest and cerebral protection, using a bifurcated vascular prosthesis to revascularize the subclavian and carotid arteries and an endovascular prosthesis to repair the aortic arch. We report the case of a 78-year-old woman successfully treated with this technique. Since in our institution endovascular prostheses are placed by the interventional cardiologists, the operation was done in cooperation between cardiac surgeons and interventional cardiologists.

© 2004 Elsevier B.V. All rights reserved.

Keywords: Ascending aorta aneurysm; Aortic surgery; Beating heart; Endovascular prosthesis

1. Background

Emergency aortic arch surgery is a major challenge due to the severity of the lesions, hypothermia, circulatory arrest and long cardiopulmonary bypass (CPB) time, conditioning postoperative bleeding and producing high morbidity and mortality [1-3].

The standard treatment of aortic arch lesions implies the use of cardiopulmonary bypass, myocardial protection, hypothermic circulatory arrest and cerebral protection.

We outline a possible alternative to treat aortic arch rupture without use of CPB.

2. Technique of operation

A 78-year-old woman admitted after syncope and thoracic pain underwent CT examination, that revealed a fissured 7 cm diameter large chronic aortic arch aneurysm and massive left haemothorax. The diameter of the ascending aorta was also evaluated and considered normal (23 mm), where descending aorta was 30 mm diameter.

The aortography revealed severe stenosis of right subclavian, both carotid, renal and femoral arteries. Due to this preoperative condition, arterial cannulation for a classical on pump hypothermic circulatory arrest procedure was considered unfeasible (Fig. 1).

Operation was performed through a standard complete median sternotomy. Innominate vein was transected.

The aortic arch was surrounded by strong adhesions.

Only innominate and left carotid arteries were skeletonized.

A bifurcated 16/8/8 mm vascular prosthesis (Intergard Knitted Collagen Coated Polyester Vascular Prosthesis, Intervascular, La Ciutat, France) was anastomized to the ascending aorta on beating heart using a side clamp. In the same fashion a 16 mm vascular prosthesis (a remnant of the bifurcated one) was anastomosed to the ascending aorta in order to provide an access to introduce the endovascular prosthesis. Only one side clamp was placed to perform both anastomoses.

In order not to mobilize calcified supraaortic vessels and to facilitate anastomoses, both distal branches of the vascular prosthesis were terminolaterally anastomosed to the innominate and the left carotid arteries, respectively. A shunt was placed into the carotid arteries while the anastomoses were performed. An endarterectomy was done on the right subclavian artery. No attempt was made to revascularize the left subclavian artery (Fig. 2).

Two endovascular prostheses 26 and 34 mm respectively (Medtronic Talent, Medtronic, Minneapolis, USA) were placed distally to the bifurcated prosthesis along the aortic arch in order to prevent further bleeding and rupture. The greater one was placed first and along the isthmus, and the smaller was placed along the aortic arch. Bleeding from the vascular prosthesis used as a port to introduce the endovascular prostheses was controlled by a tourniquet placed around the port prosthesis.

* Corresponding author. Tel.: +39 041 2608332; fax: +39 041 2608340.
E-mail address: domenicomangino@libero.it (D. Mangino).

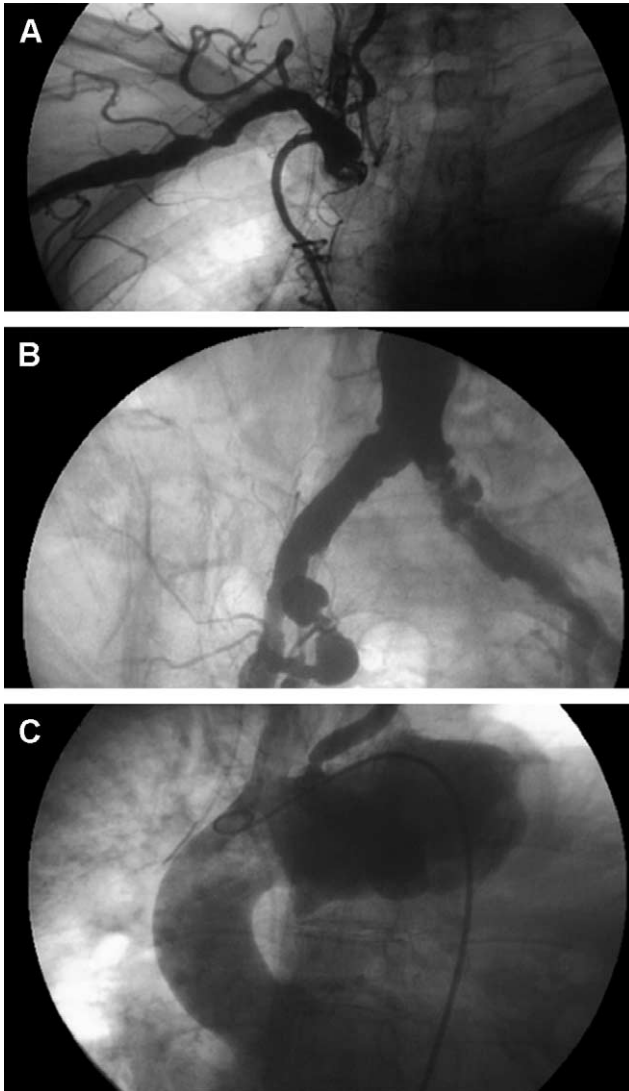


Fig. 1. Preoperative findings: (a) obstructed right subclavian artery; (b) stenotic femoral arteries; (c) fissurated chronic aortic arch aneurysm

Positioning of the endovascular prostheses was accomplished utilizing open-chest cineangiography during the whole procedure, that gave also intraoperative confirmation of the patency of the bifurcated graft, the correct position of the endovascular prostheses and the absence of endoleaks.

Duration of whole procedure was 4 h; no intraoperative complications were observed.

Postoperative bleeding was 200 ml.

When the patient regained consciousness, a mild weakness of her left arm was observed. Revascularization was not considered necessary.

3. Considerations

When arterial cannulation for CPB is difficult or not feasible, we suggest to perform an extraanatomic hybrid reconstruction of the aortic arch. This technique allows to manage one of the major challenging pathological conditions

in cardiovascular surgery, aortic arch aneurysm rupture, without the use of CPB, aortic cross clamping and hypothermic circulatory arrest and does not need any myocardial or cerebral protection technique. However, it minimizes

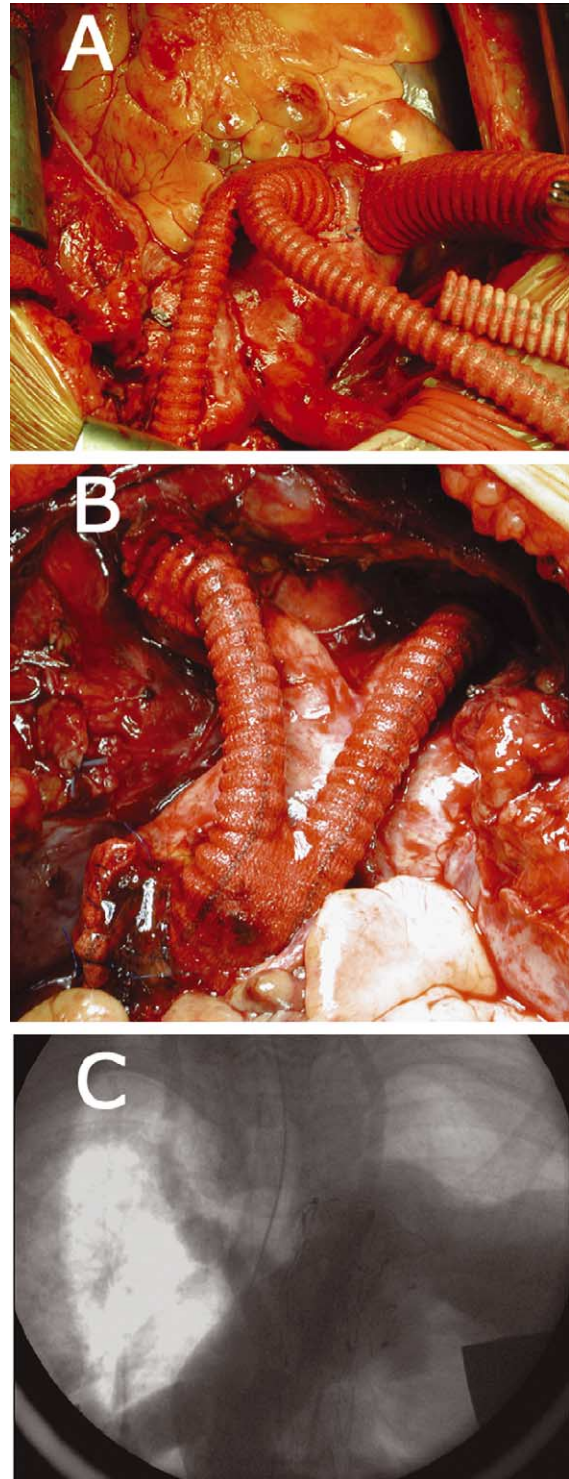


Fig. 2. Extraanatomic reconstruction of supraaortic vessels: (a) bifurcated vascular prosthesis and 'side port' for endovascular prosthesis on ascending aorta; (b) final aspect: revascularized supraaortic vessels and closed 'side port'; (c) angiographic control: position of the endovascular prostheses and patency of bifurcated graft.

operative risk and extends surgical indication to otherwise unsuitable patients.

Even if we performed this technique in a chronic aneurysm rupture, we believe that it could be successfully applied in acute aortic arch rupture or dissection, or in type A aortic dissection, associated with on-pump repair of ascending aorta, in order to simplify surgical technique. When needed, revascularization of left subclavian artery can be performed on demand.

References

- [1] Coutu M, Ugolini P, Paquet E, Cartier R. Alternative technique to classic aortic arch repair. *Can J Cardiol* 2004;20(3):349-51.
- [2] Bavaria JE, Brinster DR, Gorman RC, Woo YJ, Gleason T, Pochettino A. Advances in the treatment of acute type A dissection: an integrated approach. *Ann Thorac Surg* 2002;74(5):S1848-S52.
- [3] Kanagasabay RR, Matalanis G. A novel approach to reconstructing the distal aortic arch. *Eur J Cardiothorac Surg* 2002;21(3):544-5.