

Subclinical rhythmic electrographic discharges of adults and transient global amnesia: a causal or casual association?

Francesco Brigo, Luigi Giuseppe Bongiovanni, Antonio Fiaschi

Department of Neurological, Neuropsychological, Morphological and Movement Sciences, University of Verona, Italy

Received February 10, 2010; Accepted September 21, 2010

ABSTRACT – Subclinical rhythmic electrographic discharges of adults (SREDA) is an uncommon distinctive EEG rhythmic pattern with uncertain significance. We report a patient with transient global amnesia in whom an EEG recording, performed after the acute phase of the neurological event, showed SREDA. Based on this EEG finding, we discuss about a possible correlation between SREDA and transient global amnesia. The presence of SREDA in our patient with transient global amnesia seems to be incidental. When described in association with transient global amnesia, SREDA should be recognized in order to avoid misdiagnosis. Although SREDA has been fortuitously described in association with transient global amnesia, a patho-physiological correlation with mechanisms which produce it seems unlikely.

Key words: EEG, subclinical rhythmic electrographic discharges of adults, transient global amnesia

Subclinical rhythmic electrographic discharges of adults (SREDA) is an uncommon distinctive rhythmic pattern seen on EEG in subjects older than 50 years (Westmoreland and Klass, 1981). This pattern, which can resemble epileptic discharges, consists of sharp-contoured or sinusoidal theta waveforms in the theta range (usually 5-7 Hz), occurring in a widespread distribution, often with a maximal expression over the parieto-temporal regions. The pattern is usually bilateral, with onset and end that may or may not be abrupt, and does not usually evolve into a different

morphology or other frequencies. The average duration of the discharge is usually 40-80 seconds, but it may be less than 10 seconds or even more than five minutes.

SREDA is considered to be a pattern of uncertain significance. Naquet *et al.* (1961) suggested that cerebrovascular disease, ischemia or transient hypoxia might have a role in the genesis of SREDA.

In previous reports (Westmoreland and Klass, 1981; Begum *et al.*, 2006), SREDA was described in patients with transient global amnesia (TGA), a syndrome with ill-defined aetiology,

Correspondence:

F. Brigo
Department of Neurological,
Neuropsychological, Morphological and
Movement Sciences,
University of Verona,
Piazzale L.A. Scuro,
37134 Verona, Italy
<dr.francescobrigo@gmail.com>

doi: 10.1684/epd.2010.0335

characterized by the abrupt onset of severe anterograde amnesia, with repetitive questioning and neurological status being otherwise normal, resolving within 24 hours. We report a patient with TGA in whom an EEG recording, performed after the acute phase of TGA, showed SREDA. We were somewhat surprised to find this unusual EEG pattern in a patient with TGA and we therefore discuss about a possible correlation between SREDA and TGA.

Case report and description of EEG pattern

A 73-year-old woman with TGA was admitted to our hospital. Her medical history was unremarkable. Laboratory data was normal. CT head scan showed no abnormalities. Neurological examination showed no abnormal findings, apart from the characteristic anterograde amnesia, moderate retrograde amnesia and repetitive questioning. Within 24 hours the amnesia resolved, and at discharge the patient still had an amnesic lacuna of around three hours. Two EEGs were performed for this patient, four and six days after the onset of TGA, respectively. The first EEG, performed when the neurological examination was unremarkable except for the amnesic lacuna, showed a posterior dominant well-organized rhythm at 10-11 Hz. SREDA onset (*figure 1*) was abrupt, initially diffuse, but after a few seconds predominantly distributed bilaterally, over the parieto-posterior and temporo-occipital regions. The pattern, occurring during wakefulness, consisted of repetitive monophasic, sharp-contoured waveforms that repeated every 1-2 seconds

and gradually evolved into a sustained rhythmic sinusoidal theta pattern (5-6 Hz), replacing the ongoing background activity. Amplitude was maximal from onset and remained constant. SREDA was not suppressed by either eye opening (although in the first seconds after eye opening it was less evident) or verbal calls. During the discharge about the patient was fully alert, was able to follow verbal commands and speak correctly. The duration of the discharge was four minutes. The interruption of SREDA was abrupt, without post-ictal slowing or modifications in EEG background activity (*figure 2*). A second EEG performed two days later was completely normal, without SREDA.

Discussion

SREDA is an uncommon pattern which, although closely resembles EEG seizure discharges, does not correlate with a history of epileptic seizures or the subsequent development of seizures. It is therefore considered a benign EEG pattern of uncertain significance. SREDA has previously been described in patients affected by TGA (Westmoreland and Klass, 1981; Begum *et al.*, 2006).

A possible correlation between SREDA and TGA is indicated by the following arguments. TGA is thought to reflect a functional dysfunction of the hippocampus. The main involvement of discharges in SREDA is seen over parietal and posterior temporal derivations, which are thought to be the anatomical regions involved in TGA. Furthermore, although considered a rare EEG pattern with a prevalence of 1 per 2500 recordings (Westmoreland and Klass, 1981),

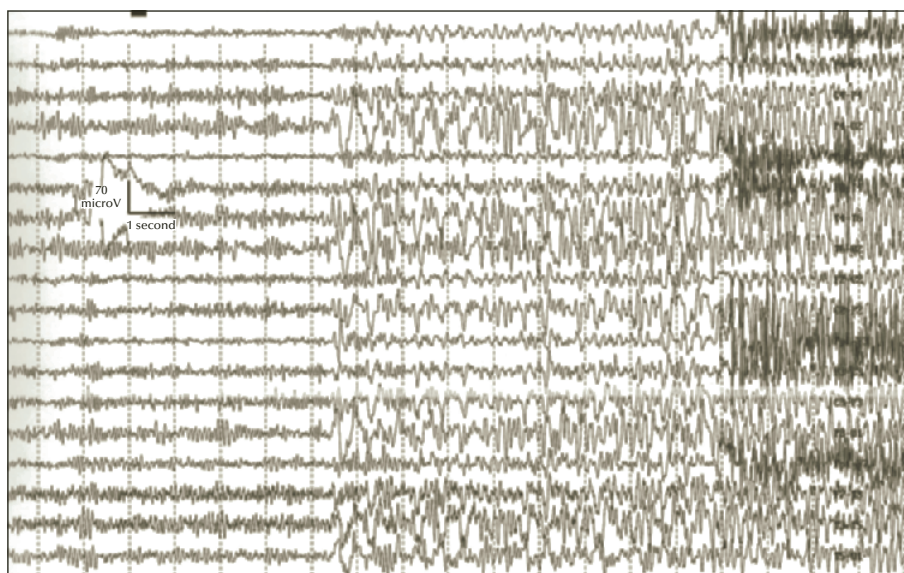


Figure 1. Abrupt onset of SREDA in the absence of any clinical manifestation. Sensitivity: 7 μ V/mm; TC: 0.1s; HF: 50.0 Hz; each vertical bar: 1 sec.

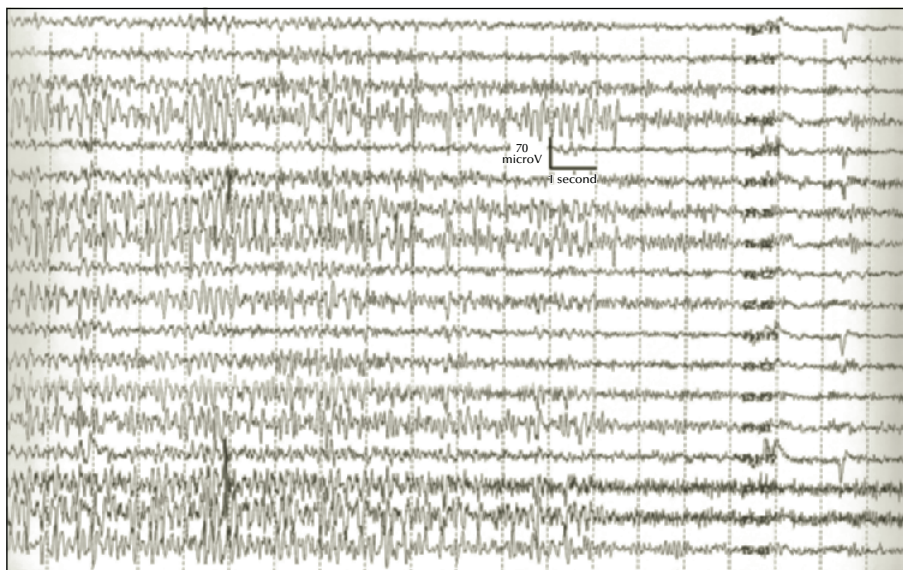


Figure 2. SREDA interruption without post-ictal slowing or modification of EEG background activity, in the absence of any clinical manifestation.

Sensitivity: $7\mu\text{V/mm}$; TC: 0.1s; HF: 50.0 Hz; each vertical bar: 1 sec.

Begum *et al.* (2006) reported the association of TGA and SREDA with a high frequency of 1 in 4 (25%) patients. From an epidemiological point of view, this association may therefore seem not to be incidental. Based on the results of their case study, Begum *et al.* (2006) raised the possibility that the presence of SREDA may suggest the pathomechanism of TGA, although no such mechanism was mentioned or proposed.

On the other hand, many aspects argue against the hypothesis of a possible correlation between SREDA and TGA. A first argument concerns the fact that, although EEG recording in patients affected by TGA may show epileptiform abnormalities in up to 37% (Butler *et al.*, 2007), SREDA is usually not reported. Moreover, whereas the high frequency of TGA in patients with SREDA (25%) reported by Begum *et al.* (2006) was based on a case series of only four patients, one of whom was affected by TGA, the case series of Westmoreland and Klass (1981), which was much larger (65 patients), showed a remarkable lower prevalence (3%) of SREDA in patients affected by TGA. As in the case we present, SREDA pattern seems not to be strictly temporally related with the amnesic disturbance, since SREDA was recorded some days after the onset of TGA and the resolution of anterograde amnesia. Furthermore, as in our case, SREDA normally has a duration ranging from a few seconds to a few minutes, whereas TGA has a longer duration (up to 24 hours). Finally, contrary to TGA, which normally does not recur, SREDA is typically present in subsequent EEG recordings, even when more than 12 years have elapsed between the recordings.

In the literature, there are no data regarding a temporal relationship between SREDA and TGA in terms of one preceding the other. There is also not enough data to hypothesize a possible correlation between the duration of TGA and the severity and frequency of SREDA, although the analysis of the reported cases (Butler *et al.*, 2007) seems to rule out a direct correlation. Finally, SREDA is an EEG pattern which is usually not associated with neuropsychological or behavioural disturbances (as its name suggests), so it seems unlikely that an otherwise clinically silent electroencephalographic discharge may be sufficient or necessary to induce TGA.

Weighing the pros and cons of a possible “causal” correlation between SREDA and TGA in our patient, it seems that arguments against this hypothesis are much more relevant than arguments in its favour, and we may therefore conclude that such an association is more likely to be incidental.

In conclusion, the presence of SREDA in our patient with TGA appears to be incidental. When described in association with TGA, this pattern of uncertain, although benign significance, should be recognized in order to avoid misdiagnosis (such as considering SREDA as an epileptic activity and TGA as an ictal symptom). Although SREDA has been fortuitously described in association with TGA, a patho-physiological correlation with mechanisms which produce TGA seems unlikely. □

Disclosure.

None of the authors has any conflict of interest or financial support to disclose.

References

Begum T, Ikeda A, Takahashi J, et al. Clinical outcome of patients with SREDA (subclinical rhythmic EEG discharge of adults). *Intern Med* 2006; 45: 141-4.

Butler CR, Graham KS, Hodges JR, Kapur N, Wardlaw JM, Zeman AZ. The syndrome of transient epileptic amnesia. *Ann Neurol* 2007; 61: 587-98.

Naquet R, Louard C, Rhodes J, Vigouroux M. A propos de certaines décharges paroxystiques du carrefour temporo-pariéto-occipital. Leur activation par l'hypoxie. *Rev Neurol* 1961; 105: 203-7.

Westmoreland BF, Klass DW. A distinctive rhythmic EEG discharge of adults. *Electroencephalogr Clin Neurophysiol* 1981; 51: 186-91.