

CASE REPORT

Food-dependent Cushing's syndrome: from molecular characterization to therapeutical results

N M Albiger, G Occhi, B Mariniello, M Iacobone¹, G Favia¹, A Fassina², D Faggian³, F Mantero and C Scaroni

Department of Medical and Surgical Sciences Endocrinology Unit, University of Padua, via Ospedale 105, 35128 Padua, Italy, Departments of ¹Endocrine Surgery, ²Pathology and ³Laboratory Medicine, University of Padua, 1-3: Giustiniani, 35128, Padua, Italy

(Correspondence should be addressed to N M Albiger; Email: nalbiger@yahoo.com)

Abstract

Objective: Cortisol secretion in ACTH-independent macronodular adrenal hyperplasia (AIMAH) may be regulated by the aberrant expression of several G-protein-coupled receptors. Bilateral adrenalectomy is the treatment of choice in most cases. We searched for aberrant receptor expression in a patient with AIMAH and evaluated the response to medical and surgical treatment.

Patient: A 35-year-old woman with amenorrhea, hirsutism, and hypertension presented ACTH-independent cortisol secretion with high androgen levels. Abdominal computed tomography showed bilateral adrenal macronodules (4.5 cm right and 1.0 cm left). Scintigraphy with I¹³¹-norcholesterol showed bilateral uptake, prevalent on the right side. Several *in vivo* stimulation tests were assessed before and after treatment and *in vitro* studies were performed after unilateral adrenalectomy.

Results: Plasma cortisol increased after a standard meal test (60%) and oral glucose loading (147%), and the response was blunted by pretreatment with 100 µg s.c. octreotide. The therapy with long-acting release octreotide (octreotide-LAR) showed an improvement in urinary free cortisol (UFC) levels. Unilateral adrenalectomy was performed and histopathology revealed macronodular AIMAH. Cortisol and androgens increased after perfusion of tumoral tissue with glucose-dependent insulinotropic polypeptide (GIP), and GIP and LH-receptor overexpression was found in both the adrenal nodules and the adjacent cortex. After surgery, UFC and androgen levels normalized followed by clinical improvement.

Conclusions: GIP and LH-receptor expression may coexist in AIMAH, influencing the functional and morphological phenotype. Aberrant hormone receptor expression enables specific pharmacological treatment, but long-term studies are needed to evaluate its real efficacy. Unilateral adrenalectomy may be a safe initial option, particularly for asymmetric bilateral adrenal enlargements.

European Journal of Endocrinology 157 771–778

Introduction

Approximately 10% of adrenocorticotrophin (ACTH)-independent Cushing's syndrome (CS) is secondary to bilateral nodular ACTH-independent macronodular adrenal hyperplasia (AIMAH) (1). A significant proportion of ACTH-independent adrenal tumors or hyperplasia may be under the control of aberrant hormone membrane receptors that may be expressed eutopically or ectopically (2). Hamet *et al.* (3) described the first case of cortisol production stimulated by food intake in a patient with a unilateral adrenal adenoma leading to CS. Several studies have since demonstrated that the abnormal cortisol response in these cases depends on the expression of glucose-dependent insulinotropic polypeptide receptor (GIP-R), which can be expressed in macronodular adrenal hyperplasia (4–9) and, less frequently, in unilateral adrenal adenoma (10–13). In the majority of reported cases, cortisol is the main steroid secreted in response to food intake, so most

of these patients have a clinical appearance of subclinical or overt CS, though some atypical cases with GIP-mediated cortisol and androgen secretion (12), or a cortisol response to both gonadotropin and GIP stimulation (14), have been described.

Since the luteinizing hormone (LH)/hCG receptor was shown to be expressed in the reticularis zone of adrenal glands (15), an aberrant expression of this receptor has also been suggested in some cases of CS (14, 16, 17) and in several cases of pure androgen-secreting adrenal adenoma (18–24) or hyperplasia (25) responding to LH or hCG stimulation *in vivo* and/or *in vitro*.

Identifying aberrant receptor expression can prompt new pharmacological alternatives to surgical treatment, particularly when bilateral disease would demand bilateral adrenalectomy and thus carry the consequence of primary hypoadrenalism.

Bilateral adrenalectomy is generally considered the treatment of choice in most patients with ACTH-independent macronodular adrenal hyperplasia,

though a few reports have suggested the feasibility of unilateral adrenalectomy in selected cases (26, 27).

We present a case of combined adrenal cortisol and androgen production by a food-dependent macronodular adrenal hyperplasia with GIP and LH/hCG-receptor coexpression, in whom medical treatment with a long-acting somatostatin analog improved urinary free cortisol (UFC) levels and unilateral adrenalectomy resulted in long-term remission of hypercortisolism and hyperandrogenism.

Clinical case

A 35-year-old woman was admitted to our institution for endocrinological evaluation due to amenorrhea. She had no family history of endocrine diseases. Menarche was 17 years old. She reported a full-term pregnancy at the age of 28 during which she had major weight gain in the early months. Arterial blood pressure and glucose levels were within the normal range. Postpartum she felt well but had oligomenorrhea (menstrual cycles of 45–60 days). She took oral contraceptives for 2 years. After stopping them, she had no spontaneous bleeding, so estrogen and progestin treatments were reinitiated. While on this treatment, her blood pressure levels began to increase (150/95 mmHg) and she experienced a progressive gain in weight of 4 kg, acne, and a mild increase in facial hair. Her daily oral medication included calcium channel blockers to control blood pressure levels. During physical examination, she was 1.70 m tall and weighed 60 kg (body mass index, BMI: 21), with a WHR of 0.87. She had a round, plethoric face, increased facial hair (Ferriman–Gallwey score 10) (28), and high blood pressure (140/95 with calcium blockers).

Initial biochemical evaluation revealed high UFC levels of 1100 µg/day (normal: 13.7–75.4 µg/day), morning plasma cortisol 5.7 µg/dl (normal: 5–25 µg/dl), plasma cortisol 6.8 µg/dl (normal: <3 µg/dl) at 2300 h, morning plasma ACTH 7.9 pg/ml (normal: 5–78 pg/ml), and plasma cortisol after 1 mg dexamethasone 13 µg/dl (normal: <1.8 µg/dl). Salivary cortisol levels were 0.6 µg/dl at 0800 h and 4.4 µg/dl at 2300 h (normal: 6–13 ng/ml and <2 ng/ml respectively). Serum

DHEA sulfate (DHEAS) levels were 6.6 µg/ml (normal: 0.7–3.9 µg/ml); testosterone 144 ng/dl (normal: 20–90 ng/dl), and androstenedione 2.3 ng/ml (normal: 0.2–3.0 ng/ml). Follicle-stimulating hormone (FSH) was 4.2 mIU/ml, LH 4.8 mIU/ml, and estradiol 12.6 pg/ml in amenorrhea. Sodium, potassium, cholesterol, triglycerides, and glucose levels were within the normal range.

Abdominal magnetic resonance imaging showed macronodular features on both adrenal glands (a non-homogeneous hypodense nodule of 45 mm on the right side and another of 10 mm on the left side). Adrenal scintigraphy with I¹³¹-norcholesterol showed a bilateral uptake, but prevalent on the right side.

A right unilateral adrenalectomy was performed: the gland measured 7.5 × 5.3 × 3.5 cm and weighed 48.8 g. Histology was typical of a macronodular adrenal hyperplasia (Fig. 1).

Material and methods

In vivo studies

Potentially illegitimate membrane hormone receptors were sought in the patient using a modified version of the clinical protocol previously published by Lacroix *et al.* (29).

The cortisol response to several stimulation tests was assessed before surgery. All tests were performed after obtaining the patient's written consent and in accordance with the Helsinki declaration. Before performing the test, the patient had been in a supine position for at least 1 h and had fasted overnight. An i.v. catheter was inserted and permeability maintained with a slow flow of saline solution throughout the tests. Serial ACTH and cortisol measurements were taken at 30-minute intervals for 2–3 h during the tests, which were performed in a sequence lasting several days. LH, FSH, prolactin, thyrotrophin, or GIP were measured at appropriate times.

The tests included the i.v. administration of 100 µg gonadotrophin-releasing hormone (Gn-RH) (Relefact, Gonadorelin, Aventis, Germany) and 200 µg i.v. TRH (thyrotrophin-releasing hormone TRH UCB, S.A. UCB N.V., Bruxelles), 500 µg i.v. terlipressin (Glipressina,

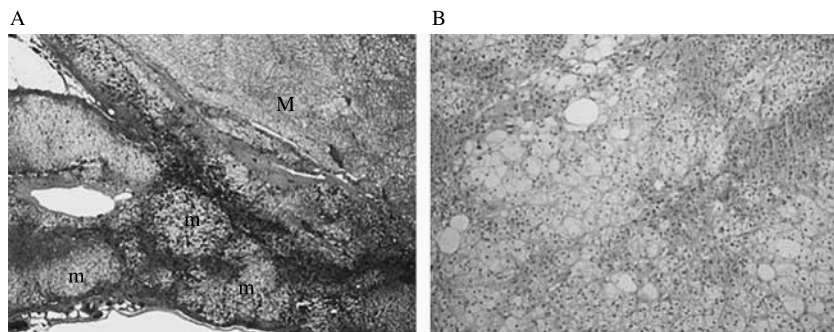


Figure 1 The adrenal cortex was thickened with well-designed nodules of variable dimension from 100 µm (m) to visible nodules (M). (A) Microscopically, the adrenal structure was distorted by nodules circumscribed by thin connective bands. (B) The nodules were composed mainly of pale, vacuolated 'lipid-rich' cells, intermingled with compact small cells. Frequent foci of lymphocytic adrenitis were also present. Atypical nuclei, mitotic figures, and necrosis were absent.

Ferring, Italy), 1 mg i.m. glucagon, 10 µg i.v. desmopressin (Minirin/DDAVP, Ferring S.p.A., Milano, Italy), 10 mg metoclopramide orally (Plasil, Gruppo Lepetit SpA, Italy), and 100 µg i.v. ovine CRH (CRF, Clinalfa, Merck Biosciences AG). The postural test was also performed, with 2 h in the supine position followed by 2 h of ambulation. A standard mixed meal challenge was performed, and a 75 g oral glucose tolerance test (OGTT) to confirm the findings. Octreotide (Sandostatin, Novartis, Italy) 100 µg s.c. was subsequently administered 60 min before a second standard mixed meal test to assess the effect of octreotide on GIP secretion and cortisol response.

After surgery, an OGTT was repeated and in addition an hCG test (Gonasi HP AMSA Srl, Italy; 5000 UI i.m. with samples obtained every 30 min for 3 h) was performed.

A test result was arbitrarily considered as a negative response when the increase in plasma cortisol levels was <25% of the baseline after the stimulus, as a partial response with an increase between 25 and 49%, and as a positive response with an increase \geq 50%. If a partial or positive response was found, the test was repeated to confirm the data.

In vitro studies

Tissue collection Adrenocortical tissue specimens were obtained immediately after surgery and stored in RNAlater (Ambion, USA) at -20°C until nucleic acid extraction. During surgery, a fragment of the patient's tumor was immersed in DMEM (Life Technologies, Grand Island, NY, USA) and taken rapidly to the laboratory for perfusion studies. One normal adrenocortical sample was obtained after surgery for renal transplantation, normal adult pancreas was obtained after surgery of a pancreatic tumor, and tumoral tissue from two patients with non-GIP-dependent CS and bilateral macronodular adrenocortical hyperplasia were also evaluated.

Perfusion experiments The tumor tissue was diced into small pieces ($1-2\text{ mm}^3$), rinsed with fresh DMEM, and transferred to perfusion chambers supplied with the same medium. The temperature in the chambers was maintained at 37°C and pH at 7.4. Before beginning the test, the tumor pieces were allowed to stabilize for 2 h at a constant flow rate ($300\text{ }\mu\text{l}/\text{min}$), then the substances were dissolved in DMEM and infused at the same flow rate.

Effluent fractions were collected at 5 min intervals and kept at -20°C until assay. Gastric inhibitory polypeptide was purchased from Sigma-Aldrich.

RNA extraction and RT-PCR The tissues were homogenized and RNA was isolated with 1 ml Trizol (Invitrogen) according to the manufacturer's protocol, using a Polytron homogenizer (Ultra-Turrax T8, Ika Labortechnik, Staufen, Germany). Briefly, the RNA was precipitated

with 0.5 ml isopropyl alcohol in the aqueous phase. The RNA pellet was washed once in 70% ethanol, dried, and resuspended in 50 µl RNase-free water and kept at -80°C until use. RNA yield and integrity were determined with a Bio Photometer (Eppendorf, Italy).

A 20 µl RT mixture containing 0.5 µg total RNA, 0.5 mM dNTPs, 4.5 ng/µl random hexamers, 5 mM dithiothreitol, 20 U RNase OUT, and 100 U Super Script III (Invitrogen) was incubated at 50°C for 1 h followed by 15 min at 70°C .

RT-PCR was performed in 12.5 µl volumes containing 0.4 units Taq polymerase (Amplitaq Gold, Applied Biosystems, Monza, Italy), 25 ng cDNA, 5 pmol of each oligonucleotide primer (R-GIP-6-7F 5'-GAGTTTGTTCAGGCGGCTAC-3', R-GIP-8R 5'-GCAGGTAGTAGCGGAAGTGG-3'), 2.5 mM MgCl_2 , and 0.2 mM dNTPs. Amplification was carried out on a 2700 GeneAmp PCR system (Applied Biosystems) under the following conditions: 94°C for 10 min followed by 35 cycles of 94°C for 30 s, 57°C for 30 s, and 72°C for 30 s. Aliquots of the amplified products were separated by 1.5% agarose gel electrophoresis and stained with ethidium bromide.

PCR product identity was confirmed by direct DNA sequencing analysis using the BigDye dideoxy terminator (Applied Biosystems Monza, Italy) on an ABI 3100 DNA sequencer (Applied Biosystems). Chromas 1.5 software (Technelysium, Helensvale, Australia), and the LASERGENE (DNA Star Inc., Madison, WI, USA) package of computer programs (DNASTAR) were used to edit and assemble sequences.

Real-time PCR Primers for amplification of the target sequences were based on published sequences for human LH/hCG-R and human GAPDH. The primer set used for LH/hCG-R consisted of forward: 5'-TCTGGA-GAAGATGCACAATGGA-3' and reverse: 5'-GCCTGC-AATTTGGTGGAAGA-3', and for GAPDH forward is 5'-CTCTCTGCTCCTCTGTTCGAC-3' and reverse is 5'-TGAGCGATGTGGCTCGGCT-3'.

Real-time PCR was performed in a total volume of 30 µl per reaction using the reaction parameters recommended by the manufacturer, using a power SYBR Green PCR Master Mix ($2\times$; Applied Biosystems), 50 nM of each primer, and 20 ng cDNA. All reactions were performed for LH-R and the housekeeping gene (GAPDH) at the same time. Data were obtained as C_t values according to the guidelines (the cycle number at which logarithmic PCR plots cross a calculated threshold) and used to determine ΔC_t values ($\Delta C_t = C_t$ of the target gene minus C_t of the housekeeping gene). The equation $2^{-\Delta\Delta C_t}$ was used to calculate the fold changes in gene expression between the patient and controls. Measurements were taken at least thrice for each sample.

Immunohistochemistry (IHC) IHC was performed with an automatic immunostaining device (Vision BioSystems 'Define' Polymer Detection System, Vision

BioSystems, Newcastle, UK), using a Bond-maX immunostainer (Vision Biosystems), on 5 μm thick sections from formalin-fixed paraffin-embedded tissues. Sections were transferred to adhesive slides and dried at 62 $^{\circ}\text{C}$ for 30 min. Anti-LH/choriogonadotropin receptor antibody (L 6792, Sigma–Aldrich Inc.) was diluted at 1:200. Bond primary antibody diluent was used. Sections were pretreated with Bond enzyme 1 for 10 min and stained with primary antibodies for 30 min, post-primary antibodies for 20 min, polymer for 30 min, and diaminobenzidine Define for 10 min, then counterstained with hematoxylin. The sections were dehydrated in alcohol, cleared in xylene, and mounted with DPX. As a negative control, the primary antibody incubation step was omitted, and placentas were employed as positive controls.

Hormonal assays

Plasma and urinary cortisol were measured by RIA (DIA-Sorin Diagnostics, Saluggia, Italy) with intra- and inter-assay coefficient of variation (CV) values of 5.4 and 9.6% respectively, and plasma ACTH levels by IRMA (Nichols Institute Diagnostics, San Juan Capistrano, CA, USA) with intra- and inter-assay CV values of 4.3 and 8.7% respectively. Serum DHEA-S concentrations were measured by RIA (DPC Diagnostic Products Corporation, Los Angeles, CA, USA) with intra- and inter-assay CV values of 8.1 and 5.3% respectively. Serum and perfused samples for 17-OH progesterone were determined by an enzyme immunoassay (DRG International Inc., DRG, Marburg, Germany) with intra- and inter-assay CV values of 5.5 and 6.8% respectively, and testosterone levels were determined by a chemiluminescence immunoassay (Roche Elecsys). Cortisol levels on perfused samples were determined in all fractions by RIA (Radim, Pomezia, Italy) with intra- and inter-assay CV values of 4.2 and 8.5% respectively.

Results

In vivo studies

A positive cortisol response (60% above the baseline) was prompted by the standard mixed meal, and this response was inhibited by the administration of 100 μg s.c. octreotide 60 min before the meal (Fig. 2a and b). Plasma cortisol response was confirmed after an OGTT test (147% above the baseline; Fig. 2c). The patient's treatment began with 20 mg octreotide-LAR, and subsequently increased to 30 mg, every 28 days for 5 months. A significant reduction in UFC levels was seen with treatment, but cortisol levels remained slightly above normal (Fig. 3). There was a modest improvement in clinical signs of CS during treatment

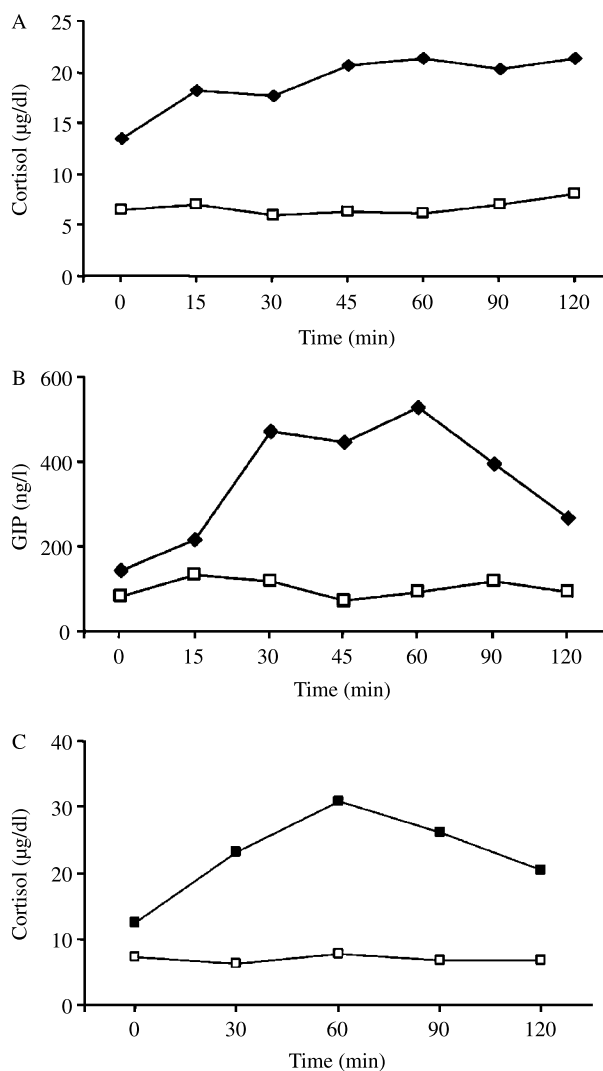


Figure 2 *In vivo* studies. Variations in (A) cortisol and (B) GIP levels after a standard meal without (—■—) or with (—□—) octreotide treatment (100 μg s.c.) 1 h beforehand. (c) Variations in cortisol levels after an OGTT without (—■—) or during (—□—) a long-acting somatostatin analog treatment.

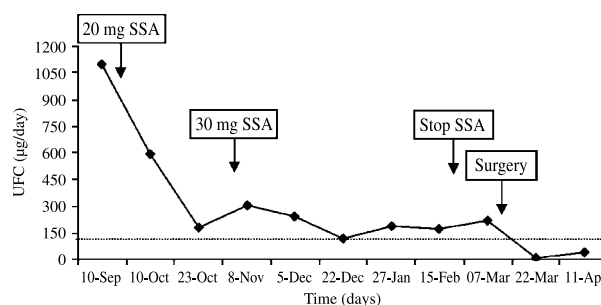


Figure 3 UFC levels during 5 months of therapy with a long-acting somatostatin analog (SSA). Values are expressed in $\mu\text{g}/24$ h (normal: 37–75 $\mu\text{g}/24$ h).

with octreotide-LAR, and OGTT was repeated with no cortisol response to the stimulus (Fig. 2c).

There was no cortisol response to desmopressin, terlipressin, TRH, and the postural test before treatment. Only a partial response of ACTH (29% above the baseline) to CRH stimulation was observed. A negative cortisol response was also observed during Gn-RH stimulation test, but the increase in LH levels (baseline: 4.8 mIU/ml, peak: 9.2 mIU/ml) was only modest. No androgen measurements were taken during these tests.

In vitro studies

Perfusion study The kinetics of the responses of perfused tissue to a pulse of GIP (10^{-7} M, 20 min) are shown in Fig. 4A. GIP administration induced a brisk but transient increase in cortisol secretion that reached a maximum of $262.0 \pm 3.0\%$. Moreover, GIP stimulation also induced an increase in 17-hydroxyprogesterone and testosterone levels of 127.0 and 86.0% respectively.

mRNA receptor expression RT-PCR analysis for GIP-R mRNA expression showed a band of 320 bp in the normal adult pancreas, and in the adrenal

macronodules and adjacent adrenal cortex in this patient, but not in the adrenal cortex of a normal subject or in the macronodular adrenal hyperplasia of two patients with non-GIP-dependent CS (Fig. 4B).

In our patient, mRNA expression of the LH/hCG-R gene, evaluated by real-time PCR, was about 94 times higher ($\Delta C_t = 8.44$) in tumoral tissue and 26 times higher ($\Delta C_t = 10.54$) in peritumoral tissue (Table 1, GIP+) than in control tissues of normal adrenal cortex ($\Delta C_t = 15.00$). The same mRNA analysis for LH/hCG-R was performed in two other patients with macronodular adrenal hyperplasia but non-GIP-dependent CS (Table 1, GIP-). Patient 2 had no LH/hCG-R mRNA expression in either tumoral or peritumoral tissue, whereas patient 3 showed a mild increase only in tumoral tissue ($\Delta C_t = 12.57$). *In vivo* evaluation of these two patients demonstrated a negative cortisol response to the Gn-RH test.

Immunohistochemistry Immunohistochemical data for LH/hCG-R performed in the tissue sample of our patient supported the real-time data. LH/hCG-R showed staining in placenta used as positive control and a moderate staining was observed in cells throughout the tumor sample (Fig. 5A and B).

Postoperative follow-up

After surgery, the patient began replacement therapy with acetate cortisone at 25 mg/day because of low cortisol levels (3.1 $\mu\text{g/dl}$) and she was then maintained with half this dose. Androgen levels returned to normal after surgery (testosterone: 11 ng/ml and DHEA-S: 0.5 $\mu\text{g/ml}$). Acetate cortisone therapy was tapered off after 7 months of follow-up. Clinical signs and symptoms of CS disappeared completely, the patient's menstrual cycle normalized, her weight dropped to 56.0 kg, and her blood pressure levels were normal in the absence of antihypertensive therapy. After 20 months of follow-up, she had normal UFC (51.0 $\mu\text{g}/24$ h) and plasma cortisol levels (9.7 $\mu\text{g/dl}$) and regular cortisol suppression after 1 mg dexamethasone overnight (0.6 $\mu\text{g/dl}$). ACTH levels were 33 pg/ml. Neither cortisol (baseline: 9.7 mmol/l, 30 min: 8.4 mmol/l, 60 min: 8 mmol/l, 90 min: 7 mmol/l, 120 min: 6.5 mmol/l) nor testosterone responses were observed after repeating the OGTT, we

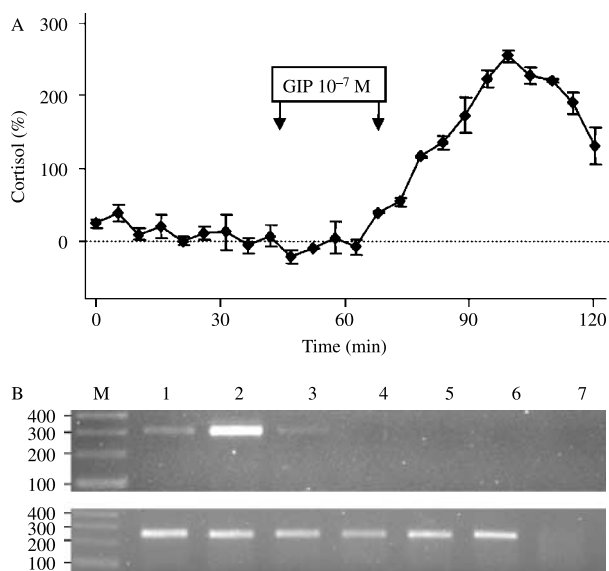


Figure 4 *In vitro* studies. (A) The pattern represents the result of perfusion study on tumor fragments. The panel shows the brisk response of cortisol to GIP perfusion (20 min, 10^{-7} M). Each point is the mean of two consecutive 5 min fractions. Basal spontaneous cortisol release was calculated as the mean of eight fractions immediately prior to the administration of the secretagogue. (B) RT-PCR analysis of GIP-R (upper panel) and PGK1 (lower panel) from a normal adult pancreas (lane 1), the adrenal macronodules and adjacent adrenal cortex of our patient (lanes 2 and 3), two cases of non-GIP-dependent macronodular adrenal hyperplasia (lanes 4 and 5), normal adult adrenal gland (lane 6), and negative control (lane 7). M, molecular marker.

Table 1 Quantification of luteinizing hormone (LH)-receptor mRNA levels in adrenal macronodules and peritumoral tissues, expressed as $2^{-\Delta\Delta C_t}$ mRNA LH/hCG/GAPDH, in samples from our patient glucose-dependent insulinotropic polypeptide receptor (GIP-R+) and another two patients with Cushing's syndrome due to non-GIP-dependent macronodular adrenal hyperplasia (GIP-R-).

	GIP-R+	GIP-R-	GIP-R-
Adrenal macronodules	94.34	6.88	0.51
Adjacent adrenal cortex	26.13	2.46	ND

ND, not done.

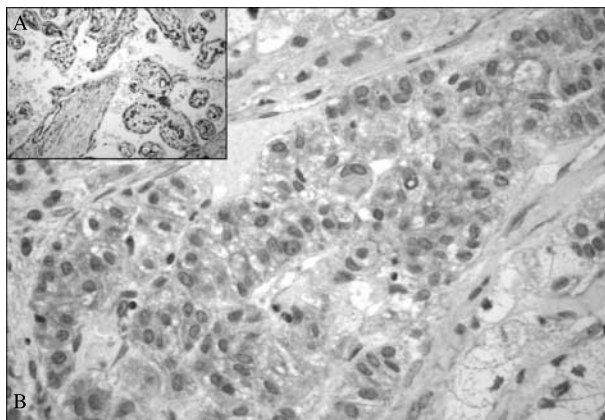


Figure 5 Immunohistochemical analysis of LH/hCG-receptor expression in placenta used as positive control (A) and in tumor sample of our patient (B).

observed a response to the hCG stimulation test for cortisol (50% above the baseline), testosterone (45% above the baseline), and 17-hydroxy-progesterone (40% above the baseline), whereas no response was detected for DHEA-S. The abdominal computed topography (CT) scan showed that the left adrenal nodule was 1.2 mm in size.

Discussion

In this case of food-dependent CS due to bilateral macronodular adrenal hyperplasia, GIP-R expression was demonstrated by *in vivo* and *in vitro* studies and a concomitant expression of the LH/hCG receptor was revealed in the adrenocortical tissue. Medical treatment with a long-acting somatostatin analog showed a partial response but unilateral adrenalectomy resulted in sustained remission after more than a 20-month follow-up.

GIP-dependent CS may differ from conditions of chronic and continuous high ACTH and cortisol secretion because plasma cortisol increases in response to food as an expression of a transient postprandial increase in GIP. These patients may have subtle signs and symptoms consistent with CS and this can delay the diagnosis (30); clinically overt CS usually becomes apparent only after several years, probably due to the low steroidogenic enzyme capacity of the hyperplastic tissue (31, 32). Patients with GIP-dependent CS usually have low morning plasma cortisol levels due to low fasting GIP levels and CRH and ACTH suppression due to hypercortisolism during the day. Our patient's ACTH levels were at the lower limit of normal and there was a slight response of ACTH to CRH stimulation. In fact, the hypothalamus–pituitary–adrenal axis may not be completely suppressed in GIP-dependent CS, probably because of intermittent food-dependent cortisol stimulation (5).

In our case, GIP-dependent CS was suggested by the *in vivo* cortisol response to food intake and the oral glucose challenge and was confirmed by *in vitro* studies. The GIP receptor had previously been demonstrated to be an ectopic or illicit receptor because no *in vitro* cortisol response to GIP was found in normal adult or fetal adrenal cells (6). It is not clear why the GIP receptor is expressed in these cases, considering that no mutations of either the full-length GIP-R or the promoter region were found in the affected adenomas or macronodular adrenal hyperplasias studied (9, 31).

Evaluating aberrant membrane receptor expression in adrenal tumor tissues has been proposed as an alternative to determining the physiopathological mechanisms involved in these rare forms of CS, but also as an opportunity to identify new therapeutic options. In previous reports, chronic s.c. octreotide administration thrice daily resulted in a transient decrease in UFC levels in patients with food-dependent CS due to the well-known inhibitory effects of somatostatin analogs on GIP levels (7, 8). In our patient, treatment with a long-acting somatostatin analog reduced UFC levels and inhibited cortisol response to OGTT, but UFC levels remained slightly above normal range and this could be explained by a different stimulation possibly due to the expression of other aberrant receptors. A long-term follow-up would be necessary to ascertain the real efficacy of this therapy over time.

Our patient also had an increase in androgen levels that make the case particularly interesting. Cortisol and androgen secretion by the adrenal glands is usually seen in patients with CS due to pituitary adenoma, while patients with adrenal adenomas may present a dissociation in cortisol and androgen secretion because of ACTH suppression due to high levels of cortisol being secreted irrespective of the pituitary stimulus. However, benign adrenal adenomas can secrete both cortisol and androgens (33), suggesting that stimuli other than ACTH can also regulate adrenal androgen synthesis (15).

In our case, we demonstrated *in vitro* the concomitant release of adrenal androgens and cortisol from adrenal tissue perfused with GIP. This situation has been previously described in a patient with an adrenocortical adenoma leading to hirsutism and subclinical CS (12). However, Bertherat *et al.* (14) identified two patients with CS due to adrenal hyperplasia that responded to both gonadotropin and GIP stimulation, demonstrating that ACTH-independent adrenocortical tissues may simultaneously express multiple illegitimate membrane receptors.

Early studies suggested that gonadal tissue in the adrenal glands might be implicated in androgen secretion in adrenal tumors responding to LH or hCG stimulation with an increase in androgen levels (34, 35). *In situ* hybridization studies have demonstrated LH/hCG-receptor mRNA transcripts in human

adrenal sections and, particularly, in the reticularis zone as a whole and in the deeper layer of the fasciculata zone (15). However, hCG seems to have a functional role in stimulating the production of DHEA-S from fetal but not from adult adrenal cells (15, 36), so a cellular event must occur in adrenal neoplasms secreting steroids in response to LH and hCG that enables the normally expressed LH/hCG receptor to trigger steroidogenesis. In some rare cases, CS may become evident in states of high LH/hCG levels (pregnancy and menopause) and cortisol secretion may be stimulated by LH and hCG, and inhibited by leuprolide acetate (16). Moreover, LH-receptor expression has been found in a pure testosterone-secreting bilateral macronodular adrenal hyperplasia (25) and in a cortisol-secreting adrenocortical carcinoma (17).

By real-time PCR, we found a concomitant mRNA expression of GIP and LH/hCG receptors in the adrenocortical tissue in our patient. However, an *in vivo* preoperative cortisol response to food intake but not to Gn-RH stimulation was detected. After surgery, the finding of the LH/hCG-receptor expression in tumoral tissue led us to perform an hCG stimulation test that revealed a moderate response of cortisol and androgen levels of the contralateral adrenal gland. Therefore, we suppose that the lack of *in vivo* cortisol response to Gn-RH may be due to a modest LH increment seen after a single Gn-RH stimulus that could be not strong enough to stimulate cortisol secretion. Moreover, oral contraceptives taken for 2 years and the state of hypercortisolism may have influenced the effect of LH levels on adrenal steroidogenesis.

The patient presented a completed full-term pregnancy with no reported signs or symptoms of hypercortisolism 6 years before CS was diagnosed. It was demonstrated recently that the expression of a single non-mutated LH/hCG-R or GIP-R gene transduced in bovine adrenocortical cells and transplanted in mice is itself sufficient to enable the formation of hyperplastic adrenal tissue and cause the onset of a benign adrenocortical tumor (37, 38). These data confirm a previous report demonstrating that LH receptor can act as an adrenocortical tumor promoter when ectopically expressed in the adrenal cortex of castrated transgenic mice (39). Whether the patient's high levels of circulating hCG during her pregnancy could have influenced the onset of hyperplastic/tumoral adrenal tissue is open to debate.

Bilateral adrenalectomy is considered the treatment of choice in patients with macronodular adrenal hyperplasia, but unilateral adrenalectomy has been recommended in selected cases (26, 27). Adrenalectomy of the larger gland with the prevalent uptake at scintiscan sufficed in our patient to achieve long-term remission after surgery. The likelihood of adrenal adenoma with a contralateral adrenal incidentaloma was discharged because histological findings were clearly indicative of macronodular adrenal hyperplasia,

adrenal scintigraphy with I¹³¹-norcholesterol showed a bilateral uptake, and LH/hCG and GIP receptors were also expressed in the cortical tissue surrounding the macronodule, suggesting the probability of bilateral lesions. The patient needed therapy with acetate cortisone for several months at a low dosage, probably because the remaining adrenal did actually secrete some, but not enough, cortisol, which would be in agreement with the hypothesis that these GIP-dependent hyperplastic adrenal tissues have a low secretion rate. These data confirm that unilateral adrenalectomy can be a safe alternative in some selective patients with adrenal hyperplasia, avoiding the need for lifelong glucocorticoid and mineralocorticoid replacement therapy. A long-term follow-up is indicated, however, due to the possibility of an asynchronous progression of nodule formation (27).

In some patients, the presence of aberrant hormone receptors enables a specific pharmacological treatment, but long-term studies are warranted to evaluate the real efficacy of medical treatment in such cases.

References

- 1 Stratakis CA & Kirschner LS. Clinical and genetic analysis of primary bilateral adrenal diseases (micro- and macronodular disease) leading to Cushing syndrome. *Hormone Metabolic Research* 1998 **30** 456–463.
- 2 Lacroix A, N'Diaye N, Tremblay J & Hamet P. Ectopic and abnormal hormone receptors in adrenal Cushing's syndrome. *Endocrine Reviews* 2001 **22** 75–110.
- 3 Hamet P, Larochelle P, Franks DJ, Cartier P & Bolte E. Cushing's syndrome with food-dependent periodic hormonogenesis. *Clinical and Investigative Medicine* 1987 **10** 530–533.
- 4 Pralong FP, Gomez F, Guillou L, Mosimann F, Franscella S & Gaillard RC. Food-dependent Cushing's syndrome: possible involvement of leptin in cortisol hypersecretion. *Journal of Clinical Endocrinology and Metabolism* 1999 **84** 3817–3822.
- 5 Croughs RJ, Zelissen PM, van Vroonhoven TJ, Hofland LJ, N'Diaye N, Lacroix A & de Herder WW. GIP-dependent adrenal Cushing's syndrome with incomplete suppression of ACTH. *Clinical Endocrinology* 2000 **52** 235–240.
- 6 Lacroix A, Bolte E, Tremblay J, Dupre J, Poitras P, Fournier H, Garon J, Garrel D, Bayard F, Taillefer R *et al.* Gastric inhibitory polypeptide-dependent cortisol hypersecretion – a new cause of Cushing's syndrome. *New England Journal of Medicine* 1992 **327** 974–980.
- 7 Reznik Y, Allali-Zerah V, Chayvialle JA, Leroyer R, Leymarie P, Travert G, Lebrethon MC, Budi I, Balliere AM & Mahoudeau J. Food-dependent Cushing's syndrome mediated by aberrant adrenal sensitivity to gastric inhibitory polypeptide. *New England Journal of Medicine* 1992 **327** 981–986.
- 8 Lebrethon MC, Avallet O, Archambault F, Combes J, Usdin TB, Narboni G, Mahoudeau J & Saez JM. Food-dependent Cushing's syndrome: characterization and functional role of gastric inhibitory polypeptide receptor in the adrenals of three patients. *Journal of Clinical Endocrinology and Metabolism* 1998 **83** 4514–4519.
- 9 N'Diaye N, Tremblay J, Hamet P, De Herder WW & Lacroix A. Adrenocortical overexpression of gastric inhibitory polypeptide receptor underlies food-dependent Cushing's syndrome. *Journal of Clinical Endocrinology and Metabolism* 1998 **83** 2781–2785.
- 10 Chabre O, Liakos P, Vivier J, Chaffanjon P, Labat-Moleur F, Martinie M, Bottari SP, Bachelot I, Chambaz EM, Defaye G & Feige JJ. Cushing's syndrome due to a gastric inhibitory

- polypeptide-dependent adrenal adenoma: insights into hormonal control of adrenocortical tumorigenesis. *Journal of Clinical Endocrinology and Metabolism* 1998 **83** 3134–3143.
- 11 De Herder WW, Hofland LJ, Usdin TB, de Jong FH, Uitterlinden P, Van Koetsveld P, Mezey E, Bonner TI, Bonjer HJ & Lamberts SW. Food-dependent Cushing's syndrome resulting from the abundant expression of gastric inhibitory polypeptide receptors in adrenal adenoma cells. *Journal of Clinical Endocrinology and Metabolism* 1996 **81** 3168–3172.
 - 12 Tsagarakis S, Tsigos C, Vassiliou V, Tsiotra P, Pratsinis H, Kletsas D, Trivizas P, Nikou A, Mavromatis T, Sotsiou F *et al*. Food-dependent androgen and cortisol secretion by a gastric inhibitory polypeptide-receptor expressive adrenocortical adenoma leading to hirsutism and subclinical Cushing's syndrome: *in vivo* and *in vitro* studies. *Journal of Clinical Endocrinology and Metabolism* 2001 **86** 583–589.
 - 13 Groussin L, Jullian E, Perlemonne K, Louvel A, Leharp B, Luton JP, Bertagna X & Bertherat J. The ectopic expression of the gastric inhibitory polypeptide receptor is frequent in adrenocorticotropin-independent bilateral macronodular adrenal hyperplasia, but rare in unilateral tumors. *Journal of Clinical Endocrinology and Metabolism* 2002 **87** 1980–1985.
 - 14 Bertherat J, Contesse V, Louiset E, Barrande G, Duparc C, Groussin L, Emy P, Bertagna X, Kuhn JM, Vaudry H *et al*. *In vivo* and *in vitro* screening for illegitimate receptors in adrenocorticotropin-independent macronodular adrenal hyperplasia causing Cushing's syndrome: identification of two cases of gonadotropin/gastric inhibitory polypeptide-dependent hypercortisolism. *Journal of Clinical Endocrinology and Metabolism* 2005 **90** 1302–1310.
 - 15 Pabon JE, Li X, Lei ZM, Sanfilippo JS, Yussman MA & Rao CV. Novel presence of luteinizing hormone/chorionic gonadotropin receptors in human adrenal glands. *Journal of Clinical Endocrinology and Metabolism* 1996 **81** 2397–2400.
 - 16 Lacroix A, Hamet P & Boutin JM. Leuprolide acetate therapy in luteinizing hormone-dependent Cushing's syndrome. *New England Journal of Medicine* 1999 **341** 1577–1581.
 - 17 Wy LA, Carlson HE, Kane P, Li X, Lei ZM & Rao CV. Pregnancy-associated Cushing's syndrome secondary to a luteinizing hormone/human chorionic gonadotropin receptor-positive adrenal carcinoma. *Gynecological Endocrinology* 2002 **16** 413–417.
 - 18 Givens JR, Andersen RN, Wisner WL, Coleman SA & Fish SA. A gonadotropin-responsive adrenocortical adenoma. *Journal of Clinical Endocrinology and Metabolism* 1974 **38** 126–133.
 - 19 Blichert-Toft M, Vejlsted H, Hehlet H & Albrechtsen R. Virilizing adrenocortical adenoma responsive to gonadotrophin. *Acta Endocrinologica* 1975 **78** 77–85.
 - 20 Leinonen P, Ranta T, Sieberg R, Pelkonen R, Heikkilä P & Kahri A. Testosterone-secreting virilizing adrenal adenoma with human chorionic gonadotropin receptors and 21-hydroxylase deficiency. *Clinical Endocrinology* 1991 **34** 31–35.
 - 21 Lószló FA, Tóth S, Kocsis J, Pávó I & Szécsi M. Testosterone-secreting gonadotropin-responsive adrenal adenoma and its treatment with the antiandrogen flutamide. *Journal of Endocrinological Investigation* 2001 **24** 622–627.
 - 22 Werk EE Jr, Sholiton LE & Kalejs L. Testosterone-secreting adrenal adenoma under gonadotropin control. *New England Journal of Medicine* 1973 **289** 767–770.
 - 23 Takahashi H, Yoshizaki K, Kato H, Masuda T, Matsuka G, Mimura T, Inui Y, Takeuchi S, Adachi H & Matsumoto K. A gonadotrophin-responsive virilizing adrenal tumour identified as a mixed ganglioneuroma and adrenocortical adenoma. *Acta Endocrinologica* 1978 **89** 701–709.
 - 24 De Lange WE, Pratt JJ & Doorenbos H. A gonadotrophin responsive testosterone producing adrenocortical adenoma and high gonadotrophin levels in an elderly woman. *Clinical Endocrinology* 1980 **12** 21–28.
 - 25 Goodarzi MO, Dawson DW, Li X, Lei Z, Shintaku P, Rao CV & Van Herle AJ. Virilization in bilateral macronodular adrenal hyperplasia controlled by luteinizing hormone. *Journal of Clinical Endocrinology and Metabolism* 2003 **88** 73–77.
 - 26 Lamas C, Alfaro JJ, Lucas T, Lecumberri B, Barceló B & Estrada J. Is unilateral adrenalectomy an alternative treatment for ACTH-independent macronodular adrenal hyperplasia? Long-term follow-up of four cases. *European Journal of Endocrinology* 2002 **146** 237–240.
 - 27 N'Diaye N, Hamet P, Tremblay J, Boutin JM, Gaboury L & Lacroix A. Asynchronous development of bilateral nodular adrenal hyperplasia in gastric inhibitory polypeptide-dependent Cushing's syndrome. *Journal of Clinical Endocrinology and Metabolism* 1999 **84** 2616–2622.
 - 28 Ferriman D & Gallwey J. Clinical assessment of body hair growth in women. *Journal of Clinical Endocrinology and Metabolism* 1961 **21** 1440–1447.
 - 29 Lacroix A, Mircescu H & Hamet P. Clinical evaluation of the presence of abnormal hormone receptors in adrenal Cushing's syndrome. *Endocrinologist* 1999 **9** 9–15.
 - 30 Swain JM, Grant CS, Schlinkert RT, Thompson GB, vanHeerden JA, Lloyd RV & Young WF. Corticotropin-independent macronodular adrenal hyperplasia: a clinicopathologic correlation. *Archives of Surgery* 1998 **133** 541–545.
 - 31 Antonini SR, N'Diaye N, Baldacchino V, Hamet P, Tremblay J & Lacroix A. Analysis of the putative regulatory region of the gastric inhibitory polypeptide receptor gene in food-dependent Cushing's syndrome. *Journal of Steroid Biochemistry and Molecular Biology* 2004 **91** 171–177.
 - 32 Christopoulos S, Bourdeau I & Lacroix A. Clinical and subclinical ACTH-independent macronodular adrenal hyperplasia and aberrant hormone receptors. *Hormone Research* 2005 **64** 119–131.
 - 33 Danilowicz K, Albiger N, Vanegas M, Gomez RM, Cross G & Bruno OD. Androgen-secreting adrenal adenomas. *Obstetrics and Gynecology* 2002 **100** 1099–1102.
 - 34 Trost BN, Koenig MP, Zimmermann A, Zachmann M & Muller J. Virilization of a post-menopausal woman by a testosterone-secreting Leydig cell type adrenal adenoma. *Acta Endocrinologica* 1981 **98** 274–282.
 - 35 Vasiloff J, Chideckel EW, Boyd CB & Foshag LJ. Testosterone-secreting adrenal adenoma containing crystalloids characteristic of Leydig cells. *American Journal of Medicine* 1985 **79** 772–776.
 - 36 Seron-Ferre M, Lawrence CC & Jaffe RB. Role of hCG in regulation of the fetal zone of the human fetal adrenal gland. *Journal of Clinical Endocrinology and Metabolism* 1978 **46** 834–837.
 - 37 Mazzucco TL, Chabre O, Feige JJ & Thomas M. Aberrant expression of human luteinizing hormone receptor by adrenocortical cells is sufficient to provoke both hyperplasia and Cushing's syndrome features. *Journal of Clinical Endocrinology and Metabolism* 2006 **91** 196–203.
 - 38 Mazzucco TL, Chabre O, Sturm N, Feige JJ & Thomas M. Ectopic expression of the gastric inhibitory polypeptide receptor gene is a sufficient genetic event to induce benign adrenocortical tumor in a xenotransplantation model. *Endocrinology* 2006 **147** 782–790.
 - 39 Rilianawati Pauku T, Kero J, Zhang FP, Rahman N, Kananen K & Huhtaniemi I. Direct luteinizing hormone action triggers adrenocortical tumorigenesis in castrated mice transgenic for the murine inhibin α -subunit promoter/simian virus 40 T-antigen fusion gene. *Molecular Endocrinology* 1998 **12** 801–809.

Received 30 August 2007

Accepted 13 September 2007