

CASE REPORT

Complete disappearance of a GH-secreting pituitary macroadenoma in a patient with acromegaly: effect of treatment with lanreotide Autogel and consequence of treatment withdrawal

Renata S Auriemma, Mariano Galdiero, Ludovica F S Grasso, Pasquale Vitale, Alessia Cozzolino, Gaetano Lombardi, Annamaria Colao and Rosario Pivonello

Department of Clinical and Molecular Endocrinology and Oncology, 'Federico II' University of Naples, Via S. Pansini 5, 80131 Naples, Italy

(Correspondence should be addressed to R Pivonello; Email: rpivone@tin.it)

Abstract

Background: Somatostatin analogs (SA) are the cornerstone in the medical treatment of acromegaly, used as either primary or adjunctive therapy. In particular, SA are effective in inducing the biochemical remission of the disease and tumor shrinkage, although only few cases of complete disappearance of the pituitary tumor in patients treated with SA as long-acting formulations have been reported. SA withdrawal has been demonstrated to keep safe levels of GH and IGF1 at least in a small subset of patients well responsive to SA, although it is generally followed by disease recurrence after several months.

Case report: A 61-year-old female patient bearing a very large GH-secreting pituitary macroadenoma was treated with 12-month lanreotide Autogel (ATG), at the initial dose of 120 mg/28 days. After 3 months, GH and IGF1 levels were fully normalized, to prolong the administration interval from 28 to 56 days. After 6 months of treatment, a significant tumor shrinkage (90% of baseline size) was observed, whereas GH and IGF1 excess was still well controlled. After 12-month therapy, a complete disappearance of the pituitary tumor was observed, and the hormonal evaluation confirmed the complete biochemical remission of acromegaly. Lanreotide ATG treatment was withdrawn. The clinical, biochemical, and radiological remission of acromegaly was maintained 24 months after lanreotide ATG treatment discontinuation, without evidence of disease recurrence.

Conclusions: This report represents an exemplary case of the potentiality of treatment with lanreotide ATG in inducing a complete remission of acromegalic disease, persistent after a long period of time from treatment withdrawal.

European Journal of Endocrinology 162 993–999

Introduction

Acromegaly is a rare and severe systemic disease caused by a GH-secreting pituitary adenoma, inducing GH and insulin-like growth factor 1 (IGF1) excess (1). Currently available therapies for acromegaly include transphenoidal neurosurgery, radiotherapy, and medical therapy with the dopamine agonists and somatostatin analogs (SA). A new engineered GH receptor antagonist, pegvisomant, has recently been shown to be effective in normalizing IGF1 excess in the great majority of patients, including those who have demonstrated resistance to SA (2). The goal of these therapies is to normalize GH and IGF1 levels, to improve the clinical signs and symptoms of acromegaly, and to reduce tumor size in order to relieve any symptom due to tumor mass (3). SA, both octreotide and lanreotide, have been demonstrated to be the cornerstone of medical treatment during the last 15 years with their acceptability,

increased by the development of depot preparations. SA improve symptoms and signs of acromegaly in the majority of patients, induce the achievement of biochemical targets for both GH and IGF1 levels in 44–77% of patients, and induce tumor shrinkage in at least 41.5% of patients (4–8). Particularly, the long-acting SA lanreotide has been found to be well tolerated and effective in reducing GH and IGF1 levels as well as the tumor mass in a high percentage of patients previously either untreated or treated by unsuccessful neurosurgery for acromegaly (7–27). Only three cases of total biochemical and/or radiological remission of a GH-secreting pituitary adenoma after medical therapy with long-acting SA have been reported (28–30). Moreover, few data on the effects of SA therapy discontinuation on disease control are presently available, and the majority of the authors reported the disease recurrence during a short follow-up. In a recent multicenter study, Ronchi *et al.* (10) reported the

successful withdrawal of SA with the complete biochemical control of acromegaly in five out of 27 recruited patients after 12 months, without evidence of disease recurrence. No previous study has reported the complete disappearance of GH-secreting pituitary macroadenoma after medical treatment with lanreotide Autogel (ATG). The aim of the present study is to describe the clinical case of a patient with acromegaly, who showed the clinical and biochemical remission of acromegaly simultaneously with the complete disappearance of an invasive GH-secreting pituitary macroadenoma after first-line treatment with ATG, without evidence of disease recurrence 24 months after drug discontinuation. A revision of the literature regarding this topic is also performed and discussed in relation to this case report.

Case report

A 61-year-old woman was admitted in our department on September 2001. The medical history revealed systemic arterial hypertension treated with angiotensin-converting enzyme inhibitors, inadequately controlled type II diabetes mellitus treated with insulin sensitizers, rheumatoid arthritis treated with steroids, all diagnosed 10 years previously, and carpal tunnel syndrome surgically treated 3 years previously. At the physical examination, the patient showed acral and tongue enlargement and prognathism. Severe asthenia,

mild perspiration, soft tissue swelling, joint pain, and paresthesia were also referred. She also experienced recurring headache and progressive reduction of visual field during the last 8 years until the diagnosis of complete bitemporal hemianopsia, which had been done 2 months before we met the patient. These findings suggested the diagnosis of acromegaly. The evaluation of the pituitary function showed increased GH (10.2 µg/l) and IGF1 (753 µg/l) levels. No GH assessment by oral glucose tolerance test was performed because of poorly controlled type II diabetes mellitus. No deficit of other pituitary trophins was found. The magnetic resonance imaging (MRI) of the hypothalamus–pituitary region showed the presence of an intrasellar pituitary macroadenoma (volume: 784.2 mm³), with a large suprasellar extension impinging the optic chiasm (Fig. 1). In line with the standard diagnostic criteria (31), a diagnosis of acromegaly due to an intrasellar and suprasellar GH-secreting pituitary macroadenoma, complicated by systemic arterial hypertension and type II diabetes mellitus, was performed. Patient's profile at baseline is shown in Table 1. In order to restore both pituitary function and visual field, neurosurgery was proposed as first-line treatment, but the patient refused. In December 2001, a treatment with ATG as s.c. administration was started at the initial dosage of 120 mg every 28 days. GH and IGF1 assessment as well as glucose and lipid profile, systolic blood pressure and diastolic blood pressure,

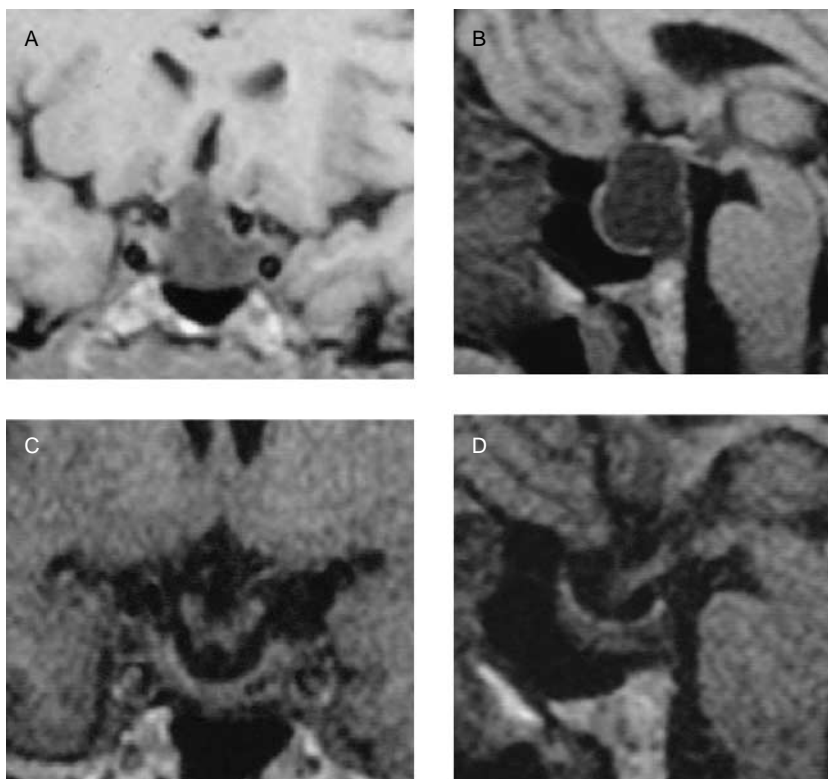


Figure 1 Pituitary MRI images at baseline (coronal (A, left) and sagittal (B, right) view) and after 12 months of treatment with ATG (coronal (C, left) and sagittal (D, right) view).

Table 1 Patient profile before and after 12-month therapy with Autogel (ATG), and 24 months after ATG withdrawal.

Parameters	Baseline	12 months after ATG	24 months after ATG discontinuation
Weight (kg)	85	75.5	82
BMI (kg/m ²)	31.25	27.75	30.1
GH (μg/l)	7.2	1.2	1.7
IGF1 (μg/l)	1071	208	174
SBP (mmHg)	140	130	130
DBP (mmHg)	90	80	80
Fasting glucose (mg/dl)	185	123	100
HbA1c (%)	8.3	7.1	6.7
Total cholesterol (mg/dl)	229	222	198
HDL cholesterol (mg/dl)	49	54	54
Triglycerides (mg/dl)	255	162	156
AST (IU/l)	14	15	14
ALT (IU/l)	10	9	9
Alkaline phosphatase (IU/l)	121	60	71
γGT (IU/l)	6	10	12

and visual field evaluation was performed at baseline and then monthly for the first 3 months. At baseline, GH and IGF1 levels were respectively 7.2 and 1071 μg/l. After one month of treatment, GH (2.15 μg/l) and IGF1 (518 μg/l) levels were reduced compared to baseline values, and the symptoms were clearly improved. After 3 months of treatment, GH (1.2 μg/l) and IGF1 (241 μg/l) levels were completely normalized indicating biochemical remission of pituitary disease. We also observed a relevant improvement in the visual field, consisting of a partial deficit in the upper section of the right eye associated with the complete normalization of visual field of the left eye. On the basis of these findings, the interval between the ATG administrations was prolonged from 28 to 56 days. Six months after treatment starting, GH and IGF1 were still in the normal range (1.6 and 215 μg/l respectively), and tumor mass was dramatically reduced by 90% (volume: 77.8 mm³). After 12 months of treatment, GH and IGF1 continued to be fully normalized (1.2 and 208 μg/l respectively, Table 1). GH and IGF1 profile before, during, and after treatment with ATG is shown in Fig. 2. Other pituitary trophins were still within normal range. Pituitary MRI detected no tumor mass and showed a secondary empty sella with the complete disappearance of the macroadenoma (Fig. 1). Moreover, no visual disturbance was referred by the patient, and at physical examination, the visual field was completely normalized. Glucose and lipid profile, as well as blood pressure, also improved, as shown in Table 1. In particular, fasting glucose levels decreased significantly, requiring the reduction of insulin sensitizer dosage. On the basis of the clinical, biochemical, and radiological remission of acromegaly and of the total tumor shrinkage, 9 months after the achievement of disease control and 6 months after tumor disappearance, the treatment with ATG was withdrawn. Then, hormonal and metabolic profile was evaluated every 3 months, whereas the pituitary MRI was repeated yearly. During the following 24 months, acromegaly remained completely recovered because of

persistent safe GH and IGF1 levels in association with the secondary empty sella, in the absence of visible tumor mass at pituitary MRI. Glucose and lipid profile, as well as blood pressure, was also well controlled, resulting in a slight although not significant improvement. No symptom and sign of acute hepatic or biliary problems were documented during ATG treatment and after drug withdrawal. Nowadays, pituitary function is still within the normal range, and pituitary MRI is stable, showing a secondary empty sella without visible tumor mass.

Methods

Hormone assays

Serum GH and IGF1 levels were measured by chemiluminescent immunometric assay using commercially available kits (respectively Immulite GH and Immulite IGF1, DPC, Llanberis, UK). For GH assays, the analytical sensitivity was 0.05 μg/l; intra-assay and inter-assay coefficient of variation (CV) values were 5.3–6.5 and 5.5–6.2% respectively. For IGF1 assays, the analytical sensitivity was 20 μg/l; intra-assay and inter-assay CV values were 3.1–6.1 and 3.2–6.0% respectively. The normal range in males and females who were aged ≤25, 26–30, 31–35, 36–40, 41–45, 46–50, 51–55, 56–60, 61–65, 66–70, and ≥70 years was 116–358, 117–329, 115–307, 109–284, 101–267, 94–252, 87–238, 81–225, 75–212, 69–200, and 64–166 μg/l respectively.

Pituitary magnetic resonance and visual perimetry

MRI examination was performed on 1.5T scanners, using a T1-weighted gradient-recalled echo (repetition time 200–300 ms; echo-time 10–12 ms; flip angle 90°) in sagittal and coronal planes. In each measurement, 7–10 slides were obtained with a slice thickness of 2–3 mm. The scans were repeated before and after

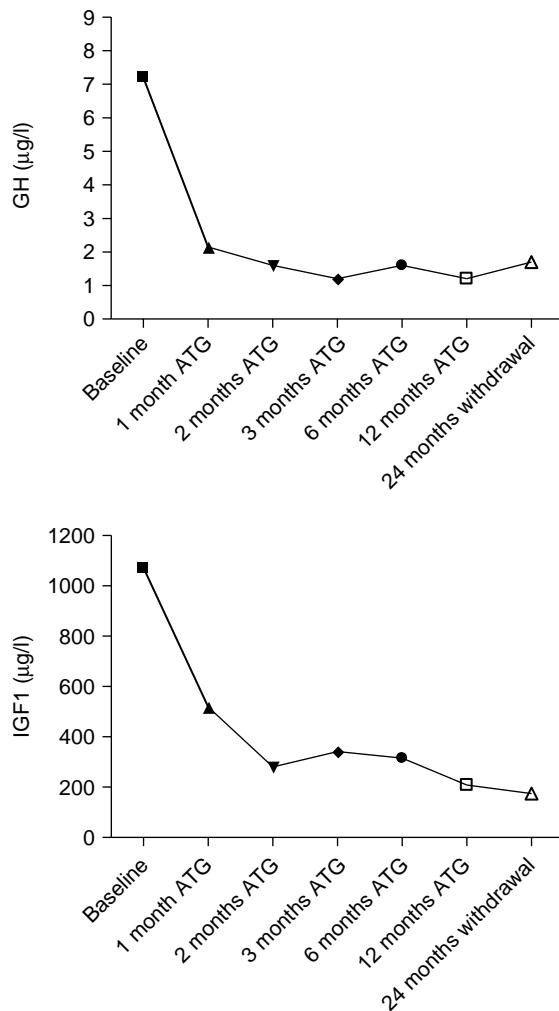


Figure 2 GH (top) and IGF1 (bottom) levels at baseline, and during and after 12-month treatment with lanreotide Autogel.

the administration of 0.1 mmol diethylenetriamine pentacetate–gadolinium chelate. The patient was placed in the same position in each examination to obtain slices as comparable as possible. Tumor volume was calculated in line with the Di Chiro & Nelson formula (volume = height \times length \times width \times $\pi/6$). MRI was performed before and 12 months after treatment with ATG, and then 12 and 24 months after drug discontinuation. The evaluation of visual field was performed by Goldmann–Friedmann perimetry. The ophthalmological examination was performed at baseline and 3, 6, and 12 months after ATG therapy, and then repeated 12 and 24 months after ATG withdrawal.

Discussion

The present study first demonstrates the effectiveness of ATG in inducing the normalization of GH and IGF1 levels together with the complete disappearance of an invasive GH-secreting pituitary macroadenoma,

maintaining disease remission without evidence of recurrence 24 months after ATG discontinuation in an acromegalic patient.

The long-acting SA lanreotide has been found to be effective in improving invasive symptoms of acromegaly in a high percentage of patients, normalizing GH levels in 63% and IGF1 levels in 65% of patients, and inducing tumor shrinkage in 50% of patient receiving lanreotide as primary treatment (11, 12). An open label study on 104 patients has demonstrated that pre-surgical treatment with lanreotide induced a significant decrease in GH and IGF1 levels, particularly in previously untreated and newly diagnosed acromegalic patients (13). Moreover, despite the short duration of pre-surgical treatment, lanreotide induced normalization of IGF1 levels in 25% of patients and reduced tumor mass in up to 60% of them (13, 14), with a tumor shrinkage greater than 20% in 29% of patients. These data on lanreotide are in line with the demonstration that first-line SA therapy is able to improve clinical conditions and surgical outcome (15, 16), induce a better biochemical disease control, and reduce the duration of hospitalization after surgery and the prevalence of secondary hypopituitarism (32). As shown in Table 2, previous studies have shown that octreotide long-acting release (LAR) and lanreotide, both as slow-release (SR) and ATG formulations, are very effective in inducing hormone control and tumor shrinkage in acromegalic patients, reporting a reduction in tumor mass rate of 31.1–82% (7, 8, 17–25). Particularly, in the review by Bevan *et al.* (8), tumor shrinkage was found in 51% of patients receiving SA as first-line treatment and in 27% of patients treated after unsuccessful surgery and/or radiotherapy. Similarly, Melmed (22) reported that a significant tumor shrinkage is more frequently induced by primary than adjunctive medical therapy with SA. Recently, no relevant difference has been reported between octreotide-LAR and lanreotide-SR in terms of clinical and biochemical improvement, as well as tumor mass shrinkage (7, 20). Furthermore, we have also demonstrated (21) that ATG, when administered as first-line therapy in newly diagnosed acromegalic patients, induced biochemical control of the disease in up to 50% of patients and a tumor shrinkage greater than 25% in up to 60% of patients treated for 6 months and in up to 75% after 12 months. Moreover, we found (33) that a significant tumor shrinkage can be obtained not only in fully responsive patients but also in resistant patients after an adequate dose adjustment to cause the maximal suppression of GH and IGF1. Only few studies (21, 26, 34) have investigated the effects of ATG on tumor mass in patients with acromegaly, reporting a mean tumor volume shrinkage of 32.8–44% of patients. The present paper first describes a case of an acromegalic patient in whom the efficacy of ATG in inducing GH and IGF1 excess control was associated with the complete disappearance of the invasive

Table 2 Effects of somatostatin analogs (SA), octreotide subcutaneous (SC), octreotide-LAR, and lanreotide (SR and Autogel) on tumor volume shrinkage in acromegaly.

First author (year)	References no.	SA type	SA duration (months)	Shrinkage prevalence (%)
Colao (1999)	(17)	SC, SR-L	6	25 (SC), 5 (SR-L)
Amato (2002)	(19)	SR-L, LAR	12	26.5 (SR-L), 31.1 (LAR)
Auriemma (2008)	(20)	LAR, SR-L	12	51.8 (LAR), 45.6 (SR-L)
Colao (2009)	(21)	ATG	6–12	61.5 (6 months); 76.9 (12 months)
Colao (2006)	(23)	LAR, SR-L	12	75.7
Maiza (2007)	(24)	All	96 (Mean duration)	72
Cozzi (2006)	(25)	LAR, SR-L	48 (Mean duration)	62
Mazziotti (2009)	(34)	SR-L, ATG	NA	32.8
Attanasio (2008)	(26)	ATG	12	44

LAR, octreotide-LAR; SR-L, lanreotide-SR; ATG, lanreotide Autogel.

pituitary macroadenoma. Only three previous clinical cases in the literature ((28–30), Table 3) reported the complete biochemical and/or radiological remission of acromegaly after long-term treatment with SA, but some differences between these cases and the present one can be found. In the case reported by Resmini *et al.* (28), the complete disappearance of the pituitary tumor in a newly diagnosed acromegalic patient has been induced by 18-month therapy with octreotide-LAR; in this case report, the disappearance of tumor mass was not associated with the biochemical control of acromegaly, demonstrating the dissociation between the anti-proliferative and anti-secretive effect of octreotide-LAR. In the paper by Livadas (29), tumor disappearance has been obtained after long-term first-line therapy with lanreotide-SR, administered at the dosage of 30 mg every 2 weeks; after the achievement of disease remission, medical treatment was withdrawn. Avramidis (30) has documented the complete biochemical remission of acromegaly induced by therapy with octreotide-LAR in a patient with a stable residual of a pituitary macroadenoma previously treated with first-line neurosurgery, followed by the recurrence of the adenoma 6 months after therapy discontinuation (30). Thus, the present paper is the first demonstrating the complete clinical and biochemical remission simultaneously with the complete disappearance of an invasive GH-secreting pituitary macroadenoma after treatment with ATG. Moreover, the recurrence-free time is different: 6 months in the report by Livadas, 6 years in the one by Avramidis, and 24 months in the present study. In the paper by Ronchi *et al.* (10), 27 acromegalic

patients (12 primarily treated and 15 post-surgical patients) received long-acting SA treatment for at least 12 months, with a median therapy duration of 48 months. Among patients, eleven had octreotide-LAR at the dosage of 10 mg (four patients), 20 mg (five patients), and 30 mg (two patients) every 28 days; nine had 60 mg lanreotide-SR every 28 days and seven had 120 mg ATG every 28 (one patient), 42 (three patients), and 56 (three patients) days. After the achievement of biochemical control by SA, all patients underwent a short-term therapy withdrawal (3–4 months), which was then prolonged up to 12 months in the case of persistent disease remission. During the study, 15 patients showed a rapid disease re-activation after short-term discontinuation, whereas 12 patients maintained biochemical control for longer than 3 months and nine patients for longer than 6 months. At the end of the study, only five (one primarily treated and four post-surgical) out of 27 recruited patients exceeded the follow-up by over 12 months.

The mechanisms responsible for the long-term biochemical and radiological remission observed in our patient are still unclear. SA are known to inhibit angiogenesis in tumors, both by a direct action on endothelial cells and indirect action on angiogenic growth factors release (27). Moreover, SA have shown also an anti-proliferative effect because of their cytostatic and cytotoxic actions (35). Also the distribution of somatostatin receptors determines hormone and tumor volume response to SA therapy, with the best response in those patients with high density and homogeneously distributed receptors on the pituitary tumor (36).

Table 3 Effects of long-acting somatostatin analog (SA) formulations withdrawal in patients with acromegaly: revision of previous clinical case reports.

First author (year)	References no.	SA type	SA duration (months)	Biochemical remission (yes/no)	Tumor disappearance (yes/no)	Recurrence-free time (months)
Resmini (2005)	(28)	LAR	18	No	Yes	NA
Livadas (2006)	(29)	SR-L	62	No	Yes	6
Avramidis (2008)	(30)	LAR	96	Yes	No	72

LAR, octreotide-LAR; SR-L, lanreotide-SR; ATG, lanreotide Autogel.

In a recent study (37), Taboada *et al.* evaluated somatostatin receptor subtype (sstr) expression profile by quantitative real-time RT-PCR, reporting a positive correlation between sstr2 levels and the percentage decrease in GH and IGF1 after treatment with SA, with a higher sstr2/sstr5 ratio among patients well controlled by medical therapy. Similarly, Pawlikowski *et al.* (38) reported that the GH-inhibiting effect of SA octreotide depends on the intensity of expression of both sstr2a and sstr2b isoforms. However, since no surgery was performed in our patient, no molecular study of the tumor was possible.

In conclusion, this case report firstly demonstrated the complete biochemical and radiological remission of acromegaly, without disease recurrence over 24 months, after primary therapy with ATG, suggesting that lanreotide ATG might be very effective in the treatment of acromegaly: its chronic administration can normalize GH and IGF1 levels and above all significantly shrinks tumor mass until its disappearance. Furthermore, this case firstly documented that biochemical and radiological remission induced by lanreotide ATG can be maintained during a long-term follow-up, at least in some 'very sensitive' patients. Since a long-term follow-up is mandatory to confirm the persistence of remission after treatment withdrawal, this case suggests the possibility that lanreotide ATG might also be considered a definitive treatment in selective patients with acromegaly.

Declaration of interest

The authors declare that there is no conflict of interest that could be perceived as prejudicing the impartiality of the research reported.

Funding

This study did not receive any specific grant from any funding agency in the public, commercial, or not-for-profit sector.

References

- Melmed S. Acromegaly. *New England Journal of Medicine* 2006 **355** 2558–2573.
- Colao A, Auriemma RS, Pivonello R, Galdiero M & Lombardi G. Medical consequences of acromegaly: what are the effects of biochemical control? *Reviews in Endocrine & Metabolic Disorders* 2008 **9** 21–31.
- Freda PU. How effective are current therapies for acromegaly? *Growth Hormone and IGF Research* 2003 **13** 144–151.
- Burt M & Ho K. Comparison of efficacy and tolerability of somatostatin analogues and other therapies for acromegaly. *Endocrine* 2003 **20** 299–306.
- Colao A, Pivonello R, Auriemma RS, Briganti F, Galdiero M, Tortora E, Caranci F, Cirillo S & Lombardi G. Predictors of tumor shrinkage after primary therapy with somatostatin analogs in acromegaly: a prospective study in 99 patients. *Journal of Clinical Endocrinology and Metabolism* 2006 **91** 2112–2118.
- Colao A, Ferone D, Marzullo P & Lombardi G. Systemic complications of acromegaly: epidemiology, pathogenesis and management. *Endocrine Reviews* 2004 **25** 102–152.
- Murray RD & Melmed S. A critical analysis of clinically available somatostatin analog formulations for therapy of acromegaly. *Journal of Clinical Endocrinology and Metabolism* 2008 **93** 2957–2968.
- Bevan JS. The antitumoral effects of somatostatin analog therapy in acromegaly. *Journal of Clinical Endocrinology and Metabolism* 2005 **90** 1856–1863.
- Verhelst JA, Pedroncelli AM, Abs R, Montini M, Vandeweghe MV, Albani G, Maiter D, Pagani MD, Legros JJ, Gianola D, Bex M, Poppe K, Mockel J & Pagani G. Slow release in the treatment of acromegaly: a study in 66 patients. *European Journal of Endocrinology* 2000 **143** 577–584.
- Ronchi CL, Rizzo E, Lania AG, Pivonello R, Grottoli S, Colao A, Ghigo E, Spada A, Arosio M & Beck-Peccoz P. Preliminary data on biochemical remission of acromegaly after somatostatin analogs discontinuation. *European Journal of Endocrinology* 2008 **158** 19–25.
- Attanasio R, Baldelli R, Pivonello R, Grottoli S, Bocca L, Gasco V, Giusti M, Tamburrano G, Colao A & Cozzi R. Lanreotide 60 mg, a new long-acting formulation: effectiveness in the chronic treatment of acromegaly. *Journal of Clinical Endocrinology and Metabolism* 2003 **88** 5258–5265.
- Ben-Shlomo A & Melmed S. Somatostatin agonists for treatment of acromegaly. *Molecular and Cellular Endocrinology* 2008 **14** 192–198.
- Lucas T, Astorga R & Catala M. Preoperative lanreotide treatment for GH-secreting adenomas: effect on tumor volume and predictive factors of significant tumor shrinkage. *Clinical Endocrinology* 2003 **58** 471–481.
- Cannavo S, Squadrito S, Curto L, Almoto B, Vieni A & Trimarchi F. Results of a two-year treatment with slow release lanreotide in acromegaly. *Hormone and Metabolic Research* 2000 **32** 224–229.
- Colao A, Martino E, Cappabianca P, Cozzi P, Scanarini M, Ghigo E & ALICE Study Group. First-line therapy of acromegaly: a statement of the A.L.I.C.E. (Acromegaly primary medical treatment Learning and Improvement with Continuous Medical Education) Study Group. *Journal of Endocrinological Investigation* 2006 **30** 1017–1020.
- Colao A, Ferone D, Cappabianca P, Del Basso De Caro ML, Marzullo P, Monticelli A, Alfieri A, Merola B, Cali A, De Divitiis E & Lombardi G. Effect of octreotide pretreatment on surgical outcome in acromegaly. *Journal of Clinical Endocrinology and Metabolism* 1997 **82** 3308–3314.
- Colao A, Marzullo P, Ferone D, Marinò V, Pivonello R, Di Somma C, Di Sarno A, Giaccio A & Lombardi G. Effectiveness and tolerability of slow-release lanreotide treatment in active acromegaly. *Journal of Endocrinological Investigation* 1999 **22** 40–47.
- van Thiel SW, Romijn JA, Biermasz NR, Ballieux BEPM, Frolich M, Smit JWA, Corssmit EPM, Roelfsema F & Pereira AM. Octreotide long-acting repeatable and lanreotide Autogel are equally effective in controlling growth hormone secretion in acromegalic patients. *European Journal of Endocrinology* 2004 **150** 489–495.
- Amato G, Mazziotti G, Rotondi M, Iorio S, Doga M, Sorvillo F, Manganello G, Di Salle F, Giustina A & Carella C. Long-term effects of lanreotide SR and octreotide LAR on tumour shrinkage and GH hypersecretion in patients with previously untreated acromegaly. *Clinical Endocrinology* 2002 **56** 65–71.
- Auriemma RS, Pivonello R, Galdiero M, De Martino MC, De Leo M, Vitale G, Lombardi G & Colao A. Octreotide-LAR vs lanreotide as first-line therapy in acromegaly: a retrospective, comparative head-to-head study. *Journal of Endocrinological Investigation* 2008 **31** 956–965.
- Colao A, Auriemma RS, Reborja A, Galdiero M, Resmini E, Minuto F, Lombardi G, Pivonello R & Ferone D. Significant tumor shrinkage after 12 months of lanreotide Autogel treatment given first-line in acromegaly. *Clinical Endocrinology* 2009 **71** 237–245.
- Melmed S, Sternberg R, Cook D, Klibanski A, Chanson P, Bonert V, Vance ML, Rhew D, Kleimberg D & Barkan A. A critical analysis of pituitary tumor shrinkage during primary medical therapy in acromegaly. *Journal of Clinical Endocrinology and Metabolism* 2005 **90** 4405–4410.

- 23 Colao A, Pivonello R, Auriemma RS, Briganti F, Galdiero M, Tortora F, Caranci F, Cirillo S & Lombardi G. Predictors of tumor shrinkage after primary therapy with somatostatin analogues in acromegaly: a prospective study in 99 patients. *Journal of Clinical Endocrinology and Metabolism* 2006 **91** 2112–2118.
- 24 Maiza JC, Vezzosi D, Matta M, Donadille F, Loubes-Lacroix F, Cournot M, Bennet A & Caron P. Long-term (up to 18 years) effects on GH/IGF-I hypersecretion and tumor size of primary somatostatin analogue (SSTa) therapy in patients with GH-secreting pituitary adenoma responsive to SSTa. *Clinical Endocrinology* 2007 **67** 282–289.
- 25 Cozzi R, Montini M, Attanasio R, Albizzi M, Lasio G, Lodrini S, Doneda P, Cortesi L & Pagani G. Primary treatment of acromegaly with octreotide LAR: a long-term (up to nine years) prospective study of its efficacy in the control of disease activity and tumor shrinkage. *Journal of Clinical Endocrinology and Metabolism* 2006 **91** 1397–1403.
- 26 Attanasio R, Lanzi R, Losa M, Valentini F, Grimaldi F, De Menis E, Davi MV, Battista C, Castello R, Cremonini N, Razzore P, Rosato F, Montini M & Cozzi R. Effects of lanreotide Autogel on growth hormone, insulinlike growth factor 1, and tumor size in acromegaly: a 1-year prospective multicenter study. *Endocrinological Practice* 2008 **14** 846–855.
- 27 Dasgupta P. Somatostatin analogue: multiple roles in cellular proliferation, neoplasia and angiogenesis. *Pharmacology and Therapeutics* 2004 **102** 61–85.
- 28 Resmini E, Murialdo G, Giusti M, Boschetti M, Minuto F & Feroni D. Pituitary tumor disappearance in a patient with newly diagnosed acromegaly primarily treated with octreotide LAR. *Journal of Endocrinological Investigation* 2005 **28** 166–169.
- 29 Livadas A, Hadjidakis DJ, Argyropoulou MI, Stamatielatu M, Kelekis D & Raptis SA. Disappearance of a growth hormone secreting macroadenoma during long-term somatostatin analogue administration and recurrence following somatostatin withdrawal. *Hormones* 2006 **5** 57–63.
- 30 Avramidis A, Polyzos SA, Efsthadiou Z & Kita M. Sustained clinical inactivity and stabilization of GH/IGF-I levels in an acromegalic patient after discontinuation of somatostatin analogue treatment. *Endocrine Journal* 2008 **55** 351–357.
- 31 Melmed S, Casanueva F, Cavagnini F, Chanson P, Frohman LA, Gaillard R, Ghigo E, Ho K, Jaquet P, Kleimberg D, Lamberts S, Laws E, Lombardi G, Sheppard MC, Thorner M, Vance ML, Wass JAH & Giustina A. Consensus statement: medical management of acromegaly. *European Journal of Endocrinology* 2005 **153** 737–740.
- 32 Cannavo S, Squadrito S, Curto L, Almoto B & Trimarchi F. Effectiveness of slow-release lanreotide in previously operated and untreated patients with GH-secreting pituitary macroadenoma. *Hormone and Metabolic Research* 2001 **33** 618–624.
- 33 Colao A, Pivonello R, Auriemma RS, Galdiero M, Savastano S & Lombardi G. Beneficial effects of dose escalation of octreotide-LAR as first-line therapy in patients with acromegaly. *European Journal of Endocrinology* 2007 **157** 579–587.
- 34 Mazziotti G & Giustina A. Effects of lanreotide SR and Autogel on tumor mass in patients with acromegaly: a systematic review. *Pituitary* 2010 **13** 60–67.
- 35 Hubina A, Nanzer AM, Hanson HR, Ciccarelli E, Losa M, Gaia D, Papotti M, Terreni MR, Khalaf S, Jordan S, Czirjak S, Hanzel YZ, Nagy GM, Göth MI, Grossman AB & Korbonnits M. Somatostatin analogues stimulate p27 expression and inhibit the MAP kinase pathway in pituitary tumors. *European Journal of Endocrinology* 2006 **155** 371–379.
- 36 Ezzat S, Kontogeorgos G, Redelmeier DA, Horvath E, Harris AG & Kovacs K. *In vivo* responsiveness of morphological variants of growth hormone-producing pituitary adenomas to octreotide. *European Journal of Endocrinology* 1995 **133** 686–690.
- 37 Taboada GF, Luque RM, Vieira Neto L, de O Machado E, Scaffi CB, Domingues RC, Marcondes JB, Chimelli LMC, Fontes R, Niemeyer P, de Carvalho DP, Kineman RD & Gadelha MR. Quantitative analysis of somatostatin receptor subtypes (1–5) gene expression levels in somatotropinomas and correlation to *in vivo* hormonal and tumor volume responses to treatment with octreotide LAR. *European Journal of Endocrinology* 2008 **158** 295–303.
- 38 Pawlikowski M, Pisarek H, Kunert-Radek J & Radek M. Somatostatin receptors in GH-secreting pituitary adenomas- their relationship to the response to octreotide. *Polish Journal of Endocrinology* 2008 **59** 196–199.

Received 8 February 2010
Accepted 12 February 2010