

# Transcatheter pulmonary valve implantation in native pulmonary outflow tract using the Edwards SAPIEN™ transcatheter heart valve

Paolo Guccione<sup>a,\*</sup>, Ornella Milanese<sup>b</sup>, Ziyad M. Hijazi<sup>c</sup> and Giacomo Pongiglione<sup>a</sup>

<sup>a</sup> Department of Pediatric Cardiology and Cardiac Surgery, Bambino Gesù Children's Hospital, Roma, Italy

<sup>b</sup> Department of Pediatric and Congenital Cardiac Surgery, University of Padua, Padua, Italy

<sup>c</sup> Rush Center for Congenital & Structural Heart Disease, Rush University Medical Center, Chicago, USA

\* Corresponding author. Department of Pediatric Cardiology and Cardiac Surgery, Bambino Gesù Children's Hospital, 00165 Roma, Italy. Tel: +39-668592407; fax: +39-65921661; e-mail: paolo.guccione@opbg.net (P. Guccione).

Received 20 June 2011; received in revised form 2 September 2011; accepted 7 September 2011

## Abstract

Percutaneous pulmonary valve implantation (PPVI) is now an accepted alternative option to conventional surgery for patients with dysfunctional conduits between the right ventricle and pulmonary artery. PPVI will reduce the total number of repeat operations in such patients.

However, surgery remains the primary option in postoperative tetralogy of Fallot patients with severe pulmonary regurgitation who underwent transannular patch reconstruction of their right ventricular outflow tract (RVOT). Traditionally, an RVOT patch is considered a relative contraindication to PPVI, however, in selected patients PPVI was successfully performed.

We report the case of a 12-year-old patient after neonatal repair of tetralogy of Fallot and pulmonary atresia, who developed advanced liver disease and severe pulmonary regurgitation. In this patient, the risk for surgical valve replacement was considered too high and he was treated with percutaneous implantation of the Edwards SAPIEN™ transcatheter heart valve.

**Keywords:** Tetralogy of Fallot • Pulmonary regurgitation • Transcatheter pulmonary valve

## CASE REPORT

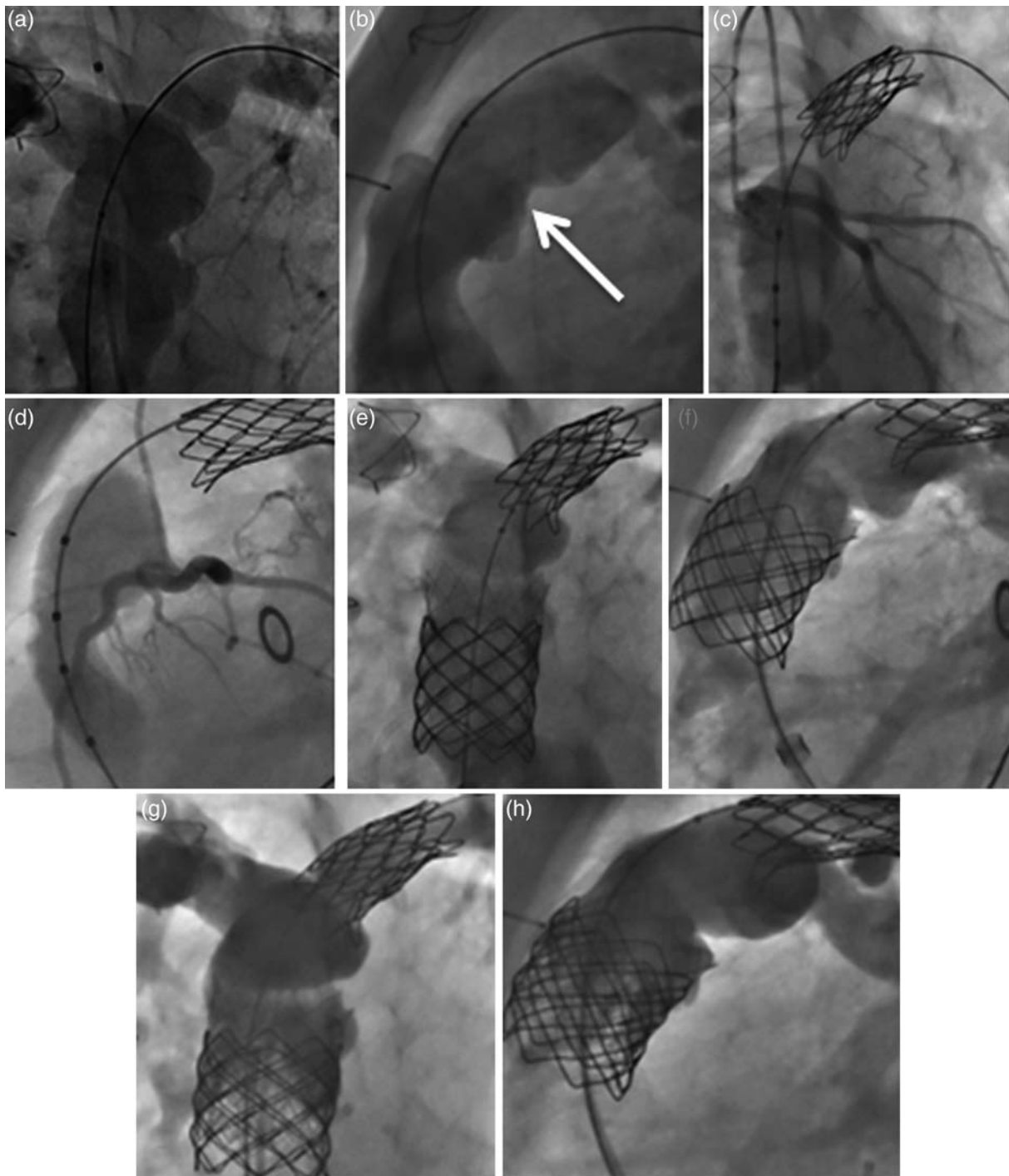
This is the case of a 12-year-old boy with tetralogy of Fallot, pulmonary atresia, who underwent at age 33 days primary surgical repair (transannular patch with a monocuspid valve). At 8 years of age, he was diagnosed with portal cavernoma with portal hypertension and oesophageal varices and progressive hepatic insufficiency. The liver biopsy showed diffuse hepatic fibrosis. Considering liver transplant, a cardiac catheterization was performed at age 11 years that showed mild residual obstruction of the pulmonary arteries, severe pulmonary regurgitation and dilated right atrium and ventricle with mean right atrial and ventricular end-diastolic pressures of 15 and 13 mmHg, respectively. The minimum diameter of the right ventricle outflow tract (RVOT) was 23 mm (Fig. 1a and b).

At age 12, he was taken to the cardiac catheterization laboratory for an attempt at percutaneous pulmonary valve implantation (PPVI). The procedure was performed under general endotracheal anaesthesia. A moderate narrowing of the left pulmonary artery was treated with implantation of a 28 mm CP stent (NuMED Inc., Hopkinton, NY) mounted on a 12 mm ZMED balloon (NuMED Inc., Hopkinton, NY) with very good result. Sizing of the RVOT was performed using the 30 mm NuMED sizing balloon. The proximity of the left coronary artery to the RVOT was assessed during balloon inflation in the RVOT with simultaneous left coronary angiography (Fig. 1c and d). The distance between the RVOT and the origin of the left coronary

was at least 10 mm and it was felt safe enough to implant a stent in the RVOT. The minimum RVOT diameter measured 23 mm, which was suitable for the Edwards SAPIEN™ transcatheter heart valve. The RVOT was pre-stented with a 45 mm CP stent (NuMED Inc., Hopkinton, NY) mounted over a 24 mm BiB balloon (NuMED). However, due to significant foreshortening, an additional 50-mm long Palmaz XL stent (P5014) (Cordis, a Johnson & Johnson Company, Interventional Systems, Warren, NJ, USA) was implanted over a 24 mm BiB balloon with overlapping between the two stents. Of note, we did not have an additional CP stent to implant, hence the use of Palmaz stent.

The stents were positioned in a way to create a conduit from the RV to the bifurcation of the pulmonary arteries with an inner diameter between 24 and 25 mm (Fig. 1e and f). Subsequently, a 26-mm Edwards valve was implanted in the middle of the two implanted stents. An angiography performed after PPVI revealed good valve function with trivial pulmonary insufficiency (Fig. 1g and h). The final mean right atrial pressure was 13 mmHg, right ventricle (RV) pressure was 28/0–12 mmHg and a trivial gradient at the take-off of the left pulmonary artery was present. The diastolic pressure of the pulmonary arteries increased from 2 to 7 mmHg after valve implantation. The fluoroscopy time was 42 min. No complications were encountered during or after the procedure. Haemostasis in the right femoral vein was achieved using the figure of 8 technique.

The patient was discharged home in good clinical condition 2 days after the procedure.



**Figure 1:** Implantation of the Edwards SAPIEN™ transcatheter heart valve into a surgically reconstructed RVOT. (a and b) pulmonary angiogram in frontal and lateral planes. The reconstructed RVOT shows (arrow) irregular shape with a minimum diameter of 23 mm. (c and d) Inflation of the NuMED sizing balloon in the RVOT with simultaneous left coronary angiogram, this reveals filling of the coronary arteries without any obstruction. (e and f) Pulmonary angiogram in frontal and lateral planes after pre-stenting of the RVOT. Note the creation of an artificial conduit between the RV and the pulmonary arteries. (g and h) Pulmonary angiogram in frontal and lateral planes after implantation of the 26 mm Edwards SAPIEN™ transcatheter heart valve showing trivalvular insufficiency without stenosis. The valved stent is fully expanded.

Cardiac catheterization performed 2-months after PPVI showed trivalvular pulmonary regurgitation and mean right atrial and ventricular end-diastolic pressures of 8 and 7 mmHg, respectively.

Three-months later, he underwent successful liver transplant without any haemodynamic sequelae.

At 9 months of follow-up, the patient's exercise tolerance had improved considerably, at echocardiographic evaluation, the right ventricle function significantly improved and the implanted pulmonary valve was well functioning without a systolic gradient and a trivalvular pulmonary regurgitation.

## DISCUSSION

The case reported confirms that PPVI in the native patch constructed RVOT is feasible [1–3]. The anatomy and dimensions of the reconstructed RVOT must be suitable for pre-stenting at a maximum diameter of 24 mm allowing a safe positioning of the 26 mm Edwards SAPIEN™ transcatheter heart valve. Pre-stenting of the RVOT is the most crucial step of the procedure since it creates an artificial conduit allowing safe positioning of the valve stent and may prevent or reduce the chance of stent/valve fracture or migration [1–3]. Further, since the Edwards valve height is only 14–16 mm, pre-stenting allows safe positioning of this valve without worrying much about the exact position or any area of residual narrowing. Once the potential of coronary compression has been accurately ruled out, stent migration appears to be the major potential complication of the procedure, considering that the compliance of the RVOT is non-predictable, as compared to that of conduits. In case of stent instability, over dilatation of the stent at a diameter larger than 25 mm might achieve a stable position of the stent, however, it does not allow subsequent implantation of the currently available valves (the largest Sapien valve being 26 mm). However, in the future, the 29 mm Edwards valve that is currently available for transapical aortic valve

implantation may increase the pool of patients with native RVOT who may benefit from this technology.

This report adds to the experience of the Edwards valve in the pulmonic position, which remains limited [3–5].

**Conflict of interest:** none declared.

## REFERENCES

- [1] Lurz P, Coats L, Khambadkone S, Nordmeyer J, Boudjemline Y, Schievano S *et al.* Percutaneous pulmonary valve implantation: impact of evolving technology and learning curve on clinical outcome. *Circulation* 2008;117: 1964e72.
- [2] Khambadkone S, Nordmeyer J, Bonhoeffer P. Percutaneous implantation of the pulmonary and aortic valves: indications and limitations. *J Cardiovasc Med* 2007;8:57–61.
- [3] Boone RH, Webb JG, Horlick E, Benson L, Cao Q, Nadeem N *et al.* Transcatheter pulmonary valve implantation using the Edwards SAPIEN™ transcatheter heart valve. *Cathet Cardiovasc Interv* 2010;75:286–94.
- [4] Bertels RA, Blom NA, Schalij MJ. Edwards SAPIEN transcatheter heart valve in native pulmonary valve position. *Heart* 2010;96:661.
- [5] Ewert P, Horlick E, Berger F. First implantation of the CE-marked transcatheter Sapien pulmonic valve in Europe. *Clin Res Cardiol* 2011;100: 85–7.