

Non-ischemic scar underlines ventricular arrhythmias in Kearns-Sayre syndrome

Stefano Figliozzi, Alessandro Zorzi, Martina Perazzolo Marra, Alessandro Ruocco, Sabino Iliceto, Domenico Corrado, Chiara Calore

Department of Cardiac, Thoracic, Vascular and Public Health Sciences, University of Padova, Italy

Abstract

Kearns-Sayre syndrome (KSS) is a rare mitochondrial disease in which cardiac involvement has been associated with poor prognosis. Although the most common clinical manifestation is progressive conduction system impairment, patients can suffer from ventricular arrhythmias. Yet, they show a high prevalence of sudden cardiac death, whose etiopathological mechanism is not completely understood. Cardiac magnetic resonance is a rising tool to detect subclinical heart involvement in many heart diseases and was recently able to detect non-ischemic scar, which is an arrhythmogenic substrate, in patients affected by KSS.

Introduction

Kearns-Sayre syndrome (KSS) is a mitochondrial disease characterized by onset before the age of 20 years, progressive external ophthalmoplegia, pigmentary retinopathy, elevated cerebrospinal fluid protein and cerebellar ataxia.¹ Cardiac involvement is more frequent in KSS than in other mitochondrial disorders, often in the form of progressive conduction system disease leading to bundle branch block and infra-Hissian atrioventricular block because the specialized cardiac conduction system cells are particularly rich of mitochondria. Furthermore, patients with KSS show a high risk of sudden cardiac death (SCD), which is traditionally ascribed to atrioventricular block or torsades-de-pointes in the context of bradycardia-related QT-prolongation. On the other hand, ventricular arrhythmias (VAs) can also be observed, although their etiopathological mechanism and clinical relevance remain to be elucidated.² We present the case of a patient affected by KSS with a long-standing history of VAs despite the absence of electrocardiogram (ECG) and electrocardiographic signs of cardiac involvement.

Case Report

A 44-year old male with KSS was referred to our cardiology clinic four years before for palpitations. Serial 24-h ECG demonstrated frequent ventricular ectopic beats (VEBs) and non-sustained ventricular tachycardia that persisted despite beta-blockers therapy. There was no family history of cardiac disease and his medications were carvedilol, ramipril and coenzyme Q-10. Baseline electrocardiogram (ECG) (Figure 1, panel A) and transthoracic echocardiography were normal. A 12-lead 24-h ambulatory ECG monitoring recorded 2175 isolated VEBs, 35 couplets and a run of nonsustained ventricular tachycardia of 5 beats with a right bundle branch block/superior axis pattern of the ectopic QRS, suggesting left ventricular free-wall origin (Figure 1, panel B). Frequent atrial ectopic beats (1981 in 24 h) were also present, while there was no evidence of atrioventricular block. Contrast-enhanced cardiac magnetic resonance (CMR) revealed mid-wall late gadolinium enhancement (LGE) in the basal-mid anterolateral and inferolateral segments, consistent with a left ventricular non-ischemic scar (Figure 1, panels C and D) in the absence of morphofunctional abnormalities, myocardial edema or fatty infiltration. The regional distribution of the myocardial scar was consistent with the plausible site of origin of VEBs.

Discussion

Scar tissue is a well-known substrate for VEBs (which origin from surviving myocytes interspersed among fibrous tissue or the scar border-zone) and re-entrant sustained ventricular tachycardia in patients with cardiomyopathies.³ More recently, isolated left-ventricular myocardial scar with a non-ischemic distribution has been recognized as a substrate of apparently unexplained VAs in patients with otherwise structurally normal heart.⁴ Although these lesions are traditionally considered the sign of a healed myocarditis, left ventricular scar with a subepicardial/midmural (*i.e.* non-ischemic) distribution can be secondary to genetically-determined cardiac damage such as in case of desmoplakin, phospholamban or filamin-C gene-mutation.⁵ All those conditions are characterized by a high risk of SCD for ventricular tachyarrhythmias unrelated to the degree of ventricular systolic dysfunction.

A recent CMR study detected pathological findings in 10 out of 35 patients affected by KSS, despite normal ECG and nega-

Correspondence: Alessandro Zorzi, Department of Cardiac, Thoracic, Vascular and Public Health Sciences, University of Padova, via Giustiniani 2, 35100, Padova, Italy.
Tel.: +39.0498.212321.
E-mail: alessandrozorzi@gmail.com

Key words: Mitochondrial cardiomyopathy; Kearns-Sayre syndrome; ventricular arrhythmias; imaging; cardiac magnetic resonance; non-ischemic scar.

Received for publication: 28 March 2019.
Accepted for publication: 12 July 2019.

This work is licensed under a Creative Commons Attribution NonCommercial 4.0 License (CC BY-NC 4.0).

©Copyright: the Author(s), 2019
Licensee PAGEPress, Italy
Cardiogenetics 2019; 9:8194
doi:10.4081/cardiogenetics.2019.8194

tive biomarkers.⁶ Similar to our case, in 8 out of these 10 patients, myocardial involvement consisted of a mid-wall area of LGE in the basal-mid lateral segments. Interestingly, this LGE pattern was not found in other mitochondrial disorders with heart involvement. KSS is distinctively characterized by a high risk of SCD: although atrioventricular block due to progressive conduction system disease is traditionally believed to be the cause, a number of patients died suddenly despite pacemaker implantation.⁷ In these cases, myocardial scar-related VAs may be a potential mechanism. According to this perspective, CMR should be strongly considered for detection of cardiac involvement in KSS patients, particularly in those with ventricular arrhythmias, as it may help to identify concealed arrhythmogenic substrates.

Conclusions

Although the most common clinical manifestation of KSS is progressive conduction system impairment, patients can also suffer from VAs. Myocardial scar is an arrhythmic substrate that is frequently demonstrated by CMR in the absence of echocardiographic or ECG abnormalities. Consequently, CMR may provide an incremental value for cardiac involvement identification and risk stratification of patients with KSS. Prospective cohort studies are needed to evaluate the impact of myocardial scarring on indications to prophylactic ICD implantation even in the absence of myocar-

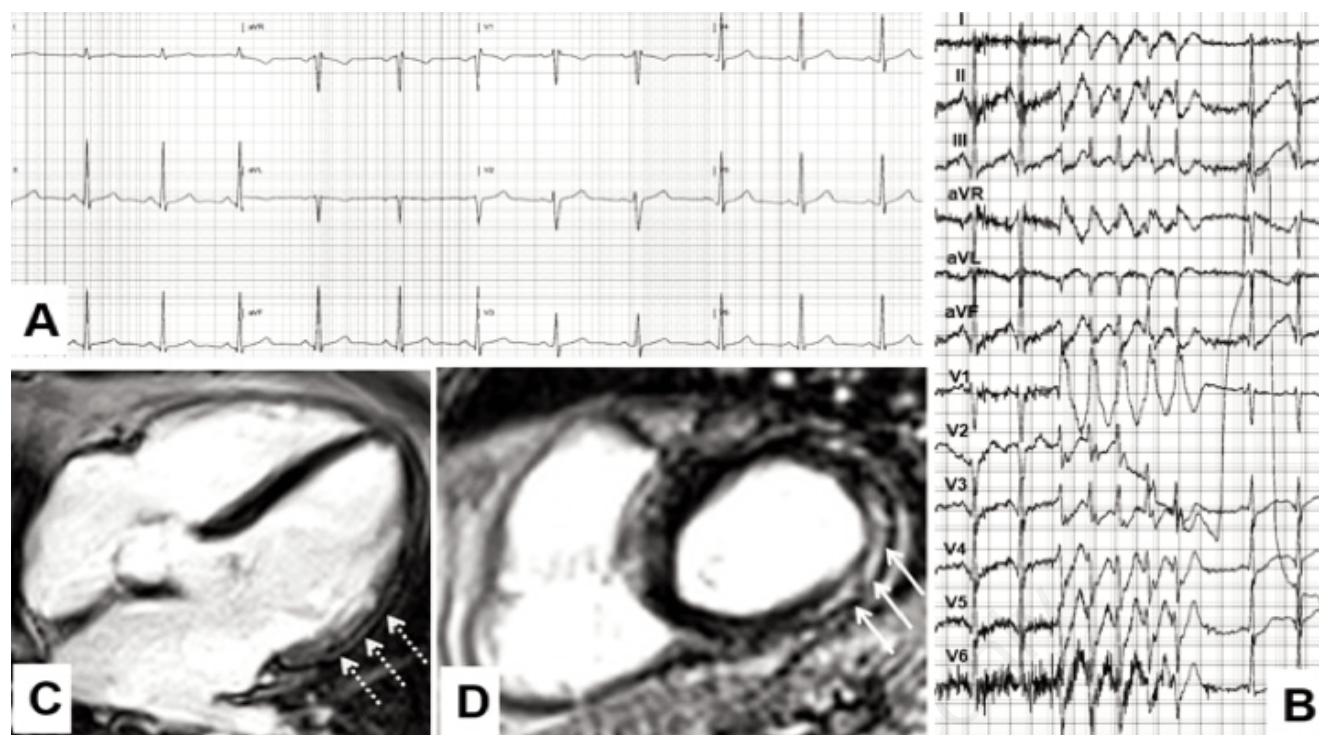


Figure 1. Baseline electrocardiogram is normal (A). Nonsustained ventricular tachycardia recorded at 24-h ambulatory electrocardiogram monitoring. A right bundle branch block/superior axis pattern of the ectopic QRS is evident (B). Contrast-enhanced cardiac magnetic resonance reveals mid-wall late gadolinium enhancement of the left ventricle, consistent with non-ischemic scar. Long axis (C) and basal short-axis (D) views show the involvement of the basal-mid segments of the anterolateral and inferolateral myocardial wall (arrows).

dial dysfunction or intraventricular conduction defects.

References

1. Thorburn DR, Dahl HH. Mitochondrial disorders: genetics, counseling, prenatal diagnosis and reproductive options. *Am J Med Genet* 2001;106:102-14.
2. Kabunga P, Lau AK, Phan K, et al. Systematic review of cardiac electrical disease in Kearns-Sayre syndrome and mitochondrial cytopathy. *Int J Cardiol* 2015;181:303-10.
3. Nguyen MN, Kiriazis H, Gao XM, Du XJ. Cardiac fibrosis and arrhythmogenesis. *Compr Physiol* 2017;7:1009-49.
4. Zorzi A, Perazzolo Marra M, et al. Nonischemic left ventricular scar as a substrate of life-threatening ventricular arrhythmias and sudden cardiac death in competitive athletes. *Circ Arrhythm Electrophysiol* 2016;9.
5. Corrado D, Zorzi A, Filamin C. A new arrhythmogenic cardiomyopathy-causing gene? *JACC Clin Electrophysiol* 2018;4:515-7.
6. Florian A, Ludwig A, Stubbe-Dräger B, et al. Characteristic cardiac phenotypes are detected by cardiovascular magnetic resonance in patients with different clinical phenotypes and genotypes of mitochondrial myopathy. *J Cardiovasc Magn Reson* 2015;17:40.
7. Imamura T, Sumitomo N, Muraji S, et al. The necessity of implantable cardioverter defibrillators in patients with Kearns-Sayre syndrome - systematic review of the articles. *Int J Cardiol* 2019;279:105-11.