

Effect of Bovine Dried Amniotic Membranes as Prosthesis of Abdominal Fascial Defect Closure Reviewed from The Level of Density Collagen Type I and III in *Rattus novergicus* Wistar Strain

by Marjono Dwi Wibowo

Submission date: 13-Sep-2023 08:18PM (UTC+0800)

Submission ID: 2164968439

File name: bdominal-fascial-defect-closure-reviewed-from-the-level-of-d.pdf (320.53K)

Word count: 2956

Character count: 15265

Effect of Bovine Dried Amniotic Membranes as Prosthesis of Abdominal Fascial Defect Closure Reviewed from The Level of Density Collagen Type I and III in *Rattus novergicus* Wistar Strain

Ahmad Jazlanardi Primaditya Wardhana, Fendy Matulatan*, Marjono Dwi Wibowo, Edwin Danardono

2

Department of Surgery, Faculty of Medicine-Dr. Soetomo Teaching Hospital, Universitas Airlangga, Surabaya 60131, Indonesia

ABSTRACT

Collagen types I and III is an important component of abdominal fascia and aponeurosis. Dried amniotic membrane is rich in the extracellular matrix, dominated by types I and III collagen, which has the potential to improve the wound healing process. This study aimed to analyze the differences in density of types I and III collagen in abdominal fascia defects closed with and without bovine dried amniotic membranes. This was an experimental research design using *Rattus novergicus* divided into two groups. The first group was directly covered with a skin flap closure, while the second group used bovine dried amniotic membrane. Evaluation of type I and III collagen density was assessed using an immunohistochemical examination and a collagen density score, the Pathological Visual Score. In the evaluation of type I collagen density the score in the control group was 1 (68.8%), 0 (25%), and 3 (6.3%). Whereas in the treatment group was a score of 2 (50%), a score of 1 (43.8%), and a score of 0 (6.3%). The density of type III collagen showed that the scores in the control group were a score of 1 (50%), a score of 0 (31.3%), and a score of 2 (18.8%). Meanwhile, the treatment group obtained a score of 2 (58.8%), a score of 1 (31.3%), and a score of 0 (0%). There was an increase in the density of collagen types I and III in the abdominal fascial defect reconstructed using bovine dried amniotic membrane.

Keywords: abdominal fascial defect, bovine dried amnion membrane, collagen type I density, collagen type III density.

Correspondence:

Fendy Matulatan, MD
Department of Surgery, Faculty of Medicine-Dr. Soetomo Teaching Hospital,
Universitas Airlangga, Surabaya 60131, Indonesia
Tel: +6231-550-1327; Fax: +6231-504-9256
E-mail: fensurg@yahoo.com

INTRODUCTION

The procedure involving the abdominal cavity is an open surgery (1). The fascia is one of the important structures in the anterior abdominal wall. The anterior abdominal wall has been the subject of numerous studies. The myoaponeurotic lining of the anterior abdominal wall plays a functional and aesthetic role. In linea alba, the region where the abdominal wall consists only of aponeurosis without any muscle covering is exposed to full pressure from the intraabdominal area and becomes a potential problem if there is a defect (2).

As an important part of abdominal fascia and aponeurosis, including linea alba, collagen has an important role as a structure providing support and resistance to the abdominal wall against intraabdominal pressure. Type I collagen is the most abundant component, which is a major component of aponeurosis, tendons, and mature scar tissue. It plays a major role in fascial resistance to strain forces. Type III collagen, formerly known as reticular fibers, functions to support structures with the ability to develop. Type III collagen also increases in number during the initial phase of wound healing (3).

Previous studies have shown that patients with abdominal wall hernias have lower levels of collagen types I and III compared to the control group without hernias. The analysis of collagen types I and III gene expression in abdominal wall fascia in obese patients shows that collagen types I and III are lower than in patients without obesity (4).

Based on socio-economic considerations and the clinical impact of wounds, innovative solutions have been developed for many years, especially the use of extraembryonic stem

cell derivatives from the placenta, chorion and amniotic membrane, which have been the subject of numerous studies and tissue engineering. Amniotic membrane has been widely used as a synthetic prosthesis [1]. It has the advantage of having a low antigenicity, antimicrobial, and ability to reduce exudate and adhesion, accelerate epithelialization, reduce local pain, and as a material for tissue growth. The basement membrane portion of the amniotic membrane is rich in an extracellular matrix dominated by collagen types I, III, and fibronectin (5).

The previous study has shown that the use of amniotic membranes in wounds on rat skin can improve wound healing processes and increase the amount of collagen type III in the proliferation phase and collagen type I in the wound maturation phase (6). The use of amniotic membranes in fascial wounds or defects and their benefits in increasing the amount of collagen, especially types I and III, has never been done before. This study aimed to analyze differences in the density of collagen types I and III in abdominal fascia defects covered with and without bovine dried amniotic membrane [2].

METHODS

An experimental study using a randomized control trial design conducted on experimental animals of Wistar strain *Rattus novergicus* aged around 12-16 weeks, with a range of body weight between 250-300 grams. There were two groups, a control group and the treatment group. Observations were made on the 21st day to determine changes in the research variables during the proliferation and maturation phases of the wound. Before being sacrificed, repeated body

Effect of Bovine Dried Amniotic Membranes as Prosthesis of Abdominal Fascial Defect Closure Reviewed from The Level of Density Collagen Type I and III in *Rattus norvegicus* Wistar Strain

measurements were taken for each animal. Experimental rats were adapted for seven days, then randomized by permuted block randomization, and the samples were divided into control groups and treatment groups. After a defect was made in the abdominal fascia, the control group was covered with a skin flap, while the treatment group was added with bovine dried amniotic membrane. After the maturation phase (21 days), an immunohistochemical examination was performed to determine the level of collagen density types I and III using collagen I and III polyclonal antibodies. The assessment of collagen density uses the Pathological Visual Score as follows:

- Score 0: No collagen fibers found in the wound area (0%)
- Score 1: Density of collagen fibers in low wound area (<10%)
- Score 2: Density of collagen fibers in moderate injury area (10-50%)
- Score 3: Density of collagen fibers in tightly wound area (>50%)

RESULTS

The study was conducted on 32 male *Rattus norvegicus* Wistar strain with age between 12-16 weeks with a body weight between 250-300 grams. Sixteen rats were involved in the control group, and 16 more in the treatment group. The basic data of the research sample are illustrated in Table 1. Data on body weight and age of the samples were normally distributed with a P-value >0.05.

Table 1. Characteristics of samples

Characteristics	Groups		p
	Control	Treatment	
Age (weeks)	14.13	13.63	0.236
Weight (grams)	272.50	269.37	0.590

Type I Collagen Density Test

In the type I collagen density score data, in the treatment group, the most score found was score 2 in 8 samples (50%), followed by score 1 in 7 samples (43.8%) and score 0 in 1 sample (6.3%), with an average score of 1.44. Meanwhile, the highest score in the control group was score 1 in 11 samples (68.8%), followed by score 0 in 4 samples (25%) and score 2 in 1 sample (6.3%), with an average score of 0.81. In this study, the difference in type I collagen density score was tested through the type I collagen density score was performed using the Mann-Whitney U test because the type I collagen density score data were ordinal data. Mann-Whitney U test results obtained $p < .05$ (0.006). It can be concluded that differences in type I collagen density in the control group compared with the treatment group were statistically significant.

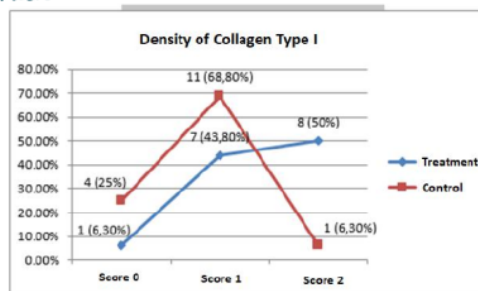
Table 2. Type I collagen density scores

Groups	Score 0	Score 1	Score 2	Mean	p
Treatment	1 (6.3%)	7 (43.8%)	8 (50%)	1.44	0.006
Control	4 (25%)	11 (68.8%)	1 (6.3%)	0.81	

Figure 1. Density of Collagen Type I

Type III Collagen Density Test

In the type III collagen density score data, in the treatment group, the most score was score 2 in 11 samples (68.8%),



followed by score 1 in 5 samples (31.3%) and score 0 in 0 samples (0%), with an average score of 1.69. Meanwhile, the highest score in the control group was score 1 in 8 samples (50%), followed by score 0 in 5 samples (31.3%) and score 2 in 3 samples (18.8%), with an average score of 0.88. In this study, the difference in type III collagen density test illustrated through the type III collagen density score, performed using the Mann-Whitney U test because the type III collagen density score data were ordinal data. Mann-Whitney U test results show $p < .05$ (0.002). It can be concluded that differences in type III collagen density in the control group compared with the treatment group were statistically significant.

Table 3. Type III collagen density scores

Groups	Score 0	Score 1	Score 2	Mean	p
Treatment	0 (0%)	5 (31.3%)	11 (68.8%)	1.69	0.002
Control	5 (31.3%)	8 (50%)	3 (18.8%)	0.88	

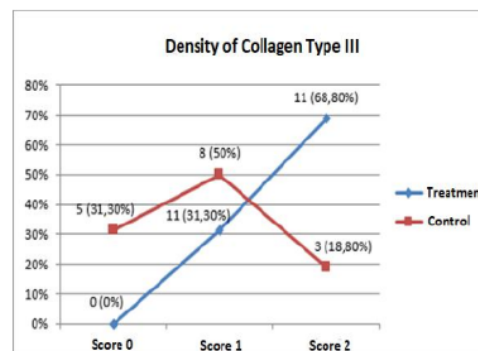


Figure 2. Density of Collagen Type III

DISCUSSION

The results of this study showed a statistically significant increase in density of collagen types I and III in the treatment group compared to the control group. These results indicate that the nutritional status of experimental animals did not influence the final results for both collagen types I and III density scores, in which case there was no significant difference in weight changes before and after treatment. Also, there were no side effects, such as hematoma, hernia, infection and cardiorespiratory disorders in both the control and treatment groups. The whole process of wound healing involves a series of complex events which can take a long time. In normal conditions, the wound can heal by itself,

Effect of Bovine Dried Amniotic Membranes as Prosthesis of Abdominal Fascial Defect Closure Reviewed from The Level of Density Collagen Type I and III in *Rattus norvegicus* Wistar Strain

but how fast it is can be affected by many factors (8). Various methods to improve wound healing have been applied, one of which involves placing the amniotic membrane in the wound (9). This study proves that the use of amniotic membrane as a prosthesis close the abdominal fascial defect can increase the density of collagen types I and III in the fascial defect [3]. The epithelium and stroma of the amniotic membrane are abundant in expression of several growth factors, including TGF- α , epidermal growth factors (EGF), keratinocyte growth factors (KGF), hepatocyte growth factors (HGF), and basic fibroblast growth factors (bFGF) (10). These growth factors are present in granules in concentrated platelet-rich plasma (PRP) (11,12). These growth factors will stimulate an increase in excess extracellular matrix deposits in the maturation phase of wound healing. Fibronectin and collagen type III are the initial matrix formed. Meanwhile, glycosaminoglycans and proteoglycans will be formed in the next matrix. The final matrix formed in the maturation phase is type I collagen, largely replacing the amount of type III collagen formed during the initial matrix formation [4].

Amniotic membrane can accelerate the process of formation of collagen types I and III (13) evidenced from the control group with the highest scores of 0 and 1, compared to the treatment group with the best scores of 1 and 2. These results were obtained from collagen types I and III. It can be concluded that with the amniotic membrane, the scoring process of forming collagen types I and III was quickly passed from score 0 to score 3. The presence of amniotic membrane contact with the wound base is associated with the ability to recover using a fast bovine amnion membrane. The amniotic membrane consists of cube-shaped, enlarged epithelial cells and mesenchymal connective tissue. Epithelial cells migrate along the amniotic membrane and form the edge of the epidermis. Although bovine amniotic membrane epithelial cells are destroyed through various sterilization and storage processes, the connective tissue in them remains present. The connective tissue of the amniotic membrane contains laminin, fibronectin, collagen types I and III, which are the main components of the dermal basal membrane. Thus, the rapid and complete epithelialization process is the result of wound closure with an amniotic membrane (14).

This study generally shows that the application of amniotic membranes can stimulate the process of collagenization. This is evidenced by an increase in the number of collagen types I and III, acting as the main structure of the new extracellular matrix of wound tissue and experiencing a relatively increased amount on the 21st day. However, how its development until then can grow new fascial tissue still needs to be further investigated.

CONCLUSION

The use of bovine dried amniotic membrane can increase the density of both type I and 3 collagen in abdominal fascial defects of *Rattus norvegicus* Wistar strain after reconstruction and is statistically significant. Bovine dried amniotic membrane can be used as a local material applied to improve the extracellular matrix structure of wound tissue in the abdominal fascia of rats.

REFERENCES

1. Wahyuni S, Wahyuni AS, Tarigan R, Syarifah S. Effect of early ambulation to peristaltic activity of abdominal post-operative patients in Medan city

hospital, Indonesia. In: IOP Conference Series: Journal of Physics: Conference Series. Institute of Physics Publishing; 2019.

2. Nahas FX, Barbosa MVJ, Ferreira LM. Factors that may influence failure of the correction of the musculoaponeurotic deformities of the abdomen. Vol. 124, Plastic and reconstructive surgery. United States; 2009. p. 334; author reply 334-5.
3. Fachinelli A, Maciel Trindade MR. Qualitative and quantitative evaluation of total and types I and III collagens in patients with ventral hernias. Langenbeck's Arch Surg. 2007 Jul;392(4):459-64.
4. Szczesny W, Szczepanek J, Tretyn A, Dąbrowiecki S, Szmytkowski J, Polak J. An analysis of the expression of collagen I and III genes in the fascia of obese patients. J Surg Res. 2015 May;195(2):475-80.
5. Mamede AC, Carvalho MJ, Abrantes AM, Laranjo M, Maia CJ, Botelho MF. Amniotic membrane: from structure and functions to clinical applications. Cell Tissue Res. 2012 Aug;349(2):447-58.
6. Campelo MBD, Santos J de AF, Maia Filho ALM, Ferreira DCL, Sant Anna LB, Oliveira RA de, et al. Effects of the application of the amniotic membrane in the healing process of skin wounds in rats. Vol. 33, Acta Cirurgica Brasileira. scielo; 2018. p. 144-55.
7. Hanafiah OA, Abidin T, Ilyas S, Nainggolan M, Syamsudin E. Wound healing activity of binahong (*Anredera cordifolia* (Ten.) Steenis) leaves extract towards NIH-3T3 fibroblast cells. J Int Dent Med Res. 2019;12(3):854-8.
8. Laila L, Febriyenti F, Salhimi SM, Baie S. Wound healing effect of Haruan (*Channa striatus*) spray. Int Wound J. 2011;8(5):484-91.
9. Rizal M, Munadzirah E, Kriswandini IL. The increase of VEGF expressions and new blood vessels formation in Wistar rats induced with post-tooth extraction sponge amnion. Dent J (Majalah Kedokt Gigi). 2018;51(1):1-4.
10. Wang M, Yoshida A, Kawashima H, Ishizaki M, Takahashi H, Hori J. Immunogenicity and antigenicity of allogeneic amniotic epithelial transplants grafted to the cornea, conjunctiva, and anterior chamber. Invest Ophthalmol Vis Sci. 2006 Apr;47(4):1522-32.
11. Rieuwpassa IE, Tanca M, Oktawati S, Djais AI, Cangara MH, Achmad H. Comparison of fibroblast amount on the gingival healing process in the wound applied by platelet-rich plasma (Prp) and chlorhexidine (chx). Indian J Public Heal Res Dev. 2019;10(5):604-9.
12. Oley MC, Islam AA, Hatta M, Hardjo M, Nirmalasari L, Rendy L, et al. Effects of platelet-rich plasma and carbonated hydroxyapatite combination on cranial defect Bone Regeneration: An animal study. Wound Med. 2018;21:12-5.
13. Retha R, Sawitri S, Rahmadewi R, Hidayati AN, Listiawan MY, Ervianti E, et al. Combination of Amniotic Membrane Stem Cell Metabolite Product (AMSC-MP) and Vitamin E for Photoaging. Berk Ilmu Kesehatan Kulit dan Kelamin. 2020;32(1):1-6.
14. Farhadhosseinabadi B, Farahani M, Tayebi T, Jafari A, Biniazan F, Modaresifar K, et al. Amniotic membrane and its epithelial and mesenchymal stem cells as an appropriate source for skin tissue engineering and regenerative medicine. Artif Cells, Nanomedicine, Biotechnol [Internet]. 2018 Nov 5;46(sup2):431-40. Available from:

Effect of Bovine Dried Amniotic Membranes as Prosthesis of Abdominal Fascial Defect Closure Reviewed from The Level of Density Collagen Type I and III in Rattus norvegicus Wistar Strain

<https://doi.org/10.1080/21691401.2018.1458730>

15. Emilio Salgado, M., " *SOMEONE COULD BE SICK*": *COGNITIVE BEHAVIOUR THERAPY FOR A SPECIFIC PHOBIA OF VOMITING (EMETOPHOBIA): A STUDY CASE*. REVISTA ARGENTINA DE CLINICA PSICOLOGICA, 2019. **28**(4): p. 325-338.
16. Cimadevilla, R., C. Jenaro, and N. Flores, *IMPACT ON PSYCHOLOGICAL HEALTH OF INTERNET AND MOBILE PHONE ABUSE IN A SPANISH SAMPLE OF SECONDARY STUDENTS*. REVISTA ARGENTINA DE CLINICA PSICOLOGICA, 2019. **28**(4): p. 339-347.
17. Antonio Santana-Campas, M., C. Alejandro Hidalgo-Rasmussen, and M. Angel Alcazar-Corcoles, *IMPULSIVITY AND HOPELESSNESS AS RISK FACTORS FOR SUICIDE IN DEPRIVED YOUNG MEXICANS*. REVISTA ARGENTINA DE CLINICA PSICOLOGICA, 2019. **28**(4): p. 544-553.
18. Fernandez-Martin, L.C., et al., *APPLICATION OF A CASE STUDY COGNITIVE-BEHAVIORAL PROTOCOL FOR THE MANAGEMENT OF CHRONIC PAIN*. REVISTA ARGENTINA DE CLINICA PSICOLOGICA, 2019. **28**(4): p. 356-362.

Effect of Bovine Dried Amniotic Membranes as Prosthesis of Abdominal Fascial Defect Closure Reviewed from The Level of Density Collagen Type I and III in Rattus novergicus Wistar Strain

ORIGINALITY REPORT

15%

SIMILARITY INDEX

6%

INTERNET SOURCES

10%

PUBLICATIONS

0%

STUDENT PAPERS

PRIMARY SOURCES

- 1** Aldo Fachinelli, Manoel Roberto Maciel Trindade. "Qualitative and quantitative evaluation of total and types I and III collagens in patients with ventral hernias", *Langenbeck's Archives of Surgery*, 2006
Publication 1%
- 2** Hasan Maulahela, Dalla Doohan, Yudith Annisa Ayu Rezkhita, Ari Fahrial Syam et al. "Helicobacter pylori prevalence in Indonesia: Higher infection risk in Eastern region population", *F1000Research*, 2022
Publication 1%
- 3** trepo.tuni.fi
Internet Source 1%
- 4** *Amniotic Membrane*, 2015.
Publication 1%
- 5** Lekshmi Krishna, Kamesh Dhamodaran, Murali Subramani, Murugeswari Ponnulagu et 1%

al. "Protective Role of Decellularized Human Amniotic Membrane from Oxidative Stress-Induced Damage on Retinal Pigment Epithelial Cells", ACS Biomaterials Science & Engineering, 2018

Publication

6

Zainab Zuhair Ali, Fatimah J. Al-Hasani. "Evaluation of Surface Roughness of Some Biomedical Titanium Alloys by Pack Cementation Coating", Key Engineering Materials, 2021

Publication

1 %

7

www.karger.com

Internet Source

1 %

8

Federico Vozi, Ilenia Guerrazzi, Jonica Campolo, Lorena Cozzi et al. "Biological and proteomic characterization of a composite mesh for abdominal wall hernia treatment: Reference Study", Journal of Biomedical Materials Research Part B: Applied Biomaterials, 2017

Publication

1 %

9

publications.inschool.id

Internet Source

1 %

10

Fitri Nuroini, Kanti Ratnaningrum, Mochamad Restinu Alya Soejoto, Sri Sinto Dewi, Gela Setya Ayu Putri. "Binahong leaf extract activity in the 8th day of wound healing

infected with Staphylococcus aureus towards collagen tissue", Jurnal Teknologi Laboratorium, 2021

Publication

11

Lia Laila. "Wound healing effect of Haruan (Channa striatus) spray", International Wound Journal, 10/2011

Publication

1 %

12

www.researchgate.net

Internet Source

1 %

13

Eliziane Nitz de Carvalho Calvi, Fábio Xerfan Nahas, Marcus Vinícius Barbosa, José Augusto Calil, Silvia Saiuli Miki Ihara, Marcelo de Souza Silva, Marcello Fabiano de Franco, Lydia Masako Ferreira. "An experimental model for the study of collagen fibers in skeletal muscle", Acta Cirurgica Brasileira, 2012

Publication

1 %

14

L. Zogbi, E. N. Trindade, M. R. M. Trindade. "Comparative study of shrinkage, inflammatory response and fibroplasia in heavyweight and lightweight meshes", Hernia, 2013

Publication

1 %

15

Viviane L. Busnardo, Maria L. P. Biondo-Simões. "Os efeitos do laser hélio-neônio de baixa intensidade na cicatrização de lesões

1 %

cutâneas induzidas em ratos", Revista Brasileira de Fisioterapia, 2010

Publication

16

www.frontiersin.org

Internet Source

1 %

17

Ola Ahmed Bakry, Rehab Monir Samaka, Mohamed Abdel Moneim Shoeib, Doaa Mohamed Megahed. "Immunolocalization of Glioma-Associated Oncogene Homolog 1 in Non Melanoma Skin Cancer", *Ultrastructural Pathology*, 2014

Publication

<1 %

18

lume.ufrgs.br

Internet Source

<1 %

19

pubmed.ncbi.nlm.nih.gov

Internet Source

<1 %

20

wjon.org

Internet Source

<1 %

Exclude quotes Off

Exclude bibliography On

Exclude matches < 10 words