

06. Deadly complication of sacrificing superior petrosal vein

by Irwan Barlian Immadoel Haq

Submission date: 06-Jul-2022 01:06PM (UTC+0800)

Submission ID: 1867187315

File name: 6._Deadly_complication_of_sacrificing_superior_petrosal_vein.pdf (972.87K)

Word count: 4112

Character count: 22841



Case Report

Deadly complication of sacrificing superior petrosal vein during cerebellopontine angle tumor resection: A case report and literature review

Irwan Barlian Immadoel Haq, Andhika Tomy Permana, Rahadian Indarto Susilo, ¹³Joni Wahyuhadi

Department of Neurosurgery, Faculty of Medicine Universitas Airlangga - Dr. Soetomo General Academic Hospital, Surabaya, East Java, Indonesia.

E-mail: Irwan Barlian Immadoel Haq - immadoelhaq@gmail.com; Andhika Tomy Permana - andhika_2010@yahoo.com; Rahadian Indarto Susilo - rahadian-i-s@fk.unair.ac.id, *Joni Wahyuhadi - joniwahyuhadi@fk.unair.ac.id



*Corresponding author:

¹³Joni Wahyuhadi,
Department of Neurosurgery,
Faculty of Medicine Universitas
Airlangga - Dr. Soetomo
General Academic Hospital,
Surabaya, East Java, Indonesia.
joniwahyuhadi@fk.unair.ac.id

²⁷Received : 25 December 2020

Accepted : 01 April 2021

Published : 28 June 2021

DOI

10.25259/SNI_948_2020

Quick Response Code:



ABSTRACT

Background: Tumors of the cerebellopontine angle (CPA) are challenging to resect and have been proven difficult for neurosurgeons to manage optimally. Superior petrosal vein complex (SPVC) as the main drainage system and close proximity to CPA could be an obstacle during operation. There is an incidence ranging from 55% to 84% of injury to one part of the SPVC during CPA tumor surgery.

Case Description: We report a case of 65-year-old woman with CPA tumor, who complained of unilateral hearing loss, dizziness, and facial pain. During tumor resection, one part of SPV complex was injured, then cerebellar edema develops.

Conclusion: This case provides an overview of surgical complication associated with venous sacrifice. This would support the agreement to preserve SPV regarding risks and improve the quality of surgical decision making.

Keywords: Cerebellopontine angle, Meningioma, Sacrifice, Superior petrosal vein, Tumor resection

INTRODUCTION

⁸Meningiomas account for 26% of primary intracranial neoplasms.⁹ Among intracranial meningiomas, 5–10% are located in the cerebellopontine angle (CPA).⁹ Meningiomas represent the second most common type of neoplasm of CPA^{5,9,12} with a prevalence of 3–13% of all CPA lesions.⁵ CPA meningiomas account for 1.5% of intracranial meningiomas and dominated (58.3%) in a series of meningiomas of the posterior skull base.¹²

⁷CPA often enabling complete surgical removal. However, complete removal can carry potential risks that may be significant, especially when the tumor has invaded brain tissue or surrounding veins.⁵ Superior petrosal veins (SPVs) are often obstacles during surgery in the upper CPA.¹⁶ SPV complex (SPVC) is a major draining system in the posterior fossa and a consistent landmark within the CPA.¹⁷

Attention has been paid to SPVs during surgeries for tumor in the upper CPA, and the number of reports on associated complications, especially during meningioma surgeries, has recently increased.¹⁶ Injury of a part of the SPVC has been frequently reported in large case series, with an incidence ranging from 55% to 84% of cases.¹⁴

¹¹This is an open-access article distributed under the terms of the Creative Commons Attribution-Non Commercial-Share Alike 4.0 License, which allows others to remix, tweak, and build upon the work non-commercially, as long as the author is credited and the new creations are licensed under the identical terms.

©2021 Published by Scientific Scholar on behalf of Surgical Neurology International

Subsequently, sacrifice of veins is common practice to gain surgical exposure.^[2] The safety of SPV sacrifice is a challenging question.^[20] Yet, current literature indicates that complications following venous sacrifice are underreported. Hence, surgical literature on safety and complications of venous sacrifice in the posterior fossa remains contradictory.^[2] In this manuscript, we report a case of the complication of SPV sacrifice during CPA tumor resection.

ILLUSTRATIVE CASE

History and examination

A 65-year-old woman was referred from the previous hospital with some symptoms of a CPA tumor. She reported a history of pain on her cheeks and lower jaw. She also complained about left ear hearing loss and dizziness. These symptoms have appeared for 6 months and are getting worse. Neurological examination revealed cranial nerve V, VII, and VIII abnormalities. The patient had already been informed and consent regarding the publication of her data.

Radiological findings

Magnetic resonance imaging without contrast was performed at previous hospital and showed a lesion at left CPA [Figure 1]. Diagnosis of petrotentorial tumor has been confirmed. Due to economic issue, radiologic examination with contrast agent was not conducted. Preoperative venography did not perform on CPA tumor according to hospital policy.

Operation and postoperative reports

Surgery was initiated with park-bench position, retrosigmoid craniotomy, and exploration of the CPA. It appears that the cerebellum relaxes and the left cerebellopontine exposes after the cisterna magna was opened and cerebrospinal fluid was released.

Arachnoid detachment was performed to separate the tumor from the cerebellar tissue. During surgical debulking

of tumor, the left SPV attached to the tumor was cut off. Coagulation technique with bipolar cautery to stop bleeding was given immediately. The surgeon noticed progressive cerebellar swelling and the CPA becomes inaccessible a 15 min later. Cerebellar tissue begins to swell and extends beyond the border of the craniotomy. In consequence, the craniotomy was widened so that we could remove the rest of tumor. Bone flap was not put back in place. Dural graft was chosen to be placed over the cerebellar tissue followed by closure of the muscle, fascia, and skin.

The patient was transferred in radiology for an emergency computed tomography (CT) scan and the results showed left cerebellar edema and hemorrhage with concomitant developing hydrocephalus [Figure 2].

The patient was transferred back to the operating room and the Kocher's point for the right external ventricular drainage was positioned. The patient was then transferred to the intensive care unit and remained sedated for 24 h. Another head CT scan was performed and showed an advancement of hemorrhage [Figure 3].

When sedation is stopped, the pupils are small and unreactive. The patient does not respond to pain, verbal, and eye stimulation. Glasgow Coma Scale is 3. No corneal reflex. The patient died 24 h later.

DISCUSSION

Anatomical perspective of SPV

The venous drainage of the SPV has many variations. These veins are among the largest and the most frequent veins in the posterior fossa. The SPVs drain the anterior and lateral surfaces of the brainstem, the petrosal surface, and some lateral parts of the tentorial and suboccipital surfaces.^[11] Tanriover *et al.* group updated the classification as Type 1, Type 2, and Type 3 based on relationship of its site of entry into the SPS, Meckel cave, and the internal acoustic meatus (IAM) [Figure 4].^[4,20,27] In Type 1, the SPV complex empties

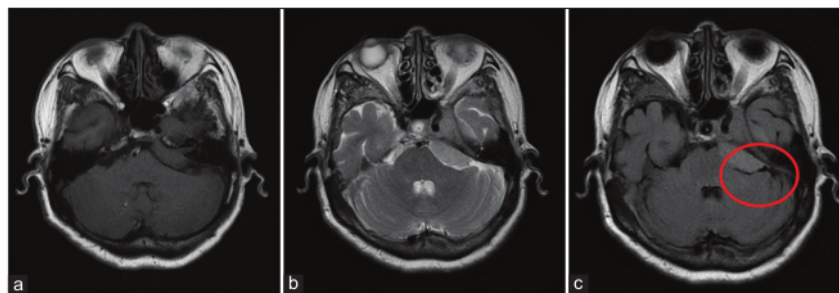


Figure 1: MR without contrast imaging of axial shows hypointense on T1 (a) and hyperintense in T2 (b) revealed extra-axial lesion in the left cerebellopontine angle. Flow void appearance on T2 flair (c) refers to the left superior petrosal vein attached to the lesion.

in to the superior petrosal sinus (SPS) or lateral to the IAM. In Type 2, SPV complex empties into the SPS between the lateral limit of the trigeminal nerve and the medial limit of facial nerve. In Type 3, the SPV complex empties into the SPS at a point medial to the lateral limit of trigeminal nerve.^[20]

After SPV obliteration, compensatory venous blood drainage seems to occur through anastomotic pathways directed to the ipsilateral supratentorial deep veins. Anastomoses to the contralateral petrosal vein system do not suffice to install an adequate outflow.^[11]

Clinical implication of SPV occlusion

CPA has always proven difficult for neurosurgeons to optimally manage,^[1] also challenging to resect because of their complex

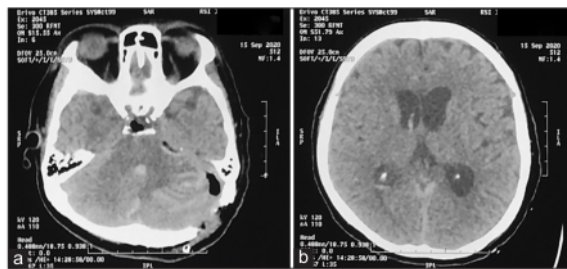


Figure 2: CT imaging early postoperative shows cerebellar edema and hemorrhagic on cerebellum (a) and hydrocephalus (b).

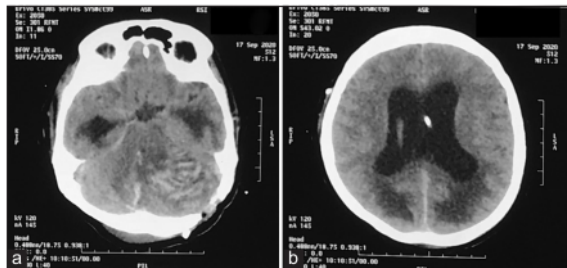


Figure 3: CT imaging 2 days postoperative shows increase of cerebellar edema and hemorrhagic on cerebellum (a) and hydrocephalus with extracranial drainage device placement (b).

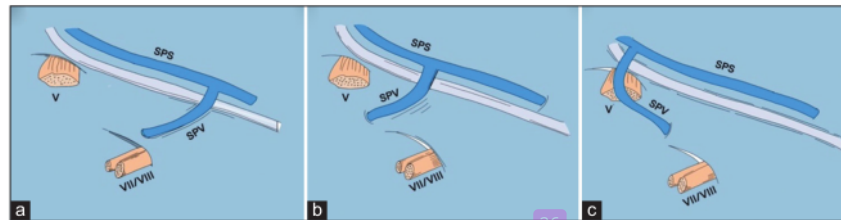


Figure 4: Type of SPV drainage into the SPS according to Tanriover *et al.*^[27] Type I drainage of the SPV into the SPS (a). Type II drainage (b). Type III drainage (c). SPS: Superior petrosal sinus, SPV: Superior petrosal vein, V: Fifth cranial nerve, VII/VIII: Seventh and eighth cranial nerves.^[4]

regional anatomy, the deep and narrow surgical corridors involved, and the abundance of vital neurovascular structures in the surgical field.^[25] The posterior fossa venous anatomy is often not well visualized during surgery. This is particularly true regarding the SPVC. The SPV also has variable anatomy as it may be the terminal segment of one single vein or may form as the common union of multiple veins.^[15]

Coagulation and dissection of the SPV do not frequently cause adverse sequelae. Several large series study of sacrificing SPV in petrous tumor showed negligible complication, in a study of 55 patients with petrous meningioma surgery, the SPV was sacrificed in 49% of the case and only 3 patients had hearing loss complication, compared with other group which SPV was preserved, 3 patients also had hearing loss complication ($P > 0.05$).^[10] Another study conducted in 12 patients which all of the patient's SPV were sectioned, no mortality was found and all of the patient had good performance after the surgery.^[24]

Another study conducted in sacrificing SPV showed the benefit of venography before surgery to identify SPV type and its tributary, helping surgeon decision to preserve or to sacrifice the SPV. This study described no venous complication for all patient who underwent surgery with sacrificing or preserving SPV with 1 patient as SPV Type 1, 2 patients as SPV Type 2 and 4 patients as SPV Type 3 in sacrificed group, and 17 patients as SPV Type 2 and 1 patient as SPV Type 3.^[19]

Larger study supporting the safety of sacrificing SPV was conducted in microvascular decompression (MVD) procedure for trigeminal neuralgia (TN). A study in 4400 patients underwent MVD procedure for TN showed that SPV is safe to be sectioned without causing major morbidity or mortality.^[18] Another study with fewer case also reported that sacrificing SPV causes only <0.5% of venous infarction and not causing direct morbidity to the patient.^[7]

In the opposite hand, several studies reported some devastating effect due to sacrificing of SPV [Table 1].^[3,10,13-15,19,21-23,28,29] The complication was reported occurred in up to 31% of the case. Recent study on a substantial number of patients with petrous apex meningiomas has revealed minor venous congestion phenomena in 23% and major complications in almost 7% of

Table 1: Study showing complication of sacrificing SPV and preserving SPV.

Author and year	Total patients	Sample's diagnosis	Complication	Imaging evaluation	Study result
Xia <i>et al.</i> (2020) ^[29]	592	TN	No venous complication	No edema, no hydrocephalus, and no hemorrhage	No venous complication was shown in SPV sacrificed group Venous complication was shown on 1.1% of patients in SPV preserved group
Watanabe <i>et al.</i> (2013) ^[28]	43	Petrous Apex Meningioma	Elevated ICP	Venous infarction of cerebellum Cerebellar edema	SPV preservation showed no complication (n=24) Sacrificing SPV cause major and minor morbidity in 31% of patients (n=14) (P<0.05)
Gharabaghi <i>et al.</i> (2006) ^[10]	55	Petrous Apex Meningioma	Hearing loss	No edema, no hydrocephalus, and no hemorrhage	Sacrificing SPV (n=27) and preserving SPV (n=26) showed no significance different in causing complication (P>0.05)
Koerbel <i>et al.</i> (2009) ^[14]	59	Petrous Apex Meningioma	Elevated ICP	Ventriculomegaly Cerebellar edema Venous infarction	SPV preservation showed no complication (n=27) Sacrificing SPV cause major and minor morbidity in 30% of patients (n=30) (P<0.05)
Kaku <i>et al.</i> (2012) ^[13]	5	Petrodival Meningioma	Facial numbness	NA	Minor complication occurred in 1 patient which SPV was sacrificed and no complication was noted in 4 other patients which SPV was preserved
Mizutani <i>et al.</i> (2016) ^[19]	28	Petrodival Meningioma	No venous complication	NA	No venous complication was observed in sacrificed (n=7) and preserved (n=18) SPV group
Perrini <i>et al.</i> (2017) ^[22]	1	Petrous Apex Meningioma	Elevated ICP	Obstructive hydrocephalus Cerebellar venous infarction	Patient was unconscious after surgery with elevated ICP, hydrocephalus, and cerebellar venous infarction. Patient died 13 days after surgery
Ryu <i>et al.</i> (1999) ^[23]	132	TN	Elevated ICP	Bleeding cerebellar infarction	Only 1 patient had complication after SPV sacrifice (0.01%), where overall mortality was 0.8%
Liebelt <i>et al.</i> (2017) ^[15]	98	TN	Elevated ICP Hemiparesis Slurred speech Facial palsy	Cerebellar and brainstem infarction with edema	SPV preservation resulting no complication and all patients with SPV sacrifice have venous complication (P<0.05)
Pathmanaban <i>et al.</i> (2017) ^[21]	224	TN	Elevated ICP Cerebellar syndrome	Sinus thrombosis	Only 2.7% of patients had sinus thrombosis and no venous infarction was identified in all patients who had SPV sacrifice in surgery (n=184)
Anichini <i>et al.</i> (2016) ^[3]	1	TN	Elevated ICP Comma	Obstructive Hydrocephalus Cerebellar Infarction	Complication occurred on second surgery when SPV was sacrificed

SPV: Superior petrosal veins, ICP: Intracranial pressure, TN: Trigeminal neuralgia

cases after intraoperative obliteration of the SPV.^[28] Another study in petrous apex meningioma, the patient also showed significance difference in complication resulted by sacrificing SPV compared to preserving it with the complication rate reach 30% of the cases.^[14]

In general, one out of several tributaries of the SPV or tentorial veins was considered safe to occlude, although most surgeon considered certain risks of infarction and edema with any venous occlusion [Figure 5]. In contrast, mortality was considered to exceed 10% with sacrifice of the specific structure such as the SPV main trunk, one of the sigmoid sinuses, and extensive tentorial bridging venous drainage.^[2]

Sacrifice of veins rarely leads to complications (1.6% on average, according to reports). Nevertheless, some

may be severe and even life threatening and necessitate emergency management.^[6] The complications reported in the previous study include contralateral hearing loss, transient postoperative cochlear nerve deficit, cerebellar and brainstem edema, cerebellar venous infarction, peduncular hallucinosis, cerebellar hemorrhage, brainstem hemorrhage, and hydrocephalus, leading in some cases to coma and death.^[11] Alaoui-Ismaili *et al.* findings supported the notion that routine venous sacrifice for surgical access may carry a risk of serious complications and death.^[2] Some patients died from unexpected major complications such as extensive cerebellar swelling and hemorrhagic infarction.^[16]

Neurosurgeons commonly sacrifice SPV to widen the operative exposure at the apex.^[2] It was proven that sacrifice

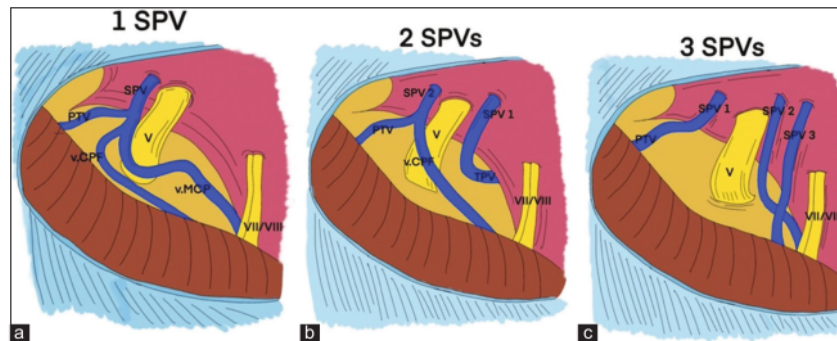


Figure 5: The three main patterns of an SPVC. (a) An SPVC with single SPV, (b) an SPVC with 2 SPVs, (c) an SPVC with 3 SPVs. ALMv: Anterior lateral marginal vein, PTV: Pontotrigeminal vein, SPS: Superior petrosal sinus, SPV: Superior petrosal vein, SPVC: Superior petrosal vein complex, SPV1: First superior petrosal vein, SPV2: Second superior petrosal vein, SPV3: Third superior petrosal vein, TPV: Transverse pontine vein, v.CPF: Vein of cerebellopontine fissure, v.MCP: Vein of the middle cerebellar peduncle, V: Trigeminal nerve, VII/VIII: Seventh and eighth cranial nerves.^[4]

of even only 1 branch of the SPV may induce venous congestion, so the individual variations of the venous system necessitate a careful tailored attitude.^[6] As was the case with our patient, in the absence of adequate data on SPV radiologically or intraoperatively in this patient, sacrifice SPV in our patient resulted in fatal cerebellar congestion.

Effort should be made to avoid the complication of sectioned SPV. Although not always possible, radiological study of venous anatomical variation through venography in each patient could tell the surgeon whether it is safe or not to sacrifice the SPV and its tributaries.^[30] In general, what is assessed on CTV in patients with CPA tumors is the patency and extent of SPV visualization. In cases where the SPV cannot be visualized by the CTV (SPV Type 4), the petrosal vein only drains the vascularization from the tumor itself, meaning that the vein may be safely sacrificed after the devascularization of the tumor.^[19]

Another way of assessing the safety of SPV sacrifice can also be done intraoperatively with temporary clamping of SPV. Assessment can be made in plain view to assess the edema, but a more objective report by monitoring the auditory potential of the brain stem has been reported.^[26,30] In addition, another study reported reports of collateral venous drainage in transient vein clamping with indocyanine green video angiography.^[8]

Surgical technique with combined petrosal approach, SPV preservation, and dural incision approach described in previous report could be used to increase the probability to preserve SPV.^[11] A good extension of arachnoid dissection also could provide easier maneuvering and mobilization to get good exposure to the operation target. In case which SPV has to be sacrificed, the main trunk and its big tributary

should be avoided to prevent venous complication. The diameter of the SPV which will be sacrificed should also be considered since the previous study described that SPV with diameter <2 mm was safe to be sacrificed.^[20]

Similarly, the use of fully endoscopic and endoscope-assisted microsurgery with and without angled optics may minimize the extent of venous sacrifice required to obtain optimum visualization. The risk of inadvertent injury to a preserved SPV with resultant bleeding into the CPA seems unlikely to be improved with this approach however and may be worse due to loss of vision for structures superficial to the tip of the endoscope. Furthermore, management of such bleeding in the CPA may be problematic with an endoscope, where a clear view of the field can be lost. Subsequently, although the problem is often not discussed in the endoscopic literature, some authors describe sacrifice of the SPV when it is encountered to improve endoscopic exposure as with the microscopic technique.^[21]

CONCLUSION

The surgeon must fully understand the essential anatomical knowledge of the veins to assess surgical risk and assess feasibility of venous sacrifice. The decision not to sacrifice SPV should be made during CPA tumor resection or other intracanal case surgery because of the potentially lethal complication. According to this case, there are several options that could be made, that is, preservation of the veins, temporary vein clamping followed by intraoperative evaluation, preoperative venography to consider the safety of sacrificing SPV complex, and avoiding long and continuous retraction of cerebellum.

Declaration of patient consent

Patient's consent not required as patients identity is not disclosed or compromised.

Financial support and sponsorship

Nil.

Conflicts of interest

There are no conflicts of interest.

REFERENCES

- Agarwal V, Babu R, Grier J, Adogwa O, Back A, Friedman AH, *et al.* Cerebellopontine angle meningiomas: Postoperative outcomes in a modern cohort. *Neurosurg Focus* 2013;35:E10.
- Alaoui-Ismaili A, Krogager ME, Jakola AS, Poulsgaard L, Couldwell W, Mathiesen T. Surgeons' experience of venous risk with CPA surgery. *Neurosurg Rev* 2020;2020:01365-5.
- Anichini G, Iqbal M, Rafiq NM, Ironside JW, Kamel M. Sacrificing the superior petrosal vein during microvascular decompression. Is it safe? Learning the hard way. Case report and review of literature. *Surg Neurol Int* 2016;7:S415-20.
- Basamh M, Sinning N, Kehler U. Individual variations of the superior petrosal vein complex and their microsurgical relevance in 50 cases of trigeminal microvascular decompression. *Acta Neurochir (Wien)* 2020;162:197-209.
- Belachew A, Chowdhury T, Spiriev T, Sandu N, Schaller B. Classification of Meningiomas. *Springer Sci Media* 2015;14:43-53.
- Dumot C, Sindou M. Veins of the cerebellopontine angle and specific complications of sacrifice, with special emphasis on microvascular decompression surgery. A review. *World Neurosurg* 2018;117:422-32.
- Elhammady MS, Heros RC. Cerebral veins: To sacrifice or not to sacrifice, that is the question. *World Neurosurg* 2015;83:320-4.
- Ferrolì P, Nakaji P, Acerbi F, Albanese E, Broggi G. Indocyanine green (ICG) temporary clipping test to assess collateral circulation before venous sacrifice. *World Neurosurg* 2011;75:122-5.
- Gao K, Ma H, Cui Y, Chen X, Ma J, Dai J. Meningiomas of the cerebellopontine angle: Radiological differences in tumors with internal auditory canal involvement and their influence on surgical outcome. *PLoS One* 2015;10:e0122949.
- Gharabaghi A, Koerbel A, Löwenheim H, Kaminsky J, Samii M, Tatagiba M. The impact of petrosal vein preservation on postoperative auditory function in surgery of petrous apex meningiomas. *Neurosurgery* 2006;59:ONS68-74.
- Haq IB, Susilo RI, Goto T, Ohata K. Dural incision in the petrosal approach with preservation of the superior petrosal vein. *J Neurosurg* 2016;124:1074-8.
- He X, Liu W, Wang Y, Zhang J, Liang B, Huang JH. Surgical management and outcome experience of 53 cerebellopontine angle meningiomas. *Cureus* 2017;9:e1538.
- Kaku S, Miyahara K, Fujitsu K, Hataoka S, Tanino S, Okada T, *et al.* Drainage pathway of the superior petrosal vein evaluated by CT venography in petroclival meningioma surgery. *J Neurol Surg B Skull Base* 2012;73:316-20.
- Koerbel A, Gharabaghi A, Safavi-Abbasi S, Samii A, Ebner FH, Samii M, *et al.* Venous complications following petrosal vein sectioning in surgery of petrous apex meningiomas. *Eur J Surg Oncol* 2009;35:773-9.
- Liebelt BD, Barber SM, Desai VR, Harper R, Zhang J, Parrish R, *et al.* Superior Petrosal vein sacrifice during microvascular decompression: Perioperative complication rates and comparison with venous preservation. *World Neurosurg* 2017;104:788-94.
- Matsushima T, Kawashima M, Inoue K, Matsushima K. Anatomy of the superior petrosal veins and their exposure and management during petrous apex meningioma surgery using the lateral suboccipital retrosigmoid approach. *Neurosurg Rev* 2014;37:535-456.
- Matsushima T, Rhoton AL Jr, de Oliveira E, Peace D. Microsurgical anatomy of the veins of the posterior fossa. *J Neurosurg* 1983;59:63-105.
- McLaughlin MR, Jannetta PJ, Clyde BL, Subach BR, Comey CH, Resnick DK. Microvascular decompression of cranial nerves: Lessons learned after 4400 operations. *J Neurosurg* 1999;90:1-8.
- Mizutani K, Toda M, Yoshida K. The Analysis of the petrosal vein to prevent venous complications during the anterior transpetrosal approach in the resection of petrodial meningioma. *World Neurosurg* 2016;93:175-82.
- Narayan V, Savardekar AR, Patra DP, Mohammed N, Thakur JD, Riaz M, *et al.* Safety profile of superior petrosal vein (the vein of Dandy) sacrifice in neurosurgical procedures: A systematic review. *Neurosurg Focus* 2018;45:E3.
- Pathmanaban ON, O'Brien F, Al-Tamimi YZ, Hammerbeck-Ward CL, Rutherford SA, King AT. Safety of superior petrosal vein sacrifice during microvascular decompression of the trigeminal nerve. *World Neurosurg* 2017;103:84-7.
- Perrini P, Di Russo P, Benedetto N. Fatal cerebellar infarction after sacrifice of the superior petrosal vein during surgery for petrosal apex meningioma. *J Clin Neurosci* 2017;35:144-5.
- Ryu H, Yamamoto S, Sugiyama K, Yokota N, Tanaka T. Neurovascular decompression for trigeminal neuralgia in elderly patients. *Neurol Med Chir (Tokyo)* 1999;39:226-9.
- Samii M, Tatagiba M, Carvalho GA. Retrosigmoid intradural suprameatal approach to Meckel's cave and the middle fossa: Surgical technique and outcome. *J Neurosurg* 2000;92:235-41.
- Spena G, Sorrentino T, Altieri R, Zinis LR, Stefani R, Panciani PP, *et al.* Early-career surgical practice for cerebellopontine angle tumors in the era of radiosurgery. *J Neurol Surg B Skull Base* 2018;79:269-81.
- Strauss C, Neu M, Bischoff B, Romstöck J. Clinical and neurophysiological observations after superior petrosal vein obstruction during surgery of the cerebellopontine angle: Case report. *Neurosurgery* 2001;48:1157-9; discussion 1159-61.
- Tanriover N, Abe H, Rhoton AL Jr, Kawashima M, Sanus GZ, Akar Z. Microsurgical anatomy of the superior petrosal venous complex: New classifications and implications for subtemporal transtentorial and retrosigmoid suprameatal approaches. *J Neurosurg* 2007;106:1041-50.
- Watanabe T, Igarashi T, Fukushima T, Yoshino A, Katayama Y. Anatomical variation of superior petrosal vein and its

management during surgery for cerebellopontine angle meningiomas. *Acta Neurochir (Wien)* 2013;155:1871-8.

29. Xia Y, Kim TY, Mashouf LA, Patel KK, Xu R, Casaos J, *et al.* Absence of ischemic injury after sacrificing the superior petrosal vein during microvascular decompression. *Oper Neurosurg (Hagerstown)* 2020;18:316-20.
30. Zhong J, Li ST, Xu SQ, Wan L, Wang X. Management of

petrosal veins during microvascular decompression for trigeminal neuralgia. *Neurol Res* 2008;30:697-700.

How to cite this article: Haq IB, Permana AT, Susilo RI, Wahyuhadi J. Deadly complication of sacrificing superior petrosal vein during cerebellopontine angle tumor resection: A case report and literature review. *Surg Neurol Int* 2021;12:306.

06. Deadly complication of sacrificing superior petrosal vein

ORIGINALITY REPORT

18%

SIMILARITY INDEX

9%

INTERNET SOURCES

16%

PUBLICATIONS

0%

STUDENT PAPERS

PRIMARY SOURCES

- 1** Watanabe, Takao, Takahiro Igarashi, Takao Fukushima, Atsuo Yoshino, and Yoichi Katayama. "Anatomical variation of superior petrosal vein and its management during surgery for cerebellopontine angle meningiomas", *Acta Neurochirurgica*, 2013. 1 %
Publication

- 2** Necmettin Tanriover, Hiroshi Abe, Albert L. Rhoton, Masatou Kawashima, Galip Z. Sanus, Ziya Akar. "Microsurgical anatomy of the superior petrosal venous complex: new classifications and implications for subtemporal transtentorial and retrosigmoid suprameatal approaches", *Journal of Neurosurgery*, 2007 1 %
Publication

- 3** Sho TSUNODA, Tomohiro INOUE, Masafumi SEGAWA, Atsuya AKABANE. "Vein-related Trigeminal Neuralgia: How to Determine the Treatment Method of the Causative Vein: A Technical Note", *Neurologia medico-chirurgica*, 2021 1 %

4	www.neurosurgicalatlas.com Internet Source	1 %
5	Vincent Huang, Stephen P. Miranda, Ryan Dimentberg, Kaitlyn Shultz, Scott D. McClintock, Neil R. Malhotra. "Effect of Household Income on Short-Term Outcomes Following Cerebellopontine Angle Tumor Resection", <i>Journal of Neurological Surgery Part B: Skull Base</i> , 2021 Publication	1 %
6	assets.cureus.com Internet Source	1 %
7	www.omicsonline.org Internet Source	1 %
8	Kun Gao, Housheng Ma, Yong Cui, Xuzhu Chen, Jun Ma, Jianping Dai. "Meningiomas of the Cerebellopontine Angle: Radiological Differences in Tumors with Internal Auditory Canal Involvement and Their Influence on Surgical Outcome", <i>PLOS ONE</i> , 2015 Publication	1 %
9	www.thieme-connect.com Internet Source	1 %
10	Alex Kørup, René Christensen, Connie Nielsen, Jens Søndergaard et al. "The International NERSH Data Pool—A Methodological	1 %

Description of a Data Pool of Religious and Spiritual Values of Health Professionals from Six Continents", Religions, 2017

Publication

11

www.researchgate.net

Internet Source

1 %

12

Toshio Matsushima. "Microsurgical Anatomy and Surgery of the Posterior Cranial Fossa", Springer Nature, 2015

Publication

1 %

13

balimedicaljournal.org

Internet Source

1 %

14

Katsuhiro Mizutani, Masahiro Toda, Kazunari Yoshida. "The Analysis of the Petrosal Vein to Prevent Venous Complications During the Anterior Transpetrosal Approach in the Resection of Petroclival Meningioma", World Neurosurgery, 2016

Publication

1 %

15

vdoc.pub

Internet Source

1 %

16

Yong Yue, Zhen-Ran Zhao, De-Cai Liu, Heng-Jian Liu, Dong-Lin Lu, Heng Zhang, Peng Jin. "Life-threatening complications after microvascular decompression procedure: Lessons from a consecutive series of 596

<1 %

patients", Journal of Clinical Neuroscience,
2021

Publication

17

MASUOKA, Jun, Tomihiro WAKAMIYA,
Toshihiro MINETA, Yukinori TAKASE, Masatou
KAWASHIMA, and Toshio MATSUSHIMA.

"Thrombosis of the Superior Petrosal Vein
Mimicking Brain Tumor", Neurologia medico-
chirurgica, 2009.

Publication

<1 %

18

thejns.org

Internet Source

<1 %

19

B. Schaller, A. Merlo, O. Gratzl, R. Probst.
"Premeatal and Retromeatal Cerebellopontine
Angle Meningioma. Two Distinct Clinical
Entities", Acta Neurochirurgica, 1999

Publication

<1 %

20

Francesco Tomasello, Filippo Flavio Angileri,
Alfredo Conti, Antonino Scibilia et al. "Petrosal
Meningiomas: Factors Affecting Outcome and
the Role of Intraoperative Multimodal
Assistance to Microsurgery", Neurosurgery,
2019

Publication

<1 %

21

Tumors of the Central Nervous System, 2015.

Publication

<1 %

22

idoc.pub

Internet Source

<1 %

23

Albert L. Rhoton. "The Posterior Fossa Veins",
Neurosurgery, 2000

Publication

<1 %

24

Florian Roser. "Peduncular Hallucinosi:
Insights from a Neurosurgical Point of View",
Neurosurgery, 11/2005

Publication

<1 %

25

Nader Sanai, Zaman Mirzadeh, Michael T.
Lawton. "Supracerebellar-Supratrochlear and
Infratentorial-Infratrochlear Approaches",
Operative Neurosurgery, 2010

Publication

<1 %

26

www.ajnr.org

Internet Source

<1 %

27

www.frontiersin.org

Internet Source

<1 %

28

"Skull Base Surgery of the Posterior Fossa",
Springer Science and Business Media LLC,
2018

Publication

<1 %

29

Ciro A. Vasquez, John A. Thompson, A. Samy
Youssef. "The Tentorial Bridge to Deep Skull
Base Exposure: Anatomic Morphometric
Study", World Neurosurgery, 2018

Publication

<1 %

30 Rachel Blue, Carrie Li, Michael Spadola, Anissa Saylany, Brendan McShane, John Y.K. Lee. <1 %
"Complication Rates During Endoscopic Microvascular Decompression Surgery Are Low With or Without Petrosal Vein Sacrifice", World Neurosurgery, 2020
Publication

31 Samii s Essentials in Neurosurgery, 2014. <1 %
Publication

32 docksci.com <1 %
Internet Source

33 www.journals.lapub.co.uk <1 %
Internet Source

34 www.jscimedcentral.com <1 %
Internet Source

35 Ken Matsushima, Toshio Matsushima, Yoshihiro Kuga, Yuji Kodama, Kohei Inoue, Hideyuki Ohnishi, Albert L. Rhoton. <1 %
"Classification of the Superior Petrosal Veins and Sinus Based on Drainage Pattern", Operative Neurosurgery, 2014
Publication

36 Ramadhan Ananditia Putra, Heri Suroto. <1 %
"Evaluation of Secretome Tenogenic Potential from Adipose Stem Cells (ACS) in Hypoxic Condition with Fresh Frozen Tendon Scaffold Using Scleraxis (Scx), Insulin-Like Growth

Factor 1 (IGF-1) and Collagen Type 1", Journal of Biomimetics, Biomaterials and Biomedical Engineering, 2021

Publication

37

Tomasz Andrzej Dziedzic, Kumar Abhinav, Juan C. Fernandez-Miranda. "Subtemporal Approach and Its Infratentorial Extension: Review and a Comparative Analysis of Different Techniques", Journal of Neurological Surgery Part B: Skull Base, 2022

Publication

<1 %

38

Tomy Nurtamin, Yudhistira Pradnyan Kloping, Johan Renaldo. "Symptomatic multiple prostatic calculi: A case report and literature review", Urology Case Reports, 2021

Publication

<1 %

Exclude quotes On

Exclude matches Off

Exclude bibliography On

06. Deadly complication of sacrificing superior petrosal vein

GRADEMARK REPORT

FINAL GRADE

/100

GENERAL COMMENTS

Instructor

PAGE 1

PAGE 2

PAGE 3

PAGE 4

PAGE 5

PAGE 6

PAGE 7
