

# Histomorphometric Analysis of Anti-Aging Properties on Rat Skin

*by* Idha Kusumawati

---

**Submission date:** 19-Apr-2021 03:30PM (UTC+0800)

**Submission ID:** 1563379222

**File name:** Jurnal\_C-2\_No\_Cover.pdf (323.79K)

**Word count:** 2491

**Character count:** 12483



# Chapter 22

## Histomorphometric Analysis of Anti-Aging Properties on Rat Skin

Idha Kusumawati, Kresma Oky Kurniawan, Subhan Rullyansyah, and Eka Pramytha Hestianah

### Abstract

We present a histomorphometric analysis to enable quantitative measurement of anti-aging activity of topical substances in rat skin. In this method, the measured parameters were closely related to changes that occur on the skin caused by exposure to UV light. We used this protocol to determine the anti-aging activities of an ethanolic extract of *Curcuma heyneana* rhizome and retinoic acid by a measurement of the changes in epidermal thickness, the number of sunburned cells, the number of fibroblasts, and the space between collagen fibers.

**Key words** Anti-aging assay, *Curcuma heyneana* rhizome, Histomorphometric analysis, Skin, UV rays

### 1 Introduction

Aging of the skin can cause changes in physical appearance, which are characterized by the appearance of wrinkles, irregular pigmentation, sagging, and elastosis [1–3]. The intrinsic aging process is natural and occurs within the skin, while aging caused by the environment, especially through exposure to UV radiation, is an external aging process [4, 5]. The latter is known as photoaging.

Photoaging causes damage to the structure and affects the function of the skin tissue. Increasing epidermal thickness is one example of changes in skin structure as a function of protection against exposure to UV light [2, 6]. UV light exposure also causes an increase in the number of sunburned cells, which are observed as having pyknotic nuclei and eosinophilic cytoplasm with the ultrastructural characteristics of apoptotic cells [7]. UV exposure also causes imbalances that cause a reduction in the number of fibroblasts and new collagen synthesis, as well as change the structure and composition of elastic fibers in the skin. These changes cause

functional changes and disorganization of skin tissue, which can appear as wrinkly, rough, slack, and pigmented [8–11].

Using a model based on changes in rat skin tissue caused by exposure to UV light, we describe an in vivo bioassay protocol to test the anti-aging properties of an ethanolic extract of *Curcuma heyneana* rhizome in comparison to those of retinoic acid. We previously showed demonstrated that *Curcuma heyneana* rhizome contains antioxidant activities that protect the skin against the aging effects of excessive exposure to UV light [12].

---

## 2 Materials

### 2.1 Animals, Solutions, and Reagents

1. 200–300 g healthy adult male rats (2–3 months old) (*see Note 1*).
2. 10% formalin solution.
3. Hematoxylin-eosin.
4. Ethanol.
5. Animal food.
6. Water.
7. *Curcuma heyneana* rhizome (dried) [12] (*see Note 2*).
8. Retinoic acid.
9. Vehicle (*see Note 3*).

### 2.2 Equipment and Software

1. Wooden box with a TL20W/12RS UV lamp installed at the top, 20 cm from the back of the animals (Fig. 1).
2. Razor blades.
3. Scissors.
4. Microdissection forceps.
5. Dissecting boards and pins.
6. Microwave.
7. Inverted system microscope IX71-IX2 series optical microscope (Olympus; Shinjuku-ku, Tokyo, Japan) (*see Note 4*).
8. DP71 camera (Olympus).
9. Cell D software (Olympus).
10. Statistical analysis package (*see Note 5*).

---

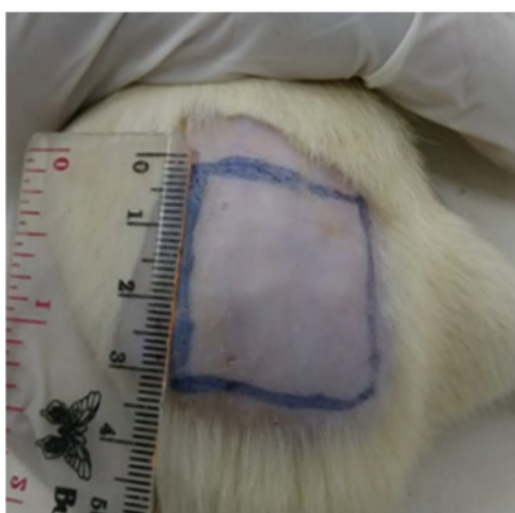
## 3 Methods

### 3.1 Animals

1. Acclimatize rats at least 5 days before use (*see Note 6*).
2. Set the temperature of the animal room at 22 °C ( $\pm 3$  °C) and the relative humidity at 30–70%.



**Fig. 1** Wooden box with TL20W/12RS UV lamp installed at the top of the box. The distance of the lamp was 20 cm from the back of the animals



**Fig. 2** Shaved back of rat

3. Set the lighting cycle at 12 h light and 12 h dark.
4. Provide a conventional diet with access to water ad libitum.
5. Shave the back of each rat to expose a 3 × 3 cm area (Fig. 2).

### 3.2 UV Ray Induction

1. Place rats inside the wooden box.
2. Expose the rats for 60 s each day and increase exposure a further 60 s every 2 days for a total of 21 days (see Note 7).
3. Shave the 3 × 3 cm area every 3 days during the protocol (see Note 8).

### 3.3 Preparation of *Curcuma heyneana* Rhizome Extract

1. Wash *Curcuma heyneana* rhizomes, cut, and dry in an oven set at 40 °C for 3 days.

2. Grind the dried material (100 g) into powder, and extract using 10 volumes of 70% ethanol by heating in a microwave at 30% power for 1 min.
3. Dry the extract by evaporating the ethanol under reduced pressure to obtain a crude extract.

### 3.4 Treatment

1. Assign the rats randomly into four groups: normal, vehicle, *Curcuma heyneana* rhizome extract, and retinoic acid drug reference.
2. Apply the sample (50 mg) to the area of the rat's shaved back topically each day for 21 days total.

### 3.5 Biopsy and Histology Analysis

1. After completion of the 21-day protocol, cull rats by cervical dislocation.
2. Remove the skin wounds from the shaved area using the dissection tools.
3. Fix the skin biopsies in 10% formalin solution, and embed into paraffin blocks for sectioning (2  $\mu\text{m}$ ) and staining using a combination of hematoxylin-eosin.
4. Observe and record images using the optical microscope and digital camera (Fig. 3).

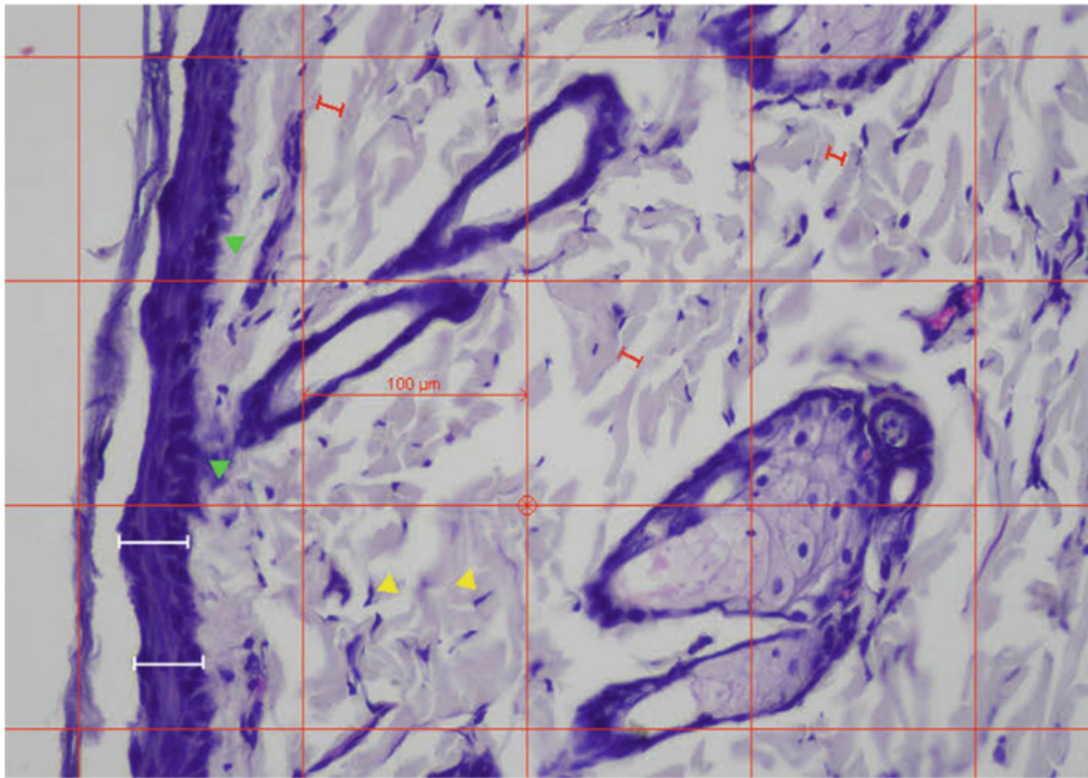
### 3.6 Statistical Analysis

1. Present the results as mean  $\pm$  standard error of the mean (SEM), and estimate statistical differences between groups using one-way analysis of variance (ANOVA) with Duncan's test, considering at  $p < 0.05$  as statistically significant.
2. Determine the epidermal thickness by histological analysis of the UV-exposed skin under the four conditions (Fig. 4) (see Note 9).
3. Determine the number of sunburned cells/ $\text{mm}^2$  by histological analysis of the UV-exposed skin under the four conditions (Fig. 5) (see Note 10).
4. Determine the number of fibroblasts/ $10,000 \mu\text{m}^2$  by histological analysis of the UV-exposed skin under the four conditions (Fig. 6) (see Note 11).
5. Determine the distance between collagen fibers in  $\mu\text{m}$  by histological analysis of the UV-exposed skin under the four conditions (Fig. 7) (see Note 12).

---

## 4 Notes

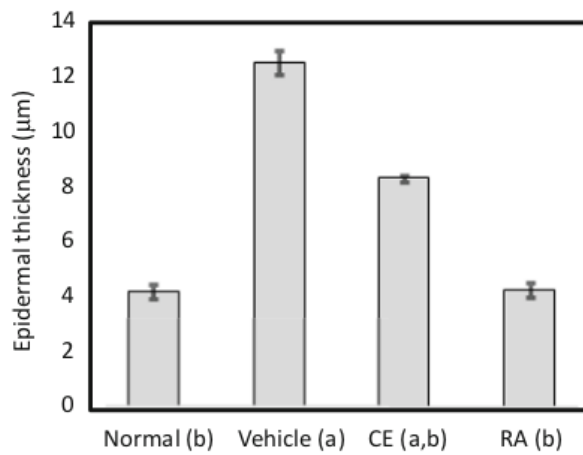
1. Ensure that all approvals are in place with the appropriate institutional authorities prior to beginning experiments. In this study, the research was designed based on the ethical



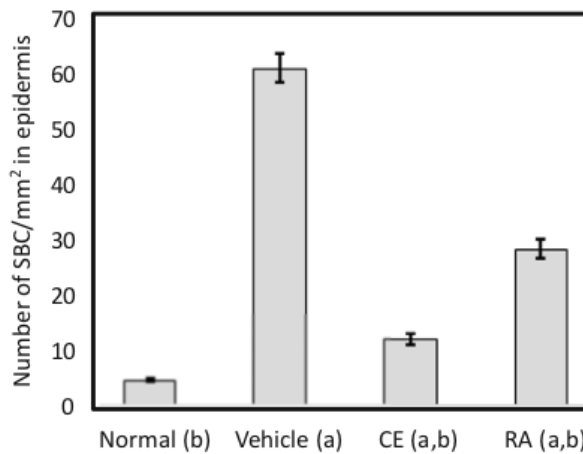
**Fig. 3** Quantitative histologic analysis of UV-exposed rat skin. White (epidermal thickness), green (sunburn cells; SBC), yellow (fibroblast), red (distance between collagen fibers). The red box shows an area of  $10,000 \mu\text{m}^2$

standards for animal use and approved by the Airlangga University Ethical Committee of Animal Experimentation (protocol number 1146/10).

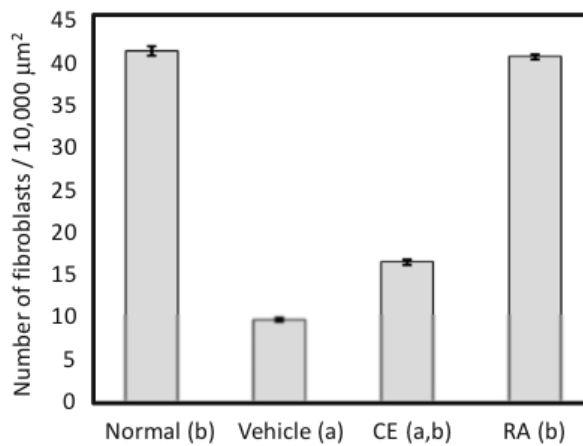
2. *Curcuma heyneana* is a zingiberaceous plant indigenous to Java Island, Indonesia. The *Curcuma heyneana* rhizome is aromatic and pale yellow and has been considered useful for the treatment of skin diseases and injuries. It is known by the local name temu giring and is used for beauty care in the traditions of the Javanese and Balinese people. The major constituents of *Curcuma heyneana* are curcuminoids and sesquiterpenes, with biological activities such as inhibition of protein tyrosine phosphatase 1B and anti-inflammatory and antibacterial effects [13].
3. The vehicle used should be semisolid (cream or gel base) instead of liquid. Attempts should be made so that this is similar to the *Curcuma heyneana* and retinoic acid samples.
4. In this study, we used the indicated Olympus microscope, camera, and analysis package. Other similar systems can be used given compatibility with the experimental procedures.



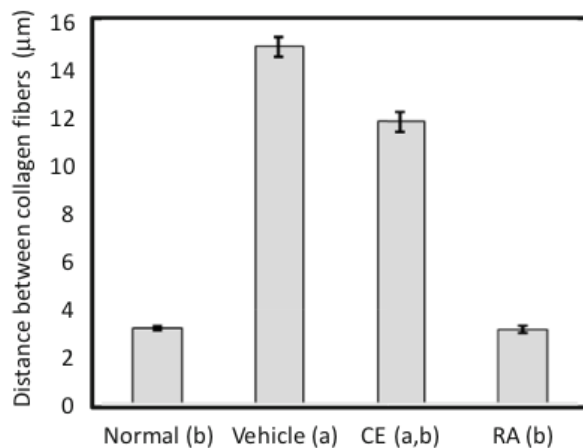
**Fig. 4** Epidermal thickness in  $\mu\text{m}$  of epidermis determined by histological analysis of UV-exposed rat skin. Values are expressed as mean  $\pm$  SEM ( $n = 10$ ). Means associated with each set of data are significantly different at  $p < 0.05$  (Duncan's test) from either (a) the normal group, (b) the vehicle group, or (a, b) both normal and vehicle groups, as indicated. Normal group: no UV exposure, no treatment. Vehicle group: UV exposure + vehicle treatment. CE group: UV exposure + crude extract treatment. RA group: UV exposure + retinoic acid treatment



**Fig. 5** Number of SBC/mm<sup>2</sup> in epidermis determined by histological analysis of UV-exposed rat skin. Values are expressed as mean  $\pm$  SEM ( $n = 10$ ). Means associated with each set of data are significantly different at  $p < 0.05$  (Duncan's test) from either (a) the normal group, (b) the vehicle group, or (a, b) both normal and vehicle groups, as indicated. Normal group: no UV exposure, no treatment. Vehicle group: UV exposure + vehicle treatment. CE group: UV exposure + crude extract treatment. RA group: UV exposure + retinoic acid treatment



**Fig. 6** Number of fibroblasts/10,000 μm<sup>2</sup> determined by histological analysis of UV-exposed rat skin. The values are expressed as mean ± SEM (*n* = 10). Means associated with each set of data are significantly different at *p* < 0.05 (Duncan's test) from either (a) the normal group, (b) the vehicle group, or (a, b) both normal and vehicle groups, as indicated. Normal group: no UV exposure, no treatment. Vehicle group: UV exposure + vehicle treatment. CE group: UV exposure + crude extract treatment. RA group: UV exposure + retinoic acid treatment



**Fig. 7** Distance between collagen fibers (μm) determined via histologic analysis of UV-exposed rat skin. Values are expressed as mean ± SEM (*n* = 10). Means associated with each set of data are significantly different at *p* < 0.05 (Duncan's test) from either (a) the normal group, (b) the vehicle group, or (a, b) both normal and vehicle groups, as indicated. Normal group: no UV exposure, no treatment. Vehicle group: UV exposure + vehicle treatment. CE group: UV exposure + crude extract treatment. RA group: UV exposure + retinoic acid treatment



5. Several statistical software packages can be used such as Microsoft Excel (Redmond, WA, USA) and SPSS (SPSS Inc., Chicago, IL, USA).
6. Acclimatizing the rats and ensuring conditions are constant and otherwise comfortable can reduce stress for more reproducible results.
7. UV exposure to mouse skin and sample administration should be done at the same time every day. The exposure time was optimized based on the strength of the lamp, according to amount of erythematous on the skin of the animal.
8. Rat skin at the sample location should be shaved every 3 days so that the sample applied to the skin is not disturbed by growing hair.
9. Histological analysis showed that UV exposure increased epidermal thickness threefold and topical application of the *Curcuma heyneana* rhizome extract and retinoic acid for 21 days minimized this increase.
10. The UV exposure led to a 14-fold increase in the number of sunburned cells (marked by the presence of pyknotic nuclei). This was reduced to only 2.7- and 6.4-fold over the normal situation (no UV exposure) by the *Curcuma heyneana* rhizome extract and retinoic acid treatments, respectively.
11. UV exposure resulted in a decrease of approximately 4.3-fold in the number of fibroblasts/mm<sup>2</sup> in the rat skin. This was partially protected with an observed 2.5-fold decrease following topical application of the *Curcuma heyneana* rhizome extract and was fully protected by the retinoic acid treatment.
12. The exposure of rat skin to UV irradiation for the 21-day period resulted in an approximate 4.6-fold increase in the space between collagen fibers, and this was partially restored (3.8-fold compared to the normal skin) by the *Curcuma heyneana* rhizome extract and completely restored by the retinoic acid treatment.

---

## Acknowledgments

This work was supported by an International Research Collaboration and Scientific Publication grant from the Ministry of Research, Technology, and Higher Education, Republic of Indonesia (Grant no. 597/UN3.14/LT/2017). Thanks to PT. Rembeka for the drug reference used in the in vivo assay. Also, thanks to all my student for the nice pictures.

## References

1. Cosgrove MC, Franco OH, Granger SP, Murray PG, Mayes AE (2007) Dietary nutrient intakes and skin-aging appearance among middle-aged American women. *Am J Clin Nutr* 86(4):1225–1231
2. Fore J (2006) A review of skin and the effects of aging on skin structure and function. *Ostomy Wound Manage* 52(9):24–35; quiz 36–37
3. Sies H, Stahl W (2004) Nutritional protection against skin damage from sunlight. *Annu Rev Nutr* 24:173–200
4. Kusumawati I, Indrayanto G (2013) Natural antioxidants in cosmetics. *Stud Nat Prod Chem* 40:485–505. <https://doi.org/10.1016/B978-0-444-59603-1.00015-1>
5. Saric S, Sivamani RK (2016) Polyphenols and sunburn. *Int J Mol Sci* 17(9). pii: E1521. <https://doi.org/10.3390/ijms17091521>
6. Chiu HW, Chen CH, Chen YJ, Hsu YH (2017) Far-infrared suppresses skin photoaging in ultraviolet B-exposed fibroblasts and hairless mice. *PLoS One* 12(3):e0174042. <https://doi.org/10.1371/journal.pone.0174042>
7. Okada T, Albarenque SM, Yasoshima A, Malcotti V, Katayama K, Uetsuka K et al (2003) Sunburn reaction in the dorsal skin of hypotrichotic WBN/ILA-Ht rats. *Histol Histopathol* 18(3):753–760. <https://doi.org/10.14670/HH-18.753>
8. Ghersetich I, Lotti T, Campanile G, Grappone C, Dini G (1994) Hyaluronic acid in cutaneous intrinsic aging. *Int J Dermatol* 33(2):119–122
9. Pasquali-Ronchetti I, Baccarani-Contri M (1997) Elastic fiber during development and aging. *Microsc Res Tech* 38(4):428–435
10. Zouboulis CC, Boschnakow A (2001) Chronological and photoaging of the human sebaceous gland. *Clin Exp Dermatol* 26(7):600–607
11. Hwang IS, Kim JE, Choi SI, Lee HR, Lee YJ, Jang MJ et al (2012) UV radiation-induced skin aging in hairless mice is effectively prevented by oral intake of sea buckthorn (*Hippophae rhamnoides* L.) fruit blend for 6 weeks through MMP suppression and increase of SOD activity. *Int J Mol Med* 30(2):392–400
12. Kusumawati I, Kurniawan KO, Rullyansyah S, Prijo TA, Widyowati R, Ekowati J et al (2018) Anti-aging properties of *Curcuma heyneana* Valetton & Zijp: a scientific approach to its use in Javanese tradition. *J Ethnopharmacol* 225:64–70
13. Widyowati R, Agil M (2018) Chemical constituents and bioactivities of several Indonesian plants typically used in Jamu. *Chem Pharm Bull (Tokyo)* 66(5):506–518

# Histomorphometric Analysis of Anti-Aging Properties on Rat Skin

## ORIGINALITY REPORT

3%

SIMILARITY INDEX

2%

INTERNET SOURCES

1%

PUBLICATIONS

0%

STUDENT PAPERS

## PRIMARY SOURCES

1

[ecfr.gov](http://ecfr.gov)

Internet Source

1%

2

[hrcak.srce.hr](http://hrcak.srce.hr)

Internet Source

1%

3

[journals.plos.org](http://journals.plos.org)

Internet Source

<1%

4

"Textbook of Aging Skin", Springer Science and Business Media LLC, 2017

Publication

<1%

5

Ki-Bae Hong, Yooheon Park, Jae Hwan Kim, Jin Man Kim, Hyung Joo Suh. "Effects of Porcine Placenta Extract Ingestion on Ultraviolet B-induced Skin Damage in Hairless Mice", Korean Journal for Food Science of Animal Resources, 2015

Publication

<1%

6

[archive.org](http://archive.org)

Internet Source

<1%

Exclude quotes Off

Exclude matches Off

Exclude bibliography On

# Histomorphometric Analysis of Anti-Aging Properties on Rat Skin

---

## GRADEMARK REPORT

---

FINAL GRADE

**/0**

GENERAL COMMENTS

**Instructor**

---

PAGE 1

---

PAGE 2

---

PAGE 3

---

PAGE 4

---

PAGE 5

---

PAGE 6

---

PAGE 7

---

PAGE 8

---

PAGE 9

---