

# Oral mucosal lesions and oral symptoms of the SarS-coV-2 infection

*by* Hendrik Setia Budi

---

**Submission date:** 13-Jun-2022 07:29AM (UTC+0800)

**Submission ID:** 1855538693

**File name:** ucosal\_lesions\_and\_oral\_symptoms\_of\_the\_SARS-CoV-2\_infection.pdf (667.64K)

**Word count:** 3216

**Character count:** 26801

## Oral mucosal lesions and oral symptoms of the SARS-CoV-2 infection

Meircurius D. SURBOYO<sup>1,2\*</sup>, Diah S. ERNAWATI<sup>1</sup>, Hendrik S. BUDI<sup>2,3</sup>

<sup>1</sup>Department of Oral Medicine, Faculty of Dental Medicine, Airlangga University, Surabaya, Indonesia; <sup>2</sup>Research Center, Faculty of Dental Medicine, Airlangga University, Surabaya, Indonesia; <sup>3</sup>Department of Oral Biology, Faculty of Dental Medicine, Airlangga University, Surabaya, Indonesia

\*Corresponding author: Meircurius D.v Surboyo, Department of Oral Medicine, Faculty of Dental Medicine, Airlangga University, Jln. Prof. Dr. Moestopo N. 47, 60132 Surabaya, Indonesia. E-mail: [meircurius-2015@fkg.unair.ac.id](mailto:meircurius-2015@fkg.unair.ac.id)

### ABSTRACT

**INTRODUCTION:** SARS-CoV-2 develops well in the oral mucosa because, it is the first contact area with the virus. The oral mucosa is highly expressed with angiotensin-converting enzyme 2 (ACE2) and makes the virus replicated in the epithelial cells and produce both oral lesions and oral symptoms. This review aimed to describe the oral mucosal symptoms and lesions related to SARS-CoV-2-infected patients that have been reported around the world.

**EVIDENCE ACQUISITION:** A literature search was performed on PubMed, ScienceDirect and Google Scholar, from February to October 5, 2020, focusing on COVID-19 (SARS-CoV-2) oral lesions and oral symptoms.

**EVIDENCE SYNTHESIS:** Eighteen studies were identified with a total of 25 cases describing the oral symptoms and oral mucosal lesions of the SARS-CoV-2 infection. The oral symptoms related to the SARS-CoV-2 infection included dysgeusia, ageusia, a burning mouth sensation, a dry mouth and severe halitosis. The oral mucosal lesions varied from ulceration and depapillation to pseudomembranous, maculae, nodules and plaque. The mucosal lesions related to the skin lesions were in the form of crusty lips, multiple ulcerations and rashes, targeted lesions, blisters and vesiculobullous lesions.

**CONCLUSIONS:** The manifestations of the SARS-CoV-2 infection in the oral cavity are non-specific. The oral mucosal lesions that occur mimic the *Herpes zoster virus* infection, the *Herpes simplex virus* infection, *Varicella* and hand, foot and mouth disease, and the oral mucosal lesions with the skin manifestations (e.g. erythema multiforme).

(Cite this article as: Surboyo M, Ernawati D, Budi H. Oral mucosal lesions and oral symptoms of the SARS-CoV-2 infection. Minerva Dent Oral Sc 2021;70:000-000. DOI: 10.23736/S2724-6329.21.04493-9)

**KEY WORDS:** Diagnosis; SARS-CoV-2; Skin; Ulcer.

### Introduction

SARS-CoV-2 is believed to exist in saliva, and it develops well in the oral mucosa because the oral cavity is the first area that comes into contact with the virus. The latest evidence shows that SARS-CoV-2 is not only presents in the saliva but also in the salivary glands because the angiotensin-converting enzyme 2 (ACE2) is highly expressed in the salivary glands and the tongue's epithelium.<sup>1,2</sup> Dental procedures are becoming risky because of the existence of SARS-

CoV-2 in saliva, and the virus is able to spread from patient to dentist or patient to patient.<sup>1</sup>

The clinical features of asymptomatic individuals with the SARS-CoV-2 infection have not been well defined. The SARS-CoV-2 infection shows mild symptoms after 14 days of viral shedding, but in the asymptomatic individual viral shedding has a longer period of 19 days.<sup>3</sup> Being the first area to be infected by the virus, it could be hypothesized that oral mucosal lesions could be an onset sign of infection.<sup>4</sup> SARS-CoV-2 has a similar manifestation to other viral infections,

uch as the *Herpes simplex virus*, including its abrupt onset and association with solitary or multiple blisters or ulcerations that can be found in every part of the oral tissue.<sup>5, 6</sup>

During the SARS-CoV-2 pandemic, the social environment changed significantly due to the highly infectious nature of SARS-CoV-2, which can be transmitted through close contact, droplets and aerosols.<sup>7</sup> Many countries affected by the SARS-CoV-2 pandemic were partly or completely locked down for long periods.<sup>7</sup> These conditions can affect emotions and stress and can lead to impaired immune systems, resulting in physiological changes in the oral mucosa and even pathological conditions.<sup>8</sup>

The latest reports from clinicians from across the world refer to the oral manifestations of the SARS-CoV-2 infection. The identification of the oral manifestation of the SARS-CoV-2 infection is important to understand, especially for dentists and oral medicine specialist during intraoral examinations before starting dental treatments. This review aimed to describe the oral mucosal symptoms and oral mucosal lesions in patients with the SARS-CoV-2 infection that have been reported around the world.

## Evidence acquisition

### Research strategy

The Preferred Reported Items for Systematic Review and Meta-Analysis (PRISMA) was used as the guideline for this review. The question for this review was: “What are the oral mucosal lesions and oral symptoms in SARS-CoV-2 patients?”

### Eligibility criteria

This study established the inclusion criteria described below: 1) cases of patients with SARS-CoV-2 with reported oral symptoms and oral mucosal lesions and/or skin lesions, with or without clinical images, in the form of case reports, letters to editors, correspondence, short communications and medical imagery; and 2) articles written in English.

The exclusion criteria: 1) cases of SARS-CoV-2 patients reporting only skin lesions without oral mucosal lesions or only oral symptoms

without oral mucosal lesions; 2) reviews; 3) commentaries and opinions; and 4) studies not published in English.

### Search methodology

A literature search was done using PubMed, ScienceDirect, Google Scholar and Embase, from February 5 to October 5, 2020, using the keywords “COVID-12” (MeSH terms) OR “SARS” (MeSH terms) OR “SARS-CoV-2” (all fields) AND “oral lesions” OR “mucosal lesion” OR “oral mucosa” OR “oral symptoms” and conducted by two independent investigators, MDSC and DSE. In case of disagreements, the investigators reached consensus through discussion.

The articles found in the databases were screened by title and abstract. In the final stage,

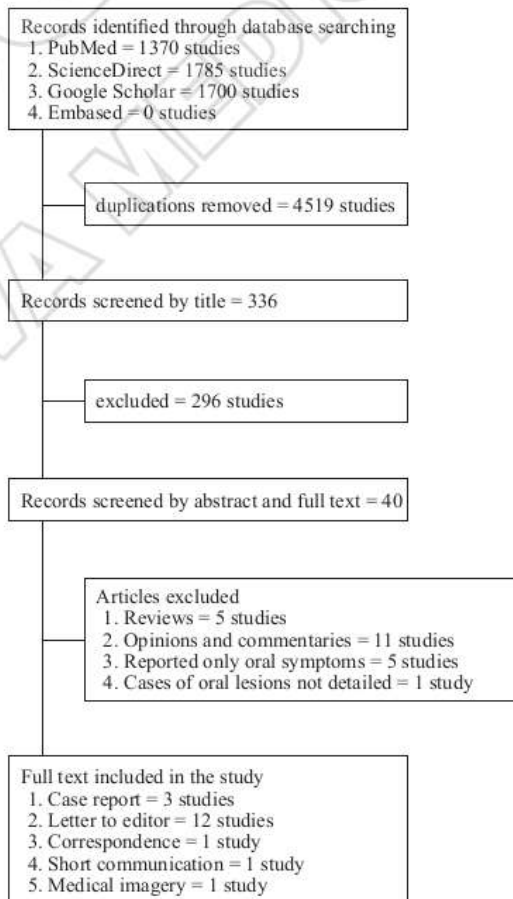


Figure 1.—Schematic strategic research.

the full text was read carefully. The reference lists in each article were scanned for the possibility of a match with the included criteria. The diagram for the search methodology is shown in Figure 1.

## Evidence synthesis

### Study results

We identified 18 studies with a total of 25 cases describing the oral symptoms and oral mucosal lesions in the SARS-CoV-2 infection. Two studies presented the oral symptoms and oral mucosal lesions accompanied by skin lesions. Six studies presented the oral mucosal lesions accompanied by skin lesions. Ten studies presented the oral symptoms only and/or accompanied by oral mucosal lesions.

### Oral symptoms

The oral symptoms related to the SARS-CoV-2 infection included dysgeusia, ageusia, a burning mouth sensation, a dry mouth, hyposmia and severe halitosis (Table I).<sup>9-16</sup>

### Oral mucosal lesions

The oral mucosal lesions in the SARS-CoV-2 infection are not specific. The oral mucosal lesions vary from single and multiple ulcerations, depapilation and pseudomembranous to bullous lesions, nodules, blisters, fissures, macular erythematous, petechiae, desquamative lesions and plaque (Table II).<sup>9, 10, 12-21</sup> The affected mucosal region can be involved in all regions of the oral cavity, such as the buccal mucosa, tongue, gingiva, soft and hard palatal mucosa and tonsils.

### Ulcerative lesions

The most commonly reported oral mucosal lesion was an oral ulceration. It varies from sin-

gle to multiple ulcers and can be distributed bilaterally and unilaterally. The types of ulcer include major and minor aphthous-like ulcers, aphthous-like ulcers covered with a mucopurulent membrane and hemorrhagic ulcers. The affected mucosal region can be involved in all regions of the oral cavity. The gingiva is also affected by manifestations, such as ulceration, bleeding and a generalized erythematous and edematous.

### Depapilation lesions

Tongue depapilation is also reported as oral lesions. The tongue depapilation is localized in the dorsum and lateral parts of the tongue and appears as a severe geographic tongue with localized depapilation.

### Pseudomembranous lesions

Pseudomembranous lesions have been reported as pseudomembranous candidiasis on the dorsum of the tongue.

### Macular lesions

Macular lesions appear as erythematous macular, non-bleeding vascular-like purple maculae, petechiae and whitish spots. Erythematous macular appears on the lateral border of the tongue, the hard palate mucosa, the oropharynx and the tonsils. Non-bleeding vascular-like purple maculae are found on the hard palate mucosa. Petechiae present as erythematous macular in hard and soft palate mucosa and the lateral border of the tongue, while the whitish spots are on the dorsum of the tongue.

### Nodule lesions

Nodule lesions are found on the lower lip of the SARS-CoV-2 patient.

TABLE I.—*Oral symptoms related to SARS-CoV-2.*

Oral manifestation	Reference
Dysgeusia	Díaz Rodríguez <i>et al.</i> ; <sup>9</sup> Carreras-Presas <i>et al.</i> ; <sup>10</sup> Labé <i>et al.</i> ; <sup>11</sup> Brandão <i>et al.</i> ; <sup>12</sup> Glavina <i>et al.</i> ; <sup>13</sup> Tomo <i>et al.</i> ; <sup>14</sup> Cebeci Kahraman <i>et al.</i> <sup>15</sup>
Ageusia	Brandão <i>et al.</i> <sup>12</sup>
Burning mouth sensation	Díaz Rodríguez <i>et al.</i> ; <sup>9</sup> Tomo <i>et al.</i> <sup>14</sup>
Dry mouth	Díaz Rodríguez <i>et al.</i> ; <sup>9</sup> Tomo <i>et al.</i> <sup>14</sup>
Severe halitosis	Patel <i>et al.</i> <sup>16</sup>

TABLE II.—*Oral mucosal lesions related to SARS-CoV-2.*

Oral mucosal lesions	Location	References
Single aphthous-like ulcer	Dorsum of the tongue Peritonsillar	Díaz Rodríguez <i>et al.</i> <sup>9</sup> Brandão <i>et al.</i> <sup>12</sup>
Single ulcer	Lateral of the tongue Ventral of the tongue	Brandão <i>et al.</i> <sup>12</sup>
Multiple aphthous-like ulcers	Lower labial mucosa Upper labial mucosa Dorsum of the tongue Ventral of the tongue	Brandão <i>et al.</i> <sup>12</sup>
Multiple hemorrhagic ulcer	Anterior and dorsum of the tongue	Brandão <i>et al.</i> <sup>12</sup>
Multiple ulceration	Palatine mucosa at the right side Palatine mucosa at the left side Lateral of the tongue Anterior of the tongue Dorsum of the tongue Hard palate mucosa Generalized gingiva	Carreras-Presas <i>et al.</i> <sup>10</sup> Carreras-Presas <i>et al.</i> <sup>10</sup> Brandão <i>et al.</i> ; <sup>12</sup> Corchuelo <i>et al.</i> <sup>17</sup> Ansari <i>et al.</i> <sup>18</sup> Amorim dos Santos <i>et al.</i> <sup>19</sup> Glavina <i>et al.</i> ; <sup>13</sup> Ansari <i>et al.</i> <sup>18</sup> Patel <i>et al.</i> <sup>16</sup>
Tongue depapillation	Dorsum of the tongue Lateral of the tongue	Díaz Rodríguez <i>et al.</i> ; <sup>9</sup> Amorim dos Santos <i>et al.</i> <sup>19</sup> Tomo <i>et al.</i> <sup>14</sup>
Pseudomembranous Petechia	Dorsum of the tongue Hard palate mucosal Lateral of the tongue Soft palate mucosa	Díaz Rodríguez <i>et al.</i> <sup>9</sup> Brandão <i>et al.</i> <sup>12</sup> Tomo <i>et al.</i> <sup>14</sup> <sup>15</sup>
Erythema macular	Lateral of the tongue Oropharynx Hard palate mucosa	Tomo <i>et al.</i> <sup>14</sup> Cebeci Kahraman <i>et al.</i> <sup>15</sup> Cebeci Kahraman <i>et al.</i> ; <sup>15</sup> Amorim dos Santos <i>et al.</i> ; <sup>19</sup> Cruz Tapia <i>et al.</i> <sup>20</sup>
Whitish spot	Tonsil	Amorim dos Santos <i>et al.</i> <sup>19</sup>
Plaque	Dorsum of the tongue Dorsum of the tongue Hard palate mucosa	Corchuelo <i>et al.</i> <sup>17</sup> Amorim dos Santos <i>et al.</i> <sup>19</sup> Cruz Tapia <i>et al.</i> <sup>20</sup>
Nodule	Lower lip	Amorim dos Santos <i>et al.</i> <sup>19</sup>
Bullous	Hard palate mucosa Lateral of the tongue	Cruz Tapia <i>et al.</i> <sup>20</sup> Cruz Tapia <i>et al.</i> <sup>20</sup>

### Plaque lesions

Plaque lesions appear as white plaque and papule plaque on the dorsum of the tongue and the hard palate mucosa.

### Bullous and blistering lesions

The oral manifestation of bullous lesions appears as erythematous bullous and purple bullous, which can be found on the hard palate mucosa and the lateral border of the tongue.

### Oral mucosa and skin lesions

Oral mucosa accompanied by skin lesions are found in SARS-CoV-2 patients (Table III).<sup>10, 11, 22-27</sup> Skin lesions include maculae, plaque, petechiae, vesicles and bullous appearing on the skin. Oral mucosal lesions include ulcer-

ations, erosions, vesicles, bullous, blisters, maculae and the formation of a crust. This manifestation is similar to hypersensitivity or a drug-related eruption and other viral infections, such as the herpes simplex virus, coxsackie and herpangina.

### Discussion

Angiotensin-converting enzyme 2 (ACE2) is a receptor for SARS-CoV-2 that plays a prominent role in causing the infection by enabling the virus to enter cells.<sup>28</sup> Therefore, cells with ACE2 receptors are able to become viral host cells, triggering inflammatory reactions in the tissues. In the oral cavity, ACE2 is highly expressed in the epithelial cells, especially in the tongue and salivary glands.<sup>1,2</sup> This condition may be the reason for the oral manifestation of the SARS-CoV-2 infection.

TABLE III.—*Oral and skin lesions related to SARS-CoV-2.*

Oral mucosal lesions	Location	Skin lesion	References
Vesicles and erosion lesions	Lips Anterior of the tongue Buccal mucosa	Red, edematous papules and plaque involving the dorsal hands and feet	Aghazadeh <i>et al.</i> <sup>22</sup>
Single ulcer	Dorsum of the tongue	Erythematous plane lesion on the left big toe	Chaux-Bodard <i>et al.</i> <sup>23</sup>
Erosions	Lips and buccal mucosa	Red papules and erythema	Sakaida <i>et al.</i> <sup>24</sup>
Multiple ulcerations	Tongue and palatal mucosa	A target lesion distributed over the hands and elbows	Demirbaş <i>et al.</i> <sup>25</sup>
Crusts	Lips	A target lesion on the foot, hand and cheek	Labè <i>et al.</i> <sup>11</sup>
Crusts	Lips	Rash under breasts, on back and in genital area	Carreras-Presas <i>et al.</i> <sup>10</sup>
Multiple blisters	Lower labial mucosa	Generalized exanthemas with desquamation finger desquamation	
Ulceration	Lip and oral mucosal	Petechia-like lesions	Soares <i>et al.</i> <sup>26</sup>
Single ulcer	Buccal mucosa	Vesicle and bullous lesions	
Multiple reddish maculae	Hard palate Tongue Lips		
Erosions and blood crust	Lips	Erythematous maculae, papules and petechiae on the lower extremities	Ciccarese <i>et al.</i> <sup>27</sup>

One of the oral symptoms of SARS-CoV-2 is burning mouth syndrome, which may manifest as a dry mouth and these are strongly correlated with a burning mouth sensation and changes in taste.<sup>29</sup> Dry mouth occurs because the virus binds to the ACE2 receptors in the epithelium of the salivary glands, combining, replicating and lysing the cells to produce noticeable signs and symptoms, such as swelling, discomfort and pain in the salivary glands, as an indication of acute sialadenitis. This process leads to decreased salivary production.<sup>30</sup>

Dysgeusia and ageusia are the most common conditions of altered taste and taste loss. SARS-CoV-2 enters cells by binding with the ACE2 receptors expressed in the oral mucosa, especially tongue epithelia. The virus enters and replicates, which triggers an inflammatory response, leading to cellular changes that change taste.<sup>31</sup> Seven authors explained dysgeusia,<sup>9-15</sup> and one ageusia,<sup>12</sup> as an oral manifestation of SARS-CoV-2. These authors also found that patients with dysgeusia and ageusia have oral lesions as well, such as oral ulcerations and depapilation on the different parts of the oral mucosa.<sup>10, 12, 13</sup> Other oral symptoms were found to be a burning mouth sensation,<sup>9, 14</sup> a dry mouth,<sup>9, 14</sup> hypostomia<sup>12</sup> and severe halitosis.<sup>16</sup> This condition hypothesizes that SARS-CoV-2 can affect the nervous system.<sup>21</sup>

The oral mucosal lesion most commonly

found in SARS-CoV-2 patients is the oral ulceration. Oral ulcerations appear as single and multiple ulcerations on the dorsum,<sup>18</sup> anterior of the tongue,<sup>19</sup> and the gingiva,<sup>16</sup> as with other viral infections. This condition is similar to the *Herpes simplex virus* (HSV) infection in which the ulcers also appear on the mucosa and gingiva. Other clinicians, such as Carreras-Presas *et al.*,<sup>10</sup> have reported the appearance of ulcers only unilaterally in the palatal mucosa. The characteristics is similar to the *Herpes zoster virus* (HZV) infection.<sup>32</sup> Carvalho *et al.*<sup>33</sup> also stated that the lesions that appeared in the unilateral multiple oral ulcers were recurrent herpetic stomatitis, which is more in line with the HZV oral manifestation. The similarity of the clinical appearance of the SARS-CoV-2 infection to HSV and HZV is probably a result of a multi-infection in the oral mucosa or the manifestations of SARS-CoV-2 mimicking HSV and HZV.

Other oral mucosal lesions in SARS-CoV-2 patients were found together with skin lesions. Two cases have a similar clinical appearance with hand, foot and mouth (HFMD) disease. The skin lesion appears as edematous with red papules and plaque involving the dorsal part of the feet and hands,<sup>22</sup> and erythematous lesions also appeared on the big toe.<sup>23</sup> Oral lesions include vesicle and erosion lesions on the lips, the anterior of the tongue and the buccal mucosa<sup>22</sup> and are in the form of a single ulcer.<sup>23</sup> HFMD is an

infectious disease caused by enteroviruses. The initial symptoms are followed by an exanthema of papules with blisters and, eventually, ulcers. Lesions commonly develop in the mouth, including on the hard palate, buccal mucosa, cheek surface, tongue and gums as well as the palms and the soles of the feet.<sup>34</sup>

In one case, there was a single ulcer and multiple maculae on the buccal mucosa, the hard palate, tongue and lips, with skin lesions, petechiae-like lesions, vesicle and bullous lesions.<sup>26</sup> The enticing feature of the petechiae-like lesions may be the varicella-like papulovesicular exanthema as an infrequent, but specific, SARS-CoV-2 skin manifestation.<sup>35</sup> Varicella, or chickenpox, is a very contagious rash disease caused by the *Varicella-Zoster Virus* (VZV), which is transmitted by the inhalation of airborne droplets from subjects with an acute infection or, infrequently, by direct contact with skin lesions in subjects with varicella or zoster. VZV infects T cells and produces subclinical cell-related viremia within 4-6 days of infection. When an antiviral agent is administered, it responds as a viral replication in infected keratinocytes, with the subsequent damage of the cell with immune and inflammatory responses leading to the formation of virion-filled vesicles. This causes a skin rash (exanthema) that appears about two weeks after infection. The rash primarily appears on the trunk with small pruritic maculopapular vesicles that disperse to the neck and limbs. Within 12 to 72 hours the lesions turn into pustules (similar to vesicles but containing purulent material), which often break down and produce scabs.<sup>36</sup>

In four cases presented by Carreras-Presas *et al.*,<sup>10</sup> Sakaida *et al.*,<sup>24</sup> Demirbas *et al.*<sup>25</sup> and Labe *et al.*,<sup>11</sup> a SARS-CoV-2 manifestation on the oral mucosa and skin lesions were reported as a hypersensitivity reaction similar to erythema multiforme and a drug-related eruption. The oral mucosal lesion included multiple blisters on the lower labial mucosa,<sup>10</sup> with an erosion on the lip and buccal mucosa<sup>24</sup> and crusty lips.<sup>11, 25</sup> The skin lesions included a rash,<sup>10</sup> papules<sup>24</sup> and a targeted lesion.<sup>11, 25</sup> This condition is compatible with a hypersensitivity reaction like erythema multiforme. Erythema multiforme is caused by a

cell-mediated immunity response, and an infection is associated with 90% of cases. HSV type 1 is the most commonly identified etiology of this disease. Erythema multiforme lesions usually begin with red papules and develop into plaque. Mucosal lesions are found in 25% to 60% of patients with erythema multiforme. Prodromal weakness, fever and malaise are common symptoms in sufferers with mucosal involvement. Even though the most commonly affected area is the oral mucosa, the genital and ocular mucosa can also develop lesions.<sup>37</sup>

All the oral mucosal and skin lesions may be associated with SARS-CoV-2, but the exact mechanism and pathological mechanism are not well explained. The conditions described above may be related to an immunosuppression condition in SARS-CoV-2 combined with stress and lack of nutritional support. In SARS-CoV-2, the human body produces excess cytokines, which is known as a cytokine storm. *In-vitro* studies show that, at the early stages of the SARS-CoV-2 infection, there is a delayed release of chemokines and cytokines in dendritic cells, respiratory epithelial cells and macrophages. Subsequently, the cells secrete high levels of chemokines (C-C motif chemokine ligand [CCL]-5, CCL-3, and CCL-2) and proinflammatory cytokines (tumor necrosis factor [TNF], interleukin [IL]-1 $\beta$  and IL-6), while they also secrete low numbers of the antiviral interferons (IFN). IFN expression is the main natural response of immune defense against viral infections, and IFN-I is the primary molecule that plays an antiviral role in the early stages of a viral infection. The delayed release of IFN in the early stages of the SARS-CoV-2 infection impedes the body's antiviral response.<sup>38, 39</sup> Meanwhile, the tissue damage mediated by the immune response is caused by CD8<sup>+</sup> T cells, which are highly cytotoxic by nature in the body. In addition, the immune response in SARS-CoV-2 patients is abnormally biased towards the immunosuppressive Th-2, a reciprocation with the functionally depleted T cells to increase the expression of inhibitory factors such as PD-1, which results in an immune dysfunction.<sup>40</sup> This condition could increase the host's exposure to a secondary infection.

The SARS-CoV-2 manifestation is currently

not well defined. The manifestations in the oral cavity and on the skin can take a form similar to HSV, HZV, HFMD and even varicella. This might occur as the inflammation progresses into systemic inflammatory response syndrome (SIRS). In SIRS, cytokines looping through the circulation system cause increased capillary permeability. Increased capillary permeability will decrease the blood volume caused by plasma deposition in the tissue space. This condition then leads to multisystem organ failure. In this condition, various manifestations, including in the oral cavity and on the skin, can occur due to the inflammatory process, especially in subjects with immunodeficiency.<sup>41</sup>

### Conclusions

In conclusion, there are several manifestations of the SARS-CoV-2 infection in the oral cavity, and these manifestations are non-specific. Thus, it is currently difficult to ascertain which specific oral mucosal lesions are directly related to SARS-CoV-2. To date, the oral mucosal lesions that have been reported as occurring in SARS-CoV-2 patients mimic HSV, HZV, varicella and HFMD, and the oral mucosal lesions with skin manifestations are similar to erythema multiforme. However, further studies and appropriate investigations are needed to confirm this.

### References

- Xu J, Li Y, Gan F, Du Y, Yao Y. Salivary Glands: Potential Reservoirs for COVID-19 Asymptomatic Infection. *J Dent Res* 2020;99:989–989.
- Xu H, Zhong L, Deng J, Peng J, Dan H, Zeng X, *et al.* High expression of ACE2 receptor of 2019-nCoV on the epithelial cells of oral mucosa. *Int J Oral Sci* 2020;12:8.
- Long QX, Tang XJ, Shi QL, Li Q, Deng HJ, Yuan J, *et al.* Clinical and immunological assessment of asymptomatic SARS-CoV-2 infections. *Nat Med* 2020;26:1200–4.
- Petrescu N, Lucaciu O, Roman A. Oral mucosa lesions in COVID-19. *Oral Dis* 2020. [Epub ahead of print]
- Santosh AB, Muddana K. Viral infections of oral cavity. *J Family Med Prim Care* 2020;9:36–42.
- Vieira AR. Oral manifestations in coronavirus disease 2019 (COVID-19). *Oral Dis* 2021;27(Suppl 3):770.
- Chakraborty I, Maity P. COVID-19 outbreak: Migration, effects on society, global environment and prevention. *Sci Total Environ* 2020;728:138882.
- Guo Y, Yuan C, Wei C. Emergency measures for acute oral mucosa diseases during the outbreak of COVID-19. *Oral Dis* 2021;27(Suppl 3):737–9.
- Díaz Rodríguez M, Jiménez Romera A, Villarreal M. Oral manifestations associated with COVID-19. *Oral Dis* 2020. [Epub ahead of print]
- Martín Carreras-Presas C, Amaro Sánchez J, López-Sánchez AF, Lázaro-Salas E, Somacarrera Pérez ML. Oral vesiculobullous lesions associated with SARS-CoV-2 infection. *Oral Dis* 2021;27(Suppl 3):710–2.
- Labé P, Ly A, Sin C, Nasser M, Chapelon-Fromont E, Ben Said P, *et al.* Erythema multiforme and Kawasaki disease associated with COVID-19 infection in children. *J Eur Acad Dermatol Venereol* 2020;34:e539–41.
- Brandão TB, Gueiros LA, Melo TS, Prado-Ribeiro AP, Nesrallah AC, Prado GV, *et al.* Oral lesions in patients with SARS-CoV-2 infection: could the oral cavity be a target organ? *Oral Surg Oral Med Oral Pathol Oral Radiol* 2021;131:e45–51.
- Glavina A, Biočina-Lukenda D, Mravak-Stipetić M, Markeljević J. Oral symptoms and lesions in SARS-CoV-2-positive patient. *Oral Dis* 2020. [Epub ahead of print]
- Tomo S, Miyahara GI, Simonato EE. Oral mucositis in a SARS-CoV-2-infected patient: secondary or truly associated condition? *Oral Dis* 2020. [Epub ahead of print]
- Cebeci Kahraman F, Çaşkırlı H. Mucosal involvement in a COVID-19-positive patient: A case report. *Dermatol Ther (Heidelb)* 2020;33:e13797.
- Patel J, Woolley J. Necrotizing periodontal disease: oral manifestation of COVID-19. *Oral Dis* 2021;27(Suppl 3):768–9.
- Corchuelo J, Ulloa FC. Oral manifestations in a patient with a history of asymptomatic COVID-19: case report. *Int J Infect Dis* 2020;100:154–7.
- Ansari R, Gheitani M, Heidari F, Heidari F. Oral cavity lesions as a manifestation of the novel virus (COVID-19). *Oral Dis* 2021;27(Suppl 3):771–2.
- Amorim Dos Santos J, Normando AG, Carvalho da Silva RL, De Paula RM, Cembranel AC, Santos-Silva AR, *et al.* Oral mucosal lesions in a COVID-19 patient: new signs or secondary manifestations? *Int J Infect Dis* 2020;97:326–8.
- Cruz Tapia RO, Peraza Labrador AJ, Guimaraes DM, Matos Valdez LH. Oral mucosal lesions in patients with SARS-CoV-2 infection. Report of four cases. Are they a true sign of COVID-19 disease? *Spec Care Dentist* 2020;40:555–60.
- Payus AO, Liew Sat Lin C, Mohd Noh M, Jeffrey MS, Ali RA. SARS-CoV-2 infection of the nervous system: A review of the literature on neurological involvement in novel coronavirus disease-(COVID-19). *Bosn J Basic Med Sci* 2020;20:283–92.
- Aghazadeh N, Homayouni M, Sartori-Valinotti JC. Oral vesicles and acral erythema: report of a cutaneous manifestation of COVID-19. *Int J Dermatol* 2020;59:1153–4.
- Chaux-Bodard AG, Deneuve S, Desoutter A. Oral manifestation of Covid-19 as an inaugural symptom? *J Oral Med Oral Surg* 2020;26:18.
- Sakaida T, Tanimoto I, Matsubara A, Nakamura M, Morita A. Unique skin manifestations of COVID-19: is drug eruption specific to COVID-19? *J Dermatol Sci* 2020;99:62–4.
- Demirbaş A, Elmas ÖF, Atasoy M, Türsen Ü, Lotti T. A case of erythema multiforme major in a patient with COVID 19: the role of corticosteroid treatment. *Dermatol Ther (Heidelb)* 2020;33:e13899.
- Soares C, Carvalho R, Carvalho K, Carvalho M, Almeida O. Letter to Editor: Oral lesions in a patient with Covid-19. *Med Oral Patol Oral y Cir Bucal.* 2020;25(4):563–4.



27. Ciccarese G, Drago F, Boatti M, Porro A, Muzic SI, Parodi A. Oral erosions and petechiae during SARS-CoV-2 infection. *J Med Virol* 2021;93:129–32.
28. Zhou P, Yang XL, Wang XG, Hu B, Zhang L, Zhang W, *et al.* A pneumonia outbreak associated with a new coronavirus of probable bat origin. *Nature* 2020;579:270–3.
29. Biadsee A, Biadsee A, Kassem F, Dagan O, Masarwa S, Ormianer Z. Olfactory and Oral Manifestations of COVID-19: Sex-Related Symptoms-A Potential Pathway to Early Diagnosis. *Otolaryngol Head Neck Surg* 2020;163:722–8.
30. Wang C, Wu H, Ding X, Ji H, Jiao P, Song H, *et al.* Does infection of 2019 novel coronavirus cause acute and/or chronic sialadenitis? *Med Hypotheses* 2020;140:109789.
31. Lozada-Nur F, Chainani-Wu N, Fortuna G, Sroussi H. Dysgeusia in COVID-19: Possible Mechanisms and Implications. *Oral Surg Oral Med Oral Pathol Oral Radiol* 2020;130:344–6.
32. Ballyram R, Wood N, Khammissa R, Lemmer J, Feller L. Oral diseases associated with human herpes viruses: Aetiology, clinical features, diagnosis and management. *S Afr Dent J* 2016;71:253–9.
33. de Carvalho LF, Kitakawa D, Cabral LA, Carvalho LF das C e S. Oral lesions of herpes zoster in COVID-19 patients or truly associated to the disease? *Oral Dis* 2021;27(Suppl 3):774–5.
34. Aswathyraj S, Arunkumar G, Alidjinou EK, Hober D. Hand, foot and mouth disease (HFMD): emerging epidemiology and the need for a vaccine strategy. *Med Microbiol Immunol (Berl)* 2016;205:397–407.
35. Marzano AV, Genovese G, Fabbrocini G, Pigatto P, Monfrecola G, Piraccini BM, *et al.* Varicella-like exanthem as a specific COVID-19-associated skin manifestation: multicenter case series of 22 patients. *J Am Acad Dermatol* 2020;83:280–5.
36. Freer G, Pistello M. Varicella-zoster virus infection: natural history, clinical manifestations, immunity and current and future vaccination strategies. *New Microbiol* 2018;41:95–105.
37. Traves KP, Love G, Studdiford JS. Erythema multiforme: recognition and management. *Am Fam Physician* 2019;100:82–8.
38. Ye Q, Wang B, Mao J. The pathogenesis and treatment of the 'Cytokine Storm' in COVID-19. *J Infect* 2020;80:607–13.
39. Zabetakis I, Lordan R, Norton C, Tsoupras A. COVID-19: The Inflammation Link and the Role of Nutrition in Potential Mitigation. *Nutrients* 2020;12:1466.
40. Maggo S, Dhull P, Dubey AP, Brashier D, Karan A, Singh NK, *et al.* Cytokine Storm Syndrome in COVID-19: Diagnosis and Management Strategies. *Int J Health Sci Res* 2020;10:140–9.
41. Hussain A, Kaler J, Tabrez E, Tabrez S, Tabrez SS. Novel COVID-19: A Comprehensive Review of Transmission, Manifestation, and Pathogenesis. *Cureus* 2020;12:e8184.

*Conflicts of interest.*—The authors certify that there is no conflict of interest with any financial organization regarding the material discussed in the manuscript.

*Authors' contributions.*—Meircurius D. Surboyo have given substantial contributions to study conception and design, literature search, data collection, organization, analysis and interpretation, and manuscript writing, Diah S. Ernawati to data collection, organization, analysis and interpretation, and manuscript revision, Hendrik S. Budi to study design, data interpretation and manuscript revision. All authors read and approved the final version of the manuscript.

*History.*—Article first published online: \_\_\_\_\_, - Manuscript accepted: January 19, 2021. - Manuscript revised: January 18, 2021. - Manuscript received: December 8, 2020.

# Oral mucosal lesions and oral symptoms of the SarS-coV-2 infection

## ORIGINALITY REPORT

15%

SIMILARITY INDEX

15%

INTERNET SOURCES

11%

PUBLICATIONS

%

STUDENT PAPERS

## PRIMARY SOURCES

1	<a href="http://www.esp.org">www.esp.org</a> Internet Source	4%
2	<a href="http://hdl.handle.net">hdl.handle.net</a> Internet Source	3%
3	Gizem S. Erbaş, Aysenur Botsali, Nihan Erden, Canan Arı, Banu Taşkın, Sibel Alper, Secil Vural. "COVID - 19 - related oral mucosa lesions among confirmed SARS - CoV - 2 patients: a systematic review", International Journal of Dermatology, 2021 Publication	1%
4	<a href="http://journals.plos.org">journals.plos.org</a> Internet Source	1%
5	<a href="http://www.umd.pt">www.umd.pt</a> Internet Source	1%
6	<a href="http://www.frontiersin.org">www.frontiersin.org</a> Internet Source	1%
7	<a href="http://jofs.in">jofs.in</a> Internet Source	1%

8	Juliette Rochefort, Anne Gaelle Chaux. "Oral mucosal lesions and Covid-19: symptoms and/or complication?", Journal of Oral Medicine and Oral Surgery, 2021 Publication	1 %
9	<a href="https://pdfs.semanticscholar.org">pdfs.semanticscholar.org</a> Internet Source	<1 %
10	<a href="https://pubmed.ncbi.nlm.nih.gov">pubmed.ncbi.nlm.nih.gov</a> Internet Source	<1 %
11	<a href="http://www.mdpi.com">www.mdpi.com</a> Internet Source	<1 %
12	LP Samaranayake, KS Fakhruddin, H C Ngo, HMHN Bandara, YY Leung. "Oro-facial Mycoses in Coronavirus Disease-2019 (COVID-19): A Systematic Review", International Dental Journal, 2022 Publication	<1 %
13	<a href="http://www.ijss-sn.com">www.ijss-sn.com</a> Internet Source	<1 %
14	Abanoub Riad, Islam Kassem, Jan Stanek, Mai Badrah, Jitka Klugarova, Miloslav Klugar. " Aphthous stomatitis in - 19 patients: Case - series and literature review ", Dermatologic Therapy, 2021 Publication	<1 %
15	<a href="http://hrjournal.net">hrjournal.net</a> Internet Source	<1 %

---

Exclude quotes Off  
Exclude bibliography On

Exclude matches < 10 words

# Oral mucosal lesions and oral symptoms of the SarS-coV-2 infection

---

## GRADEMARK REPORT

---

FINAL GRADE

**/0**

GENERAL COMMENTS

**Instructor**

---

PAGE 1

---

PAGE 2

---

PAGE 3

---

PAGE 4

---

PAGE 5

---

PAGE 6

---

PAGE 7

---

PAGE 8

---