



ISSN 0019-5595

# Indian Journal of ORTHOPAEDICS

Roots of Responsibility. Wings of Professional Excellence



 Springer

# Editors

## **Editor**

Lalit Maini

## **Associate Editors**

Rehan UI Haq

Murali Poduval

Srinivas Kambhampati

## **Assistant Editors**

Raju Vaishya

Bhavuk Garg

Sujit Tripathy

Shivam Sinha

Ashish Gulia

Amit Kumar Agarwal

Basant Kumar Bhuyan

Rajesh Kumar Rohilla

Hitesh Lal

Praveen Sarda

Ashok Shyam

## **Chief Advisor**

AK Jain

**Past Editor**

Ish Dhammi

**Section Editors****Shoulder & Elbow**

Tarun Goyal

Praveen Sarda

DP Bakshi

Anand Arya (UK)

Marius M Scarlat (France)

Minoo Patel (Australia)

**Hand**

Alock Agrawal

Basant K Bhuyan

J Terrence Jose

Ted Mah (Australia)

Karthik Vishwanathan

Amitabha Lahiri Singapore

Sunil Choudhary India

**Hip**

Vivek Trikha

Rajiv Thukral

Sudhir Babhulkar

Vikas Khanduja (UK)

Venu Kavarthapu (UK)

**Knee**

Ujwal Debnath

Saurabh Jain

Parag Sancheti

Sidharth M Shah

Jegan Krishnan (Australia)

**Foot & Ankle**

Vinod Panchbhavi (USA)

MS Dhillon

Maninder Shah

Abdul Q Khan

**Oncology**

Ashish Gulia

SS Yadav

Mayil Natrajan

Sudhir Kapoor

Aditya Maheshwari (USA)

**Paediatric**

Mandar V Agashe

Shakti Das

Ashok N Johari

HS Sandhu

Shivam Sinha

**Spine**

Bhavuk Garg

Kshitij Choudhary

Naresh Babu J

Keith D Luk (HongKong)

Dilip Sengupta (USA)

**Arthroscopy & Sports**

Amit Kr Agrawal

Saseendar S

P Gopinathan

Arun GR

Samir Dwidmuthe

**Arthroplasty**

Rajesh Malhotra

Sujit Tripathy

Rohit Rambani (UK)

Anoop C. Dhamangaonkar

**Trauma**

Ashok Gavaskar

Yogesh Salphale

Cyril Mauffrey (USA)

Rajesh P Dharia

**Infection**

Hitesh Lal

Zile Singh Kundu

SM Tuli

AK Jain

Kamal Bose (Singapore)

**Education & statistics**

Ashok Shyam

Mohit Bhandari (Canada)

DK Taneja

Anant Mahapatra (Ireland)

### **Biomedical Engineering**

Raju Vaishya

Abhishek Kashyap

Boyko Gueorguiev (Swiss)

Friedrich Baumgaertel (Germany)

Abhishek Kashyap

### **Health Policy & Administration**

Murali Poduval

Shantaram Shetty

Sudhir Kumar

S Rajasekaran

### **Reconstruction & Ilizarov**

Rajesh Rohilla

Milind Chowdhary

CP Pal

Leonid Solomin (Russia)

### **Biomaterial & Basic Science**

Ujjwal Debnath

SC Goel

Shivam Sinha

### **Biostatistics**

Mohit P

Krishna V

### **Editorial Board**

S. Saseendar

## Table of Content



### Volume 55, issue 1, February 2021

31 articles in this issue

#### Presidential Address

R. C. Meena

Presidential Address | Published: 21 January 2021 | Pages: 1 - 2



#### Save the Hip–Hip Surveillance in Cerebral Palsy is the Need of the Hour!!

Ashok N. Johari

Editorial | Published: 01 February 2021 | Pages: 3 - 4

#### Save the Hip–Hip Surveillance in Cerebral Palsy is the Need of the Hour!!

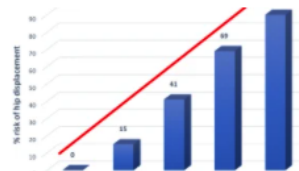
Ashok N. Johari

Editorial | Published: 01 February 2021 | Pages: 3 - 4

#### Hip Displacement in Cerebral Palsy: The Role of Surveillance

Alaric Aroojis, Nihit Mantri & Ashok N. Johari

Review Article | Published: 11 June 2020 | Pages: 5 - 19



#### Suspension of Hip Surveillance for Children with Cerebral Palsy During the COVID-19 Outbreak: The Benefit of Hip Surveillance Does Not Outweigh the Risk of Infection

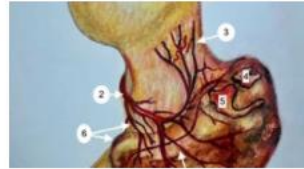Stacey Miller, Jeffrey Bone & Kishore Mulpuri

Review Article | Published: 28 August 2020 | Pages: 20 - 22

## Fractures of the Proximal Femur in Childhood: A Review

Deepika A. Pinto & Alaric Aroojis

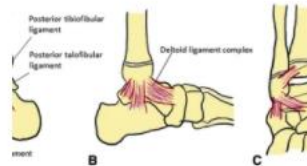Review Article | Published: 18 September 2020 | Pages: 23 - 34



## Paediatric Ankle Fractures: Guidelines to Management

K. Venkatadass, G. Sangeet ... S. Rajasekaran

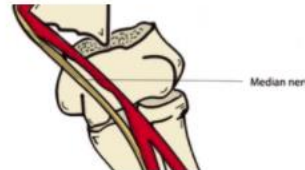Review Article | Published: 06 October 2020 | Pages: 35 - 46



## The Pulseless Supracondylar Elbow Fracture: A Rational Approach

Samir Sabharwal, Adam Margalit ... Sanjeev Sabharwal

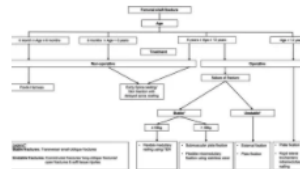Review Article | Published: 13 October 2020 | Pages: 47 - 54



## Pediatric Femoral Shaft Fracture: An Age-Based Treatment Algorithm

Glen Zi Qiang Liao, Hong Yi Lin ... James Hoi Po Hui

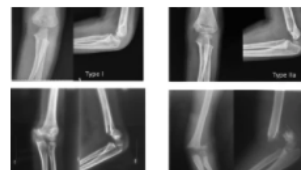
Review Article | Published: 10 October 2020 | Pages: 55 - 67



## Supracondylar Humerus Fractures: Classification Based Treatment Algorithms

Mudit Shah & Mandar Vikas Agashe

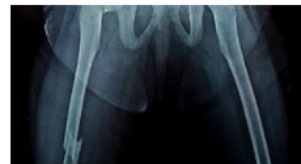
Review Article | Published: 22 October 2020 | Pages: 68 - 80



## Dilemma for Fracture Fixation of Paediatric Ipsilateral Neck with Shaft Femur Fracture

Jaswinder Singh & John Mukhopadhaya

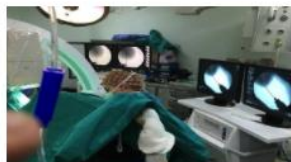Review Article | Published: 13 January 2021 | Pages: 81 - 92





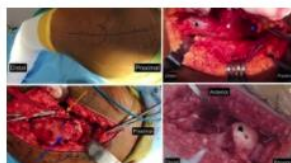
## Procedural Outcomes of Double Vs. Single Fluoroscopy for Fixing Supracondylar Humerus Fractures in Children: A Case–Control Study

Burak Gunaydin, Ali Turgut ... Yavuz Selim Kabukcuoglu  
Original Article | Published: 31 May 2020 | Pages: 93 - 99



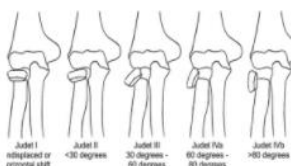
## Modified Dunn Osteotomy for Moderate and Severe Slipped Capital Femoral Epiphysis – A retrospective study of thirty hips

Mandar V. Agashe, Deepika A. Pinto & Sandeep Vaidya  
Original Article | Published: 03 June 2020 | Pages: 100 - 108



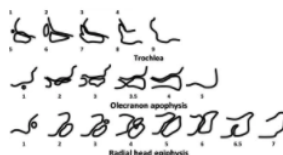
## Close Reduction Technique for Severely Displaced Radial Neck Fractures in Children

Maulin M. Shah, Gaurav Gupta ... Kemble K. Wang  
Original Article | Published: 04 July 2020 | Pages: 109 - 115



## Usefulness of the Sauvegrain Method of Bone Age Assessment in Indian Children

Premal Naik, Dhren Ganjwala ... Kranti Suresh Vora  
Original Article | Published: 02 July 2020 | Pages: 116 - 124



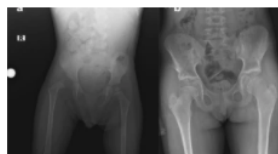## A Practical Method for Obtaining True Lateral Elbow X-rays in a Paediatric Age Group: Lateral Elbow X-ray in the Standing Salute Position

Mehmet Burtaç Eren, Murat Aşçı ... Tahir Öztürk  
Original Article | Published: 27 August 2020 | Pages: 125 - 129



## A Comparative Study of Clinical and Radiological Outcomes of Open Reduction Using the Anterior and Medial Approaches for the Management of Developmental Dysplasia of the Hip

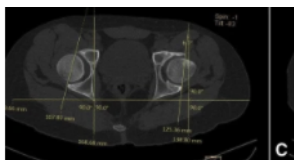
Omer Naci Ergin, Mehmet Demirel ... Fuat Bilgili  
Original Article | Published: 20 June 2020 | Pages: 130 - 141



## Is the Acetabulum Retroverted in SCFE? A Study of Acetabular Morphology in Indian Children with SCFE

K. Venkatadass, S. Muthukumar ... S. Rajasekaran

Original Article | Published: 15 June 2020 | Pages: 142 - 146



## Swaddling Practices in an Indian Institution: Are they Hip-Safe? A Survey of Paediatricians, Nurses and Caregivers

Deepika A. Pinto, Alaric Aroojis & Rujuta Mehta

Original Article | Published: 08 July 2020 | Pages: 147 - 157



## Developmental Dysplasia of the Hip: An Examination of Care Practices of Orthopaedic Surgeons in India

Nikki Hooper, Alaric Aroojis ... Kishore Mulpuri

Original Article | Published: 20 August 2020 | Pages: 158 - 168

## The Association Between *BMP-2*, *UQCC1* and *CX3CR1* Polymorphisms and the Risk of Developmental Dysplasia of the Hip

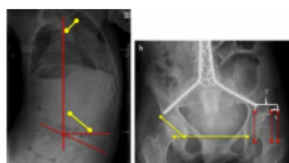
Evren Gumus, Ebru Temiz ... Ataman Gonel

Original Article | Published: 29 August 2020 | Pages: 169 - 175

## The Impact of Spinal Fusion on Hip Displacement in Cerebral Palsy

Mutlu Cobanoglu, Brian Po-Jung Chen ... Freeman Miller

Original Article | Published: 09 October 2020 | Pages: 176 - 182



## Prospective Study of Gross Motor Milestones in Children with Severe Idiopathic Clubfoot Treated by Ponseti Method

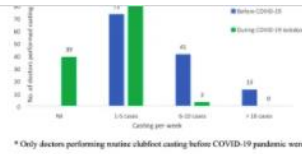
Chaitrali Shrikant Gundawar, Sameer Shrikrishna Desai ... Amrut V. Oswal

Original Article | Published: 27 July 2020 | Pages: 183 - 187

## Changes in the Management of Clubfoot Cases During COVID-19 Pandemic—A Survey Among Orthopaedic Specialists

Karthick Rangasamy, Rujuta Mehta ... Mandeep S. Dhillon

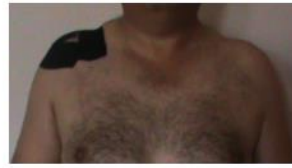Original Article | Published: 06 October 2020 | Pages: 188 - 194



## Comparison of Kinesiotaping, Exercise and Subacromial Injection Treatments on Functionality and Life Quality in Shoulder Impingement Syndrome: A Randomized Controlled Study

Ozge Vergili, Birhan Oktas & Ibrahim Deniz Canbeyli

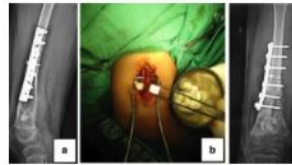
Original Article | Published: 11 June 2020 | Pages: 195 - 202



## Lengthening of Massive Intercalary Cortical Allograft After Successful Graft Incorporation in Skeletally Immature Bone with Critical-Sized Defect: A Case Report with 6-year Follow-up

Ferdiansyah Mahyudin, Kuku Dwiputra Hernugrahanto ... Heri Suroto

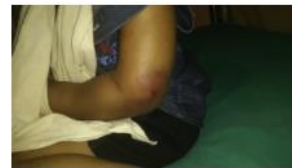Case Report | Published: 24 March 2020 | Pages: 203 - 207



## Anterior Physeal Separation of Distal Humerus: Report of a Rare Case with Review of Literature

Deny Kurien Mathew, Sangeet Gangadharan ... Rajasekaran Shanmughanathan

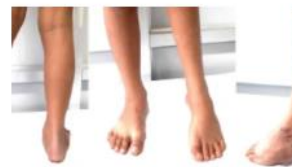Case Report | Published: 23 April 2020 | Pages: 208 - 212



## Ilizarov Frame Application Based on Ponseti Principles for Clubfoot Correction: A Case Report and Description of Surgical Technique

Nirmal Raj Gopinathan, Karthick Rangasamy ... Pebam Sudesh

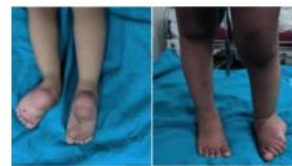Case Report | Published: 03 June 2020 | Pages: 213 - 218



## Congenital Posterior Dislocation of Fibula with Pes Valgus Deformity

Alok Chandra Agrawal & Shilp Verma

Surgical Technique | Published: 31 July 2020 | Pages: 219 - 223



## 'Return to the New Normal': Innovative Solutions for Safe Ponseti Casting in Clubfoot Clinics during the COVID-19 Pandemic

Alaric Aroojis & Vigneshwaran Pragadeeswaran

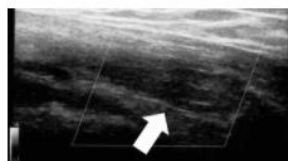
Surgical Technique | Published: 10 October 2020 | Pages: 224 - 229



## Tietze Syndrome and Malposition

Hiroshi Ito

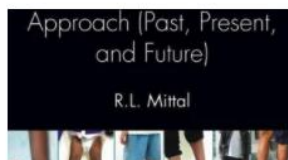
Letter to the Editor | Published: 28 July 2020 | Pages: 230 - 231



## R.L. Mittal: CLUBFOOT—A Comprehensive Approach (Past, Present, and Future)

Ashok N. Johari & Farokh Wadia

Book Review | Published: 12 October 2020 | Pages: 232 - 233





# Lengthening of Massive Intercalary Cortical Allograft After Successful Graft Incorporation in Skeletally Immature Bone with Critical-Sized Defect: A Case Report with 6-year Follow-up

Ferdiansyah Mahyudin<sup>1</sup> · Kuku Dwiputra Hernugrahanto<sup>1</sup> · Jeffrey Andrianus<sup>1</sup> · Lukas Widhiyanto<sup>1</sup> · Mouli Edward<sup>1</sup> · Heri Suroto<sup>1</sup>

Received: 21 January 2020 / Accepted: 6 March 2020

© Indian Orthopaedics Association 2020

## Abstract

Bone allograft serves as an alternative to overcome the limitation of autograft. Some concerns, such as graft rejection, infection, and low union rate, arise from the use of bone allograft since the graft is a non-living and foreign material. We reported a case of critical-sized bone defect in a skeletally immature patient treated with massive intercalary allograft that not only did it show union but also graft incorporation that allowed for subsequent bone lengthening at the site of the incorporated massive allograft. To our knowledge, there has been a report of lengthening of free-vascularized fibular autograft but not the nonvascularized one. Massive intercalary allograft that incorporates well to the host could be an option to treat critical-sized bone defect.

**Keywords** Massive intercalary allograft · Bone lengthening · Critical-sized defect

**MeSH Terms** Massive · Intercalary · Allograft · Lengthening · Critical-sized · Defect

## Introduction

Autologous bone grafting remains the gold standard to treat bone defect, but its limited supply deems bone allograft more feasible for critical-sized defect [1]. Issues like graft rejection and low union rate arise from the use of bone allograft since it is a non-living material [2, 3]. We reported a case of critical-sized bone defect treated with massive intercalary allograft. Not only did it show union but also complete graft incorporation that allowed for subsequent bone lengthening at the site of the allograft. To our knowledge, there has been a report of lengthening of free-vascularized autograft but not the nonvascularized massive allograft.

## Case History

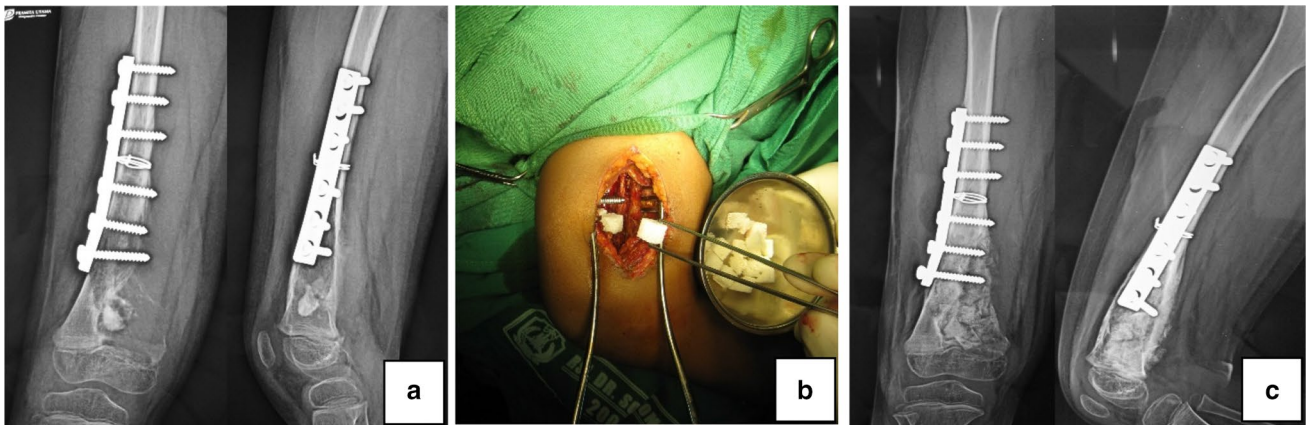
A 10-year-old boy had suffered from right distal femoral fracture and underwent an internal fixation in a remote district hospital. Following the surgery, he was referred to our hospital after an intraoperative finding suggested a haemangioma lesion. Neither CT scan nor MRI had been performed prior to the operation to suggest the presence of haemangioma. Biopsy specimen was taken during the internal fixation surgery in the district hospital. The histopathologic result confirmed the finding of haemangioma. The patient was then scheduled for curettage of the lesion and bone grafting using freeze-dried cancellous bone allograft (Fig. 1).

Six months following the curettage and bone grafting, we observed clearly from the plain x-ray that the lesion continued to expand, and the grafts were resorbed. The expansion also involved the physis distally. The patient was then scheduled for another curettage, but this time bone cement was used instead of bone allograft (Fig. 2).

After 6-month of close follow-up, the patient was 11 years old then, no sign of recurrence was found. The patient underwent another surgery to reconstruct the defect (Fig. 3). Firstly, the bone cement was removed. Upon removal of the

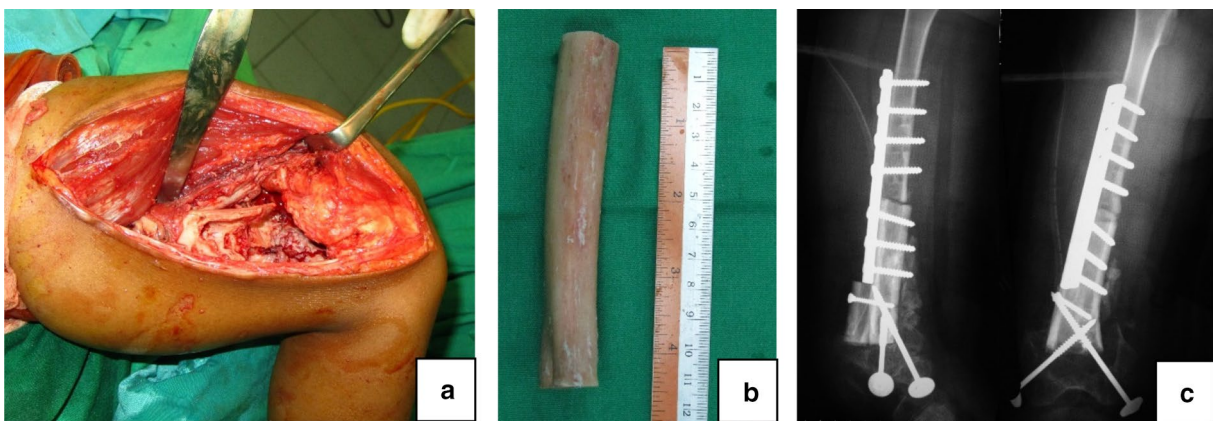
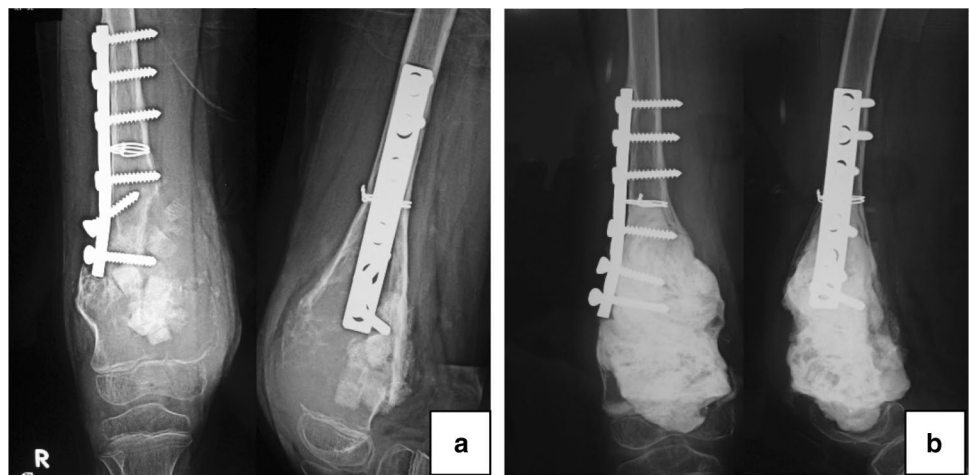✉ Ferdiansyah Mahyudin  
ferdiansyah@fk.unair.ac.id

<sup>1</sup> Orthopedic and Traumatology Department, Faculty of Medicine, Universitas Airlangga/Dr. Soetomo General Hospital, Jalan Mayjend Prof. Dr. Moestopo No. 6-8, Surabaya, East Jawa, Indonesia



**Fig. 1** The patient was 10 years old: **a** initial X-ray image from the previous hospital suggested a well-demarcated lesion in the distal metaphysis of the right femur; **b** curettage and bone grafting using cancellous bone allograft; **c** postoperative X-ray image after curettage and bone grafting Source: internal documentation

**Fig. 2** Six months after the first curettage: **a** The lesion continued to expand. Distally, it damaged the physics. Another curettage was needed; **b** second curettage and application of bone cement to fill the defect Source: internal documentation



**Fig. 3** Six months after the second curettage. The patient was 11 years old: **a** critical-sized defect of 10 cm was found; **b** massive intercalary bone allograft was used; **c** the bone graft was inserted and fixed Source: internal documentation

bone cement, intraoperative evaluation did not find any sign of recurrent hemangioma lesion, but a critical-sized bone defect

of 10 cm was found. It was decided to use massive intercalary fresh-frozen bone allograft. The bone allograft had been

procured through careful screening of donor and processed in our hospital tissue bank according to the standard protocols of American Association of Tissue Bank (AATB), European Association of Tissue Bank (EATB), and Asia Pacific Association of Surgical Tissue Bank (APASTB) to ensure the safety and quality of the allograft.

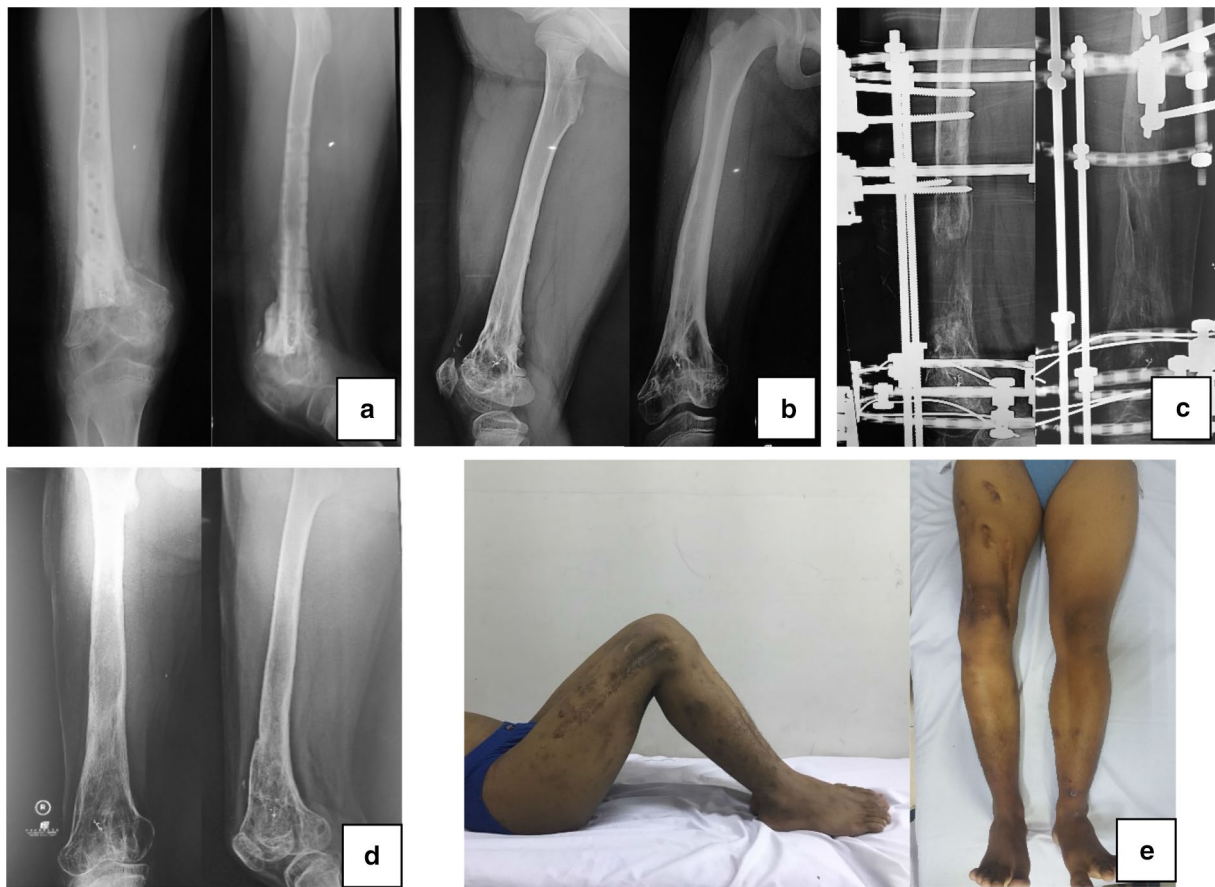The patient was closely followed up to evaluate any clinical and radiological sign of recurrence, graft rejection, graft failure, infection, fracture, or nonunion. Neither of the sign was found in the patient. After 2 years, the radiological evaluation showed graft union and incorporation. The patient was 13 years old then. Clinical examination found that there was leg-length discrepancy of 2 cm. It was decided to remove all internal fixation and continue to do close observation until the patient passed the period of rapid growth to allow any remaining leg discrepancy to occur. After 3 years of observation, the patient was 16 years old, the leg-length discrepancy increased to 8 cm by then. Limb lengthening procedure was necessary to restore the length of the shortened limb. Gradual lengthening using Ilizarov's distraction osteogenesis was preferred. Osteotomy of the meta-diaphyseal area at the site of the previous intercalary bone allograft with meticulous preservation of the surrounding periosteum and soft tissue was done followed by application of a ring fixator. Seven-day delay was done to allow osteogenesis before starting distraction. We followed the Ilizarov's optimum distraction rule of "one millimeter a day" although in the actual practice the rate of the distraction was adjusted according to the patient's pain assessment and the progress of radiological callus formation. The lengthening procedure was carried out under close monitoring until both limbs achieved equal length. On average, the external fixation index (EFI) was 21.25 days/cm. After a year, equal length with complete radiological union was achieved, and the fixator was removed. Neither clinical nor radiological sign of pin tract infection was observed. We performed close follow-up every 6 months after the last operation to monitor any occurrence of late discrepancy or additional deformity. Although there was residual 5° varus deformity of the right knee found during the 6-month follow-up, the patient was satisfied with his condition. He was able to walk painlessly without limp and to perform daily activity (Fig. 4). According to the Association for the Study and Application of Methods of Ilizarov (ASAMI) outcome criteria, the patient achieved excellent result in both radiological and clinical criteria [4]. The patient was planned for future corrective osteotomy for the varus deformity.

## Discussion

The decision to use bone allograft in this case was due to the massive defect size in which autologous graft would not be sufficient to fill. Intercalary cortical graft was chosen since the defect required structural support. Some concerns arise

from the use of bone allograft. Several studies reported the complication of bone allograft in critical-sized segmental bone defect. Bullens reported that out of 32 patients undergone reconstruction with massive structural allografts, the fracture rate, infection rate, and union rate after five-year followed up were 13%, 16%, and 25% respectively [5]. Another report from 78 cases with average follow up of 37.9 months by Zheng showed that there were 18 cases (23%) of local rejections, 4 cases (5%) of infection, 5 cases (6.5%) of nonunion [6]. Companacci et al. assessed the long-term results of pediatric osteoarticular allografts after massive resection in 13 distal femoral and 12 proximal tibial tumors. They concluded that allograft mechanical failure was the most important complication, which occurred in 12 cases (60%) [7]. Fracture occurs in about 16% of massive allografts and is usually seen two years after implantation [8]. No finding of infection, graft rejection, fracture, and nonunion was found in this patient. The clinical and radiological evaluation also showed good graft union and incorporation. The complications that occurred were limb shortening and varus deformity.

Stevenson has studied the factors affecting bone graft incorporation. Bone graft incorporation requires the process of revascularization, new bone formation, and host-graft union [9]. The incorporation process of a bone allograft usually occurs at the host-graft junctions since the process is the result of creeping substitution that replaces the allograft with newly formed bone. The nonvascularized massive bone allograft is poorly remodeled which causes the central part of the graft distant from the host-graft junctions to be almost non-viable even after several years of implantation [10]. This makes the allograft entirely dependent on the surrounding tissue for its revascularization. Therefore, the condition of perigraft environment is very important. In this reported case, to prevent any adverse immunologic reaction between the host and the graft, the allograft had been processed under strict standard protocol of AATB, EATB, and APASTB. After allograft implantation, any clinical signs of graft rejection were observed and recorded. No rejection sign was found. The patient was a skeletally immature 10-year old boy. The still-growing pediatric bone provides stronger and thicker periosteum that might have contributed to better revascularization and bone healing, which resulted in good graft incorporation. We performed meticulous and careful handling of the periosteum and the surrounding soft tissues in every stage of the surgery to ensure that the periosteum and the surrounding soft tissues were well preserved. Since infection might also cause poor union rate, we exercised strict monitoring for any sign of pin tract infection both clinically and radiologically. Daily pin sites cleaning, and good personal hygiene were carried out by the patient. In addition, to protect and facilitate the incorporation between the graft and the host bone, optimum mechanical environment



**Fig. 4** **a** Two years after the graft implantation, 13 years old: good graft incorporation and union. Length discrepancy was two centimeters; **b** after 3 years of observation, 16 years old: the graft was fully incorporated. Leg length discrepancy increased to 8 cm; **c** limb

lengthening using Ilizarov's distraction osteogenesis. Osteotomy at the level of meta-diaphyseal junction; **d** one year of lengthening procedure, 17 years old; **e** equal length of both limbs Source: internal documentation

is necessary. This requires stable fixation of the graft using ring fixator [9, 11].

Bone defect in skeletally immature patients often leave the patients with residual leg length discrepancy. Distraction osteogenesis offers an additional therapeutic. According to Ilizarov, the requirements for an optimal result of bone lengthening are minimally traumatic osteotomies preferably located in a metaphysis, solid mechanical fixation across osteotomies, an adequate latency period before lengthening, and sufficient time for callus to mature [12]. Han Jo Kim assess the safety and efficacy of limb reconstruction using Ilizarov's distraction osteogenesis method following treatment of a range of benign and malignant bony conditions. The living bone regenerated in distraction osteogenesis will eventually provide sufficient biomechanical strength, stability, and durability. In growing children, leg-length discrepancies may be corrected by distraction osteogenesis after they have matured [13]. Ilizarov showed that formation of new bone at the osteotomy site is definitely influenced by the amount of damage to the bone, medullary cavity, and

periosteum. Since regeneration of medullary vessels will only occur after 7–10 days following a complete osteotomy, the most important factor for new bone formation at the site of the osteotomy is the integrity of the periosteum [9, 12]. Therefore, we performed careful preservation of the periosteum during the osteotomy to ensure good periosteum cuff around the osteotomy site. For the lengthening to succeed, a period of delay between osteotomy and distraction must be carried out to allow osteogenesis. In an adolescent patient, we consider that 7 days were long enough to allow initial callus formation. Ilizarov suggests one-milimeter-a-day rule for optimum distraction. Several studies on bone distraction in nonunion cases suggested various external fixation index from 1 to 3 months per centimeter gained. As far as our concern, there is still no published reference for distraction rate in allograft. Therefore, we followed the original rule by Ilizarov with some adjustment based on the patient condition and the radiological progress of callus formation. After equal length was achieved, close observation was carried out to monitor complete union, and any residual discrepancy



or deformity. To our knowledge, there has been a report of lengthening of free-vascularized fibular autograft but not the non-vascularized one. The reported case showed successful bone lengthening of the incorporated non-vascularized massive intercalary allograft. This shows that in skeletally immature bone, the graft might achieve complete incorporation to allow subsequent lengthening.

## Conclusion

Optimum perigraft condition that includes infection-free environment, well-preserved periosteum, stable fixation, and proper distraction technique, will facilitate good incorporation and subsequent lengthening of allograft in skeletally-immature bone.

**Author Contributions** Concepts: FM, HS. Design: FM, KDH, JA, LW, ME. Definition of intellectual content: FM, KDH, JA, LW, ME. Literature search: FM, KDH, JA, LW, ME. Clinical studies: FM, KDH, JA, LW, ME. Experimental studies: FM, KDH, JA, LW, ME. Data acquisition: FM, KDH, JA, LW, ME. Data analysis: FM, HS. Statistical analysis: FM, HS. Manuscript preparation: FM, KDH, HS. Manuscript editing: FM, KDH, HS. Manuscript review: FM, KDH, HS. Guarantor: FM, KDH, JA, LW, ME, HS.

**Funding** This research did not receive any specific grant from funding agencies in the public, commercial, or not-for-profit sectors so this research was fully funded personally.

## Compliance with Ethical Standards

**Conflicting interest** No conflict of interest in this study.

**Ethical standard statement** All procedures performed in studies involving human participants were in accordance with the ethical standards of the institutional and/or national research committee and with the 1964 Helsinki declaration and its later amendments or comparable ethical standards.

**Informed consent** Informed consent was obtained from the patient for publication of this case report and accompanying images.

## References

1. Utomo, D. N., Hernugrahanto, K. D., Edward, M., Widhiyanto, L., & Mahyudin, F. (2019). International Journal of Surgery Case

- Reports Combination of bone marrow aspirate, cancellous bone allograft, and platelet-rich plasma as an alternative solution to critical-sized diaphyseal bone defect: A case series. *International Journal of Surgery Case Reports*, 58, 178–185.
2. Wang, W., & Yeung, K. W. K. (2017). Bioactive Materials Bone grafts and biomaterials substitutes for bone defect repair: A review. *Bioactive Materials*, 2(4), 224–247.
3. Goldberg, V. M., & Akhavan, S. (2005). Biology of bone grafts. In J. R. L. G. E. Friedlaender (Ed.), *Bone Regeneration and Repair: Biology and Clinical Applications* (pp. 57–65). Totowa: Humana Press Inc.
4. Paley, D., Catagni, M. A., Argnani, F., Villa, A., Benedetti, G. B., Cattaneo, R., et al. (1989). Ilizarov treatment of tibial nonunions with bone loss. *Clinical Orthopaedics and Related Research*, 241, 146–165.
5. Bullens, P. H. J., Minderhoud, N. M., de Waal Malefijt, M. C., Veth, R. P. H., Buma, P., & Schreuder, H. (2009). Survival of massive allografts in segmental oncological bone defect reconstructions. *International Orthopaedics*, 33, 757–760.
6. Zheng, X.-F., Huang, H.-Y., Ding, H.-W., Zhang, Y., & Yin, Q.-S. (2009). Reconstruction of bone defects with massive bone allograft for bone tumor treatment in 78 cases. *Journal of Clinical Rehabilitative Tissue Engineering Research*, 9(13), 2978–2983.
7. Jamshidi, K., & Bahrabadi, M. M. A. (2017). Long-term results of osteoarticular allograft reconstruction in children with distal femoral bone tumors. *Archives of Bone and Joint Surgery*, 5, 296–301.
8. Delloye, C., Cornu, O., Druetz, V., & Barbier, O. (2007). Bone allografts. What they can offer and what they cannot. *The Journal of Bone and Joint Surgery B*, 89(5), 574–579.
9. Stevenson, S., Emery, S. E., & Goldberg, V. M. (1996). Factors affecting bone graft incorporation. *Clinical Orthopaedics and Related Research*, 323, 66–74.
10. Delloye, C. (2003). How to improve the incorporation of massive allografts? *La Chirurgia Degli Organi di Movimento*, 88(4), 335–343.
11. Lindaman, L. (2001). Bone healing in children. *Clinics in Podiatric Medicine and Surgery*, 18(1), 97–108.
12. Hvid, I., Horn, J., Huhnstock, S., & Steen, H. (2016). The biology of bone lengthening. *Journal of Children's Orthopaedics*, 10(6), 487–492.
13. Frisoni, T., Cevolani, L., Giorgini, A., & Dozza, B. D. D. (2012). Factors affecting outcome of massive intercalary bone allografts in the treatment of tumours of the femur. *The Journal of Bone and Joint Surgery*, 94-B, 836–841.