




# Procedia

## Chemistry



### **Molecular and Cellular Life Sciences: Infectious Diseases, Biochemistry and Structural Biology 2015 Conference**

*Editors:*

**Toshihiro Kase  
Gongy Kuroda  
Marie Inge Lervik  
David M. Edwards  
Richard Dixon**

Available online at [www.elsevier.com/locate/procedia](http://www.elsevier.com/locate/procedia)  
**ScienceDirect**

# **International Seminar on Molecular and Cellular Life Sciences 2015 (MCLS 2015)**

Procedia Chemistry Volume 18

Surabaya, Indonesia  
7 - 8 May 2015

## **Editors:**

**Toshiharu Hase  
Genji Kurisu  
Maria Inge Lusida**

**Bauke W. Dijkstra  
Nicholas Dixon**

ISBN: 978-1-5108-2070-8

**Printed from e-media with permission by:**

Curran Associates, Inc.  
57 Morehouse Lane  
Red Hook, NY 12571



**Some format issues inherent in the e-media version may also appear in this print version.**

Copyright© by Elsevier B.V.  
All rights reserved.

Printed by Curran Associates, Inc. (2016)

For permission requests, please contact Elsevier B.V.  
at the address below.

Elsevier B.V.  
Radarweg 29  
Amsterdam 1043 NX  
The Netherlands

Phone: +31 20 485 3911  
Fax: +31 20 485 2457

<http://www.elsevierpublishingsolutions.com/contact.asp>

**Additional copies of this publication are available from:**

Curran Associates, Inc.  
57 Morehouse Lane  
Red Hook, NY 12571 USA  
Phone: 845-758-0400  
Fax: 845-758-2634  
Email: [curran@proceedings.com](mailto:curran@proceedings.com)  
Web: [www.proceedings.com](http://www.proceedings.com)

# TABLE OF CONTENTS

<b>PREFACE</b> .....	1
<i>Maria Inge Lusida</i>	
<b>STRUCTURE AND CATALYTIC MECHANISM OF 3-KETOSTEROID DEHYDROGENASES</b> .....	3
<i>Bauke W. Dijkstra, Niels Van Oosterwijk, Ali Rohman</i>	
<b>EXTRACELLULAR ENZYMES PRODUCED BY VIBRIO ALGINOLYTICUS ISOLATED FROM ENVIRONMENTS AND DISEASED AQUATIC ANIMALS</b> .....	12
<i>Supansa Bunpa, Natthawan Sermwittayawong, Varaporn Vuddhakul</i>	
<b>RECOMBINANT LIPL32 PROTEIN FOR LEPTOSPIROSIS DETECTION IN INDONESIA</b> .....	18
<i>Sumarningsih, Simson Tarigan, Susanti, Kusmiyati</i>	
<b>ENHANCING STABILITY AND PURITY OF CRUDE CHITINASE OF ACHATINA FULICA BY CRYSTALLIZATION</b> .....	26
<i>Afaf Baktir, Nira Ambar Arum, Suyanto, Bambang Suprijanto</i>	
<b>APPLICATION OF CASSAVA PEEL AND WASTE AS RAW MATERIALS FOR XYLOOLIGOSACCHARIDE PRODUCTION USING ENDOXYLANASE FROM BACILLUS SUBTILIS OF SOIL TERMITE ABDOMEN</b> .....	31
<i>Anak Agung Istri Ratnadewi, Agung Budi Santoso, Erma Sulistyarningsih, Wuryanti Handayani</i>	
<b>MUTATION ANALYSIS OF THE PK<sub>a</sub> MODULATOR RESIDUE IN B-D-XYLOSIDASE FROM GEOBACILLUS THERMOLEOVORANS IT-08: ACTIVITY ADAPTATION TO ALKALINE AND HIGH-TEMPERATURE CONDITIONS</b> .....	39
<i>Lanny Hartanti, Ali Rohman, Ami Suwandi, Bauke W. Dijkstra, Zeily Nurahman, Ni Nyoman Tri Puspaningsih</i>	
<b>AUTOLYTIC ISOLATION OF CHITIN FROM WHITE SHRIMP (PENAUES VANNAMEI) WASTE</b> .....	49
<i>Achmad Sjaifullah, Agung Budi Santoso</i>	
<b>EFFECTS OF FERMENTATION AND STORAGE ON BIOACTIVE ACTIVITIES IN MILKS AND YOGHURTS</b> .....	53
<i>Irma Sarita Rahmawati, Worapot Suntornsuk</i>	
<b>SCANNING ELECTRON MICROSCOPE ANALYSIS OF RICE STRAW DEGRADATION BY A TREATMENT WITH A-L-ARABINOFURANOSIDASE</b> .....	63
<i>Anita Kurniati, Handoko Darmokoesoemo, Ni Nyoman Tri Puspaningsih</i>	
<b>SECRETION OF GEOBACILLUS THERMOLEOVORANS IT-08 <math>\alpha</math>-L-ARABINOFURANOSIDASE (ABFA) IN SACCHAROMYCES CEREVISIAE BY FUSION WITH HM-1 SIGNAL PEPTIDE</b> .....	69
<i>I Nengah Wirajana, Tetsuya Kimura, Kazuo Sakka, Eddy Bagus Wasito, Soekry Erfan Kusuma, Ni Nyoman Tri Puspaningsih</i>	
<b>HYDROLYSIS OF CORNCOB XYLAN USING <math>\beta</math>-XYLOSIDASE GBTXYL43B FROM GEOBACILLUS THERMOLEOVORANS IT-08 CONTAINING CARBOHYDRATE BINDING MODULE (CBM)</b> .....	75
<i>Ni Nyoman Purwani, Handoko Darmokoesoemo, Ni Nyoman Tri Puspaningsih</i>	
<b>BIOCHEMICAL POTENTIAL OF <math>\alpha</math>-L-ARABINOFURANOSIDASE AS ANTI-TUBERCULOSIS CANDIDATE</b> .....	82
<i>One Asmarani, Much Zaenal Fanani, Ni Nyoman Tri Puspaningsih</i>	
<b>SHORTENING OF AMINO ACIDS FROM C-TERMINAL OF PZASE AS BASIS OF PYRAZINAMIDE RESISTANCE IN P14 ISOLATE OF MYCOBACTERIUM TUBERCULOSIS STRAIN</b> .....	90
<i>Purkan, Redianti Galuh Novarizka, Rizka Aziz Ayuningsih, Presty Nurdiana, Wiwin Retnowati</i>	
<b>ELIMINATION OF SCMV (SUGARCANE MOZAIK VIRUS) AND RAPID PROPAGATION OF VIRUS-FREE SUGARCANE (SACCHARUM OFFICINARUM L.) USING SOMATIC EMBRYOGENESIS</b> .....	96
<i>Parawita Dewanti, Laily Ilman Widuri, Choirul Ainiyati, Purnama Okviandari, Maisaro, Bambang Sugiharto</i>	
<b>ANTIMICROBIAL ACTIVITIES AND IN SILICO ANALYSIS OF METHOXY AMINO CHALCONE DERIVATIVES</b> .....	103
<i>Hery Suwito, Ni' Matuzahroh, Alfinda Novi Kristanti, Salwa Hayati, Selva Rosyta Dewi, Ilma Amalina, Ni Nyoman Tri Puspaningsih</i>	
<b>POTENTIAL APPLICATION OF OLEYLAMINE-ENCAPSULATED AGINS<sub>2</sub>-ZNS QUANTUM DOTS FOR CANCER CELL LABELING</b> .....	112
<i>Mochamad Zakki Fahmi, Jia-Yaw Chang</i>	

<b>MACROPHAGE ACTIVITY AND CAPACITY FOLLOWING ORAL ADMINISTRATION OF COCOA EXTRACT TO MICE</b> .....	122
<i>Ariza Budi Tunjung Sari, Teguh Wahyudi, Misnawi, Diana Chusna Mufida, I Wayan Suardita</i>	
<b>THE ROLE AND EFFICIENCY OF AMMONIUM SULPHATE PRECIPITATION IN PURIFICATION PROCESS OF PAPAIN CRUDE EXTRACT</b> .....	127
<i>Maria Goretti M. Purwanto</i>	
<b>ISOLATION AND ANTIBACTERIAL ACTIVITY TEST OF LAURIC ACID FROM CRUDE COCONUT OIL (COCOS NUCIFERA L.)</b> .....	132
<i>Febri Odel Nitbani, Jumina, Dwi Siswanta, Eti Nurwening Solikhah</i>	
<b>EFFECT OF BUTYRIC ACID ON P53 EXPRESSION AND APOPTOSIS IN COLON EPITHELIAL CELLS IN MICE AFTER TREATED WITH 9,10-DIMETHYL-1,2-BENZ(A)ANTHRACENE</b> .....	141
<i>Cherry Siregar, Eddy Bagus Wasito, I Ketut Suidiana</i>	
<b>DEEP EUTECTIC SOLVENT (DES) AS A PRETREATMENT FOR OIL PALM EMPTY FRUIT BUNCH (OPEFB) IN SUGAR PRODUCTION</b> .....	147
<i>Nur Atikah Md Nor, Wan Aida Wan Mustapha, Osman Hassan</i>	
<b>PRETREATMENT OF OIL PALM EMPTY FRUIT FIBER (OPEFB) WITH AQUEOUS AMMONIA FOR HIGH PRODUCTION OF SUGAR</b> .....	155
<i>Nursyafiqah Zulkiple, Mohamad Yusuf Maskat, Osman Hassan</i>	
<b>ANTIBACTERIAL ACTIVITY OF PYROGALLOL, A POLYPHENOL COMPOUND AGAINST VIBRIO PARAHAEOLYTICUS ISOLATED FROM THE CENTRAL REGION OF THAILAND</b> .....	162
<i>Tran Huu Tinh, Taiyeebah Nuidate, Varaporn Vuddhakul, Channarong Rodkhum</i>	
<b>ANTIHEPATITIS C VIRUS ACTIVITY OF ALECTRYON SERRATUS LEAVES EXTRACT</b> .....	169
<i>Lidya Tumewu, Evhy Apryani, Mei Ria Santi, Tutik Sri Wahyuni, Adita Ayu Permanasari, Myrna Adianti, Chie Aoki, Aty Widyawaruyanti, Achmad Fuad Hafid, Maria Inge Lusida, Soetjipto, Hak Hotta</i>	
<b>TOXICITY TEST N-HEXANE: ETHYL ACETATE (3:7) FRACTION OF SUDAMALA (ARTEMISIA VULGARIS L.)</b> .....	174
<i>Ira Arundina, S. Theresia Indah Budhy, Intan Nirwana, Retno Indrawati, Muhammad Luthfi</i>	
<b>ACTIVITIES OF FICUS FISTULOSA LEAVE EXTRACT AND FRACTIONS AGAINST HEPATITIS C VIRUS</b> .....	179
<i>Achmad Fuad Hafid, Adita Ayu Permanasari, Lidya Tumewu, Myrna Adianti, Chie Aoki, Aty Widyawaruyanti, Soetjipto, Maria Inge Lusida, Hak Hotta</i>	
<b>CHARACTERIZATION OF TRYPTOPHANASE FROM VIBRIO CHOLERAЕ O1</b> .....	185
<i>Taiyeebah Nuidate, Natta Tansila, Kanda Panthong, Varaporn Vuddhakul</i>	
<b>CURCUMINOID PREVENTS PROTEIN OXIDATION BUT NOT LIPID PEROXIDATION IN EXERCISE INDUCED MUSCLE DAMAGE MOUSE</b> .....	190
<i>Bambang Purwanto, Harjanto, I. Ketut Suidiana</i>	
<b>THE CORRELATION BETWEEN PULMONARY FUNCTION TESTS AND THE SALIVARY MMP-9 ACTIVITY AMONG CHRONIC OBSTRUCTIVE PULMONARY DISEASE (COPD) PATIENTS</b> .....	194
<i>Mulyadi, Sunnati, Mulkan Azhary</i>	
<b>MULTIPLE INTRACRANIAL TUBERCULOMAS: DIAGNOSIS DIFFICULTIES IN A CLINICAL CASE</b> .....	199
<i>Evita Mayasari, Sufida</i>	
<b>STUDY OF TREE-SPARROW (PASSER MONTANUS) AS NATURAL SPREADER OF H5N1 VIRUS</b> .....	205
<i>Emmanuel Djoko Poetranto, Anna Lystia Poetranto, Aldise Mareta Natri, Adhitya Yoppy Ro Candra, Edith Frederika Puruhito, Laksmi Wulandari, Resti Yudhawati, Landia Setiawati, Retno Asih Setyoningrum, Yusuke Takahara, Hak Hotta, Yasuko Mori, Kazufumi Shimizu</i>	
<b>THE EFFECT OF SPIRULINA AS FEED ADDITIVE TO MYOCARDIAL NECROSIS AND LEUKOCYTE OF CHICKEN WITH AVIAN INFLUENZA (H5N1) VIRUS INFECTION</b> .....	213
<i>Widya Paramita Lokapirnasari, Andreas Berny Yulianto, Djoko Legowo, Agustono</i>	
<b>POTENCY OF ATTENUATED EIMERIA TENELLA IN PROTECTIVE IMMUNITY INDUCTION ON HOMOLOGOUS AND HETEROLOGOUS CHALLENGES</b> .....	218
<i>Muchammad Yunus, Endang Suprihati</i>	
<b>SEQUENCE ANALYSIS OF THE GENE REGION ENCODING ESAT-6, AG85B, AND AG85 C PROTEINS FROM CLINICAL ISOLATES OF MYCOBACTERIUM TUBERCULOSIS</b> .....	225
<i>Ni Made Mertaniasih, Didik Handijatno, Agnes Dwi Sis Perwitasari, Desak Nyoman Surya Suameitria Dewi, Much Zaenal Fanani, Ika Qurrotul Afifah</i>	
<b>DETECTION OF MYCOBACTERIUM LEPRAE IN FORMALIN-FIXED PARAFFIN-EMBEDDED SAMPLE BY FITE-FARACO STAINING AND POLYMERASE CHAIN REACTION</b> .....	231
<i>Willy Sandhika, Dinar Adriaty, Indropo Agusni</i>	

**IMMUNOGENICITY AND SPECIFICITY OF ANTI RECOMBINANT PROTEIN FIM-C-SALMONELLA TYPHIMURIUM ANTIBODY AS A MODEL TO DEVELOP TYPHOID VACCINE** .....

237

*Muktiningsih Nurjayadi, Dea Apriyani, Umar Hasan, Imam Santoso, Fera Kurniadewi, Irma Ratna Kartika, Kurnia Agustini, Fernita Puspasari, Dessy Natalia, Wibowo Mangunwardoyo*

**Author Index**



Molecular and Cellular Life Sciences: Infectious Diseases, Biochemistry and Structural Biology  
2015 Conference, MCLS 2015

## Potency of Attenuated *Eimeria tenella* in Protective Immunity Induction on Homologous and Heterologous Challenges

Muchammad Yunus<sup>a\*</sup>, Endang Suprihati<sup>a</sup>

<sup>a</sup>Department of Veterinary Parasitology, Faculty of Veterinary Medicine Airlangga University, C campus Unair, Mulyorejo Street Surabaya  
60115, Indonesia

---

### Abstract

The aim of this study was to know the protective immunity of broilers immunized with attenuated *Eimeria tenella* (*E. tenella*) on homologous and heterologous challenges. The protective immunity was represented by oocyst production and histopathological changes of cecum. The previous experiment already produced attenuated *E. tenella* through serial passages of precocious lines in naive chicken. Four groups of chickens were separately divided into two non-immunized control groups and two immunized with attenuated *E. tenella* groups, and each group was challenged with homologous and heterologous strains. The results showed significant difference in oocysts production ( $p < 0.01$ ) and histopathological changes between control and immunized groups.

© 2016 The Authors. Published by Elsevier B.V. This is an open access article under the CC BY-NC-ND license  
(<http://creativecommons.org/licenses/by-nc-nd/4.0/>).

Peer-review under responsibility of the organizing committee of the Molecular and Cellular Life Sciences: Infectious Diseases,  
Biochemistry and Structural Biology 2015 (MCLS 2015)

**Keywords:** attenuated *E. tenella*; protective immunity; homologous; heterologous

---

---

\* Corresponding author. Tel.: +62-81357335095, +62-31-5992785; fax: +62-31-5993015  
E-mail address: [muhyunus\\_99@yahoo.com](mailto:muhyunus_99@yahoo.com)

## 1. Introduction

The World Health Organisation has now recommended restrictions in the type of antimicrobials used in food-producing animals, livestock development and disease control. The consequence of this withdrawal for the poultry industry in Indonesia is reduction of productivity due to an increased incidence of infection by certain pathogens. This restriction of the use of antibiotic is necessarily anticipated with appropriate substitutes for prophylactic and cure antibiotics to microorganisms infection.

Faced with these restrictions, the use of vaccine to control infectious disease is expected to be able to avoid dependence upon the use of antibiotic and other chemical agents. Moreover the use of vaccine is safer and more natural, effective and efficient to enhance resistance and to obstruct the development of infectious agent. One of potential vaccine materials that has been explored is live vaccine of oocysts that can be developed, produced and applied in mass quantity.

The development of live vaccine using low-virulence precocious lines of oocysts of *Eimeria* can be used as an alternative for more efficient and effective protection and cost compared to other avian coccidiosis vaccines, such as killed and/or sub unit vaccine. Previous study stated that low-virulence precocious lines of oocysts of *Eimeria* could result in serial passage precocious lines of oocysts *Eimeria* at naive chicken. That evidence showed that pathogenicity of *Eimeria* can be attenuated by modification of prepatent period of life cycle of parasite and it is hoped to become a stage for induction of protective immunity in chicken. In fact there are many coccidiosis cases present in several poultry farms due to *E. tenella* infection.

Therefore prevention and/or protection program of cecal coccidiosis is needed using low-virulence precocious lines of oocysts *E. tenella*. This is very beneficial particularly for protection and economical value if vaccination program is performed by using *E. tenella*, a pathogen that frequently attacks many poultry farms.

The previous experiment already produced attenuated *E. tenella* through serial passages of precocious lines in naive chicken. Live vaccines using low-virulence precocious lines of the parasites are expected to be efficient and cost-effective. To be effective, low-virulence precocious lines of the parasites (attenuated *E. tenella*) must exhibit potency of protective immunity in chicken particularly on the challenge of homologous and heterologous strain.

## 2. Methods

Precocious lines of *E. tenella* was to be developed incorporation in an efficacious live vaccine, attenuation of parent strain of *E. tenella* with modification of the prepatent period by serial passage for precocious development to result in *E. tenella* live vaccine which has characterization of potency of protection against homologous and heterologous challenges.

All birds used in this work were CP707 strain, which were supplied from the minimal diseases breeding flock on-site at the Animal Research Institute. Day-old chicks were transferred to positive pressure isolator in a designated clean chicken rearing room, which was isolated from all experimental areas. Strict bio-security procedures were in place and appropriate staff training was completed to ensure no contamination of the coccidian-free birds would occur. Feces from the isolators were monitored weekly to ensure no coccidial infections were present. The birds were reared to at least three weeks of age before they were removed and used for parasite work.

Low-virulence precocious lines of the parasites, attenuated local isolate *E. tenella* were used to immunize naive chickens.

Animals used in these experiments were forty male CP707 strain broilers at two weeks old which were divided into four groups and each group consisted of ten broilers. All broilers at each group adapted during 7 days and were placed in individual battery cages and given standard diet (Charoen Pockphand) that did not contain coccidiostat. All broilers were given food and drink ad libitum. After adaptation, the first and second group were administered with distilled water and they were then challenged with  $1 \times 10^4$  un-attenuated homologous (parent strain) and heterologous of *E. tenella* strain respectively two weeks later. The first two groups were positive control groups of homologous strain and heterologous strain. The third and fourth group were administered with  $1 \times 10^4$  attenuated homologous (precocious lines of *E. tenella* of parent strain) and they were then challenged with  $1 \times 10^4$  un-attenuated homologous (parent strain) and heterologous of *E. tenella* strain respectively two weeks later.

After challenge infection, half of chickens in each group were sacrificed on day 4 for histopathological examination on both macroscopic and microscopic changes. Macroscopic examination of the changes was made by looking at the score of cecal lesion while the microscopic change was made to see the development of intracellular



parasites in each chicken group using HE staining<sup>1</sup>. The other half of chickens in each group were observed on clinical symptoms that began after infection. The total production of the observations made on days 7-12 after infection using the flotation method and calculated using the New McMaster Chamber. All the above procedures were performed on all chickens groups both positive control groups and administered with precocious lines of *E. tenella* groups.

Microscopic changes occurring included the development of intracellular parasites as many as per 10 crypts of Lieberkuhn<sup>2</sup> using a microscope with a magnification of 400 times. The pattern of daily oocyst production will describe patterns of daily oocyst production and subsequent total will describe the level of protective immunity development of the host after immunization and the challenge.

Data on clinical symptoms and the development of intracellular parasites as a result of infection with *E. tenella* were analyzed with comparative and descriptive analysis for each chicken group. Macroscopic examination data in the form of the cecal lesion scores were analyzed by Kruskal-Wallis One Way Test. Total production of oocysts and the number of intracellular parasites that evolved from each chicken group was analyzed using t test<sup>3</sup>.

### 3. Results and discussion

#### 3.1. Clinical symptoms and histopathological changes

The administration of precocious line of *E. tenella* on naïve chicken group that were then challenged using homologous parent strain and heterologous of *E. tenella* showed that both almost similar that is there was no up to light clinical symptoms. In contrast, there was significant difference between administered with precocious line of *E. tenella* (immunized attenuated *E. tenella*) groups and positive control groups. On the one hand, the positive control groups showed obvious clinical symptoms such as diarrhea that began on the fourth day after challenge which became more progressive and accompanied by the presence of blood. Depression, anorexia and weakness were visible on those chickens. These conditions were seen until the tenth day after infection. On the other hand, immunized with precocious line of *E. tenella* groups showed a slight decrease on appetite and had watery stool.

Based on microscopic observations on the cecum, histopathologic damage scores were obtained which included inflammatory cells, degeneration, necrosis hemorrhage, and damage to the mucosa of the cecum as shown in Table 1 and Fig. 2.

Table 1. Comparison of score of histopathological changes between administered precocious line chicken groups (Immunized chicken groups) and positive control groups

Treatment groups	Means ± SD
The 1 <sup>st</sup> group	3.34 <sup>a</sup> ± 0.01
The 2 <sup>nd</sup> group	3.41 <sup>a</sup> ± 0.42
The 3 <sup>rd</sup> group	1.34 <sup>b</sup> ± 0.42
The 4 <sup>th</sup> group	1.22 <sup>b</sup> ± 0.31

Superscript is different in same column represented significantly difference (p<0.05)

Statistical analysis using the Kruskal-Wallis test showed significant difference (p < 0.05) between positive control groups and immunized chicken groups. Cecal damage score was high at positive control groups showing high pathogenicity in chickens that had not been administered with precocious line of *E. tenella*. In contrast, the group that had already been administered with precocious line of *E. tenella* and then challenged with homologous and heterologous strains showed a lower lesion scores than positive control group. Therefore, there was significant decline of histopathological damage of cecum (Table. 2). From the observation on the positive control groups there were much inflammation, damage in the form of erosion and swelling, bleeding a little accumulation of erythrocyte cells. In addition, epithelial cells underwent degeneration and necrosis in the mucosa of the cecum.

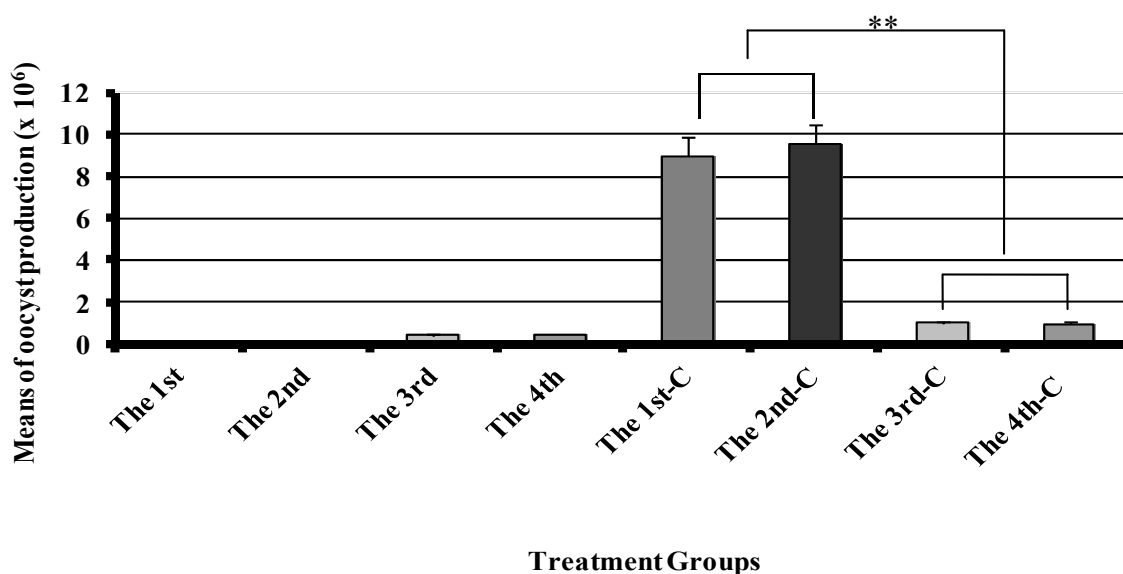


Fig. 1. The comparison of oocyst production between non immunized and immunized chicken groups of attenuated *E. tenella*. \*\*, p<0.01

The damage on administered with precocious line groups was lighter compared to that on positive control group such as less inflammation, less damage to the mucosa and only a small fraction undergoing changes, degeneration and necrosis. Of the two different groups, the developmental stage of the parasite seen surrounded by inflammatory cells was the body's response to antigens entering the chicken (Fig. 2). Some changes in anatomic pathology in the cecum of chickens after being infected with *E. tenella* oocysts that can be seen included cell degeneration, inflammation, necrosis, hemorrhage, and mucosal erosions.

Table 2. The comparison lesion score between non immunized attenuated *E. tenella* and immunized attenuated *E. tenella* which then challenged with homologous and heterologous strains, respectively

Treatment groups	Means ± SD
The 1 <sup>st</sup> group	3.34 <sup>a</sup> ± 0.01
The 2 <sup>nd</sup> group	3.41 <sup>a</sup> ± 0.42
The 3 <sup>rd</sup> group	1.34 <sup>b</sup> ± 0.42
The 4 <sup>th</sup> group	1.22 <sup>b</sup> ± 0.31

Superscript is different in same column represented significant difference (p<0.05)

The presence of inflammation indicated that infectious process (*E. tenella*) in the host was running. In addition to inflammatory cells, it was also found that epithelial cells underwent inflammation (swelling) due to the cell's defense against infection. Damage occurring to the mucosa was caused by the development of schizonts, gametes and oocysts of *E. tenella* on mucosal epithelial cells, especially at the top. Forms of mucosal damage were in the form of swelling and erosion. On average, in the immunized precocious line groups mucosal epithelial damage seen in pathology was not a serious damage. This was due to the damage occurring only in the upper part of the mucosa and not up to the crypt area or muscular layers. In fact, more or less mucosal damage caused a reduction in the surface area of the cecum mucosa to absorb nutrients<sup>4</sup>. Thus in chickens infected with *E. tenella* impaired absorption of nutrients can occur and it can potentially affect the weight of the chicken.

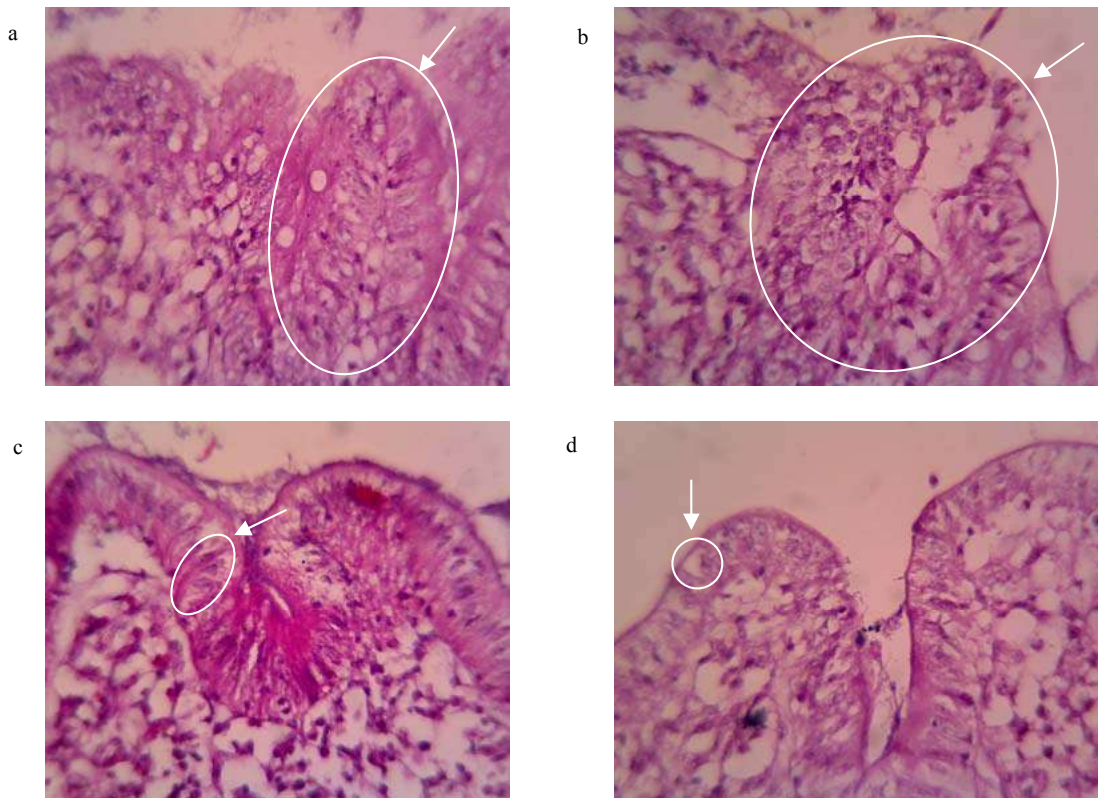


Fig. 2. The increase of protective immunity (decrease of damage target cell by parasite). a and b, non immunized attenuated *E. tenella*.(parent strain); c and d, immunized attenuated *E. tenella* which were then challenged with homologous and heterologous strains, respectively; arrow, development of parasites.

The number of parasites (total schizont) in the cecum histopathology preparations was counted at each of ten randomly Liberkhun crypts in each preparation<sup>5</sup> with a magnification of 400 times. Administered with precocious line groups showing a pattern of growing number of schizont in the mucosa of the cecum was significantly different compared to positive control groups that means the development of parasite to become sexual generation was a similar pattern (Fig. 2).

Total of oocyst production on administered with precocious line groups were reduced significantly compared to that on positive control group (Fig. 1). The decrease in the production of oocysts of groups administered with precocious line was about  $\pm$  85-90 % compared to that of positive control group.

Positive control groups showed clear clinical symptoms such as bloody diarrhea, depression, decreased appetite, and weakness. This was because positive control group had not been exposed to *E. tenella* antigens previously so that protective immunity had not been established to respond to incoming antigens. Clinical symptoms were a manifestation of the development of the parasite occurring in the cecum to the damage caused by endogenous development. Bloody diarrhea was caused by rupture of the mature schizont stage that occurs in the cecum epithelial cells in large quantities so that the blood vessels were damaged. The amount of blood coming out in some cases caused anemia and followed by weakness and decreased appetite. Morbidity due to infectious caused depression in the infected chickens. Administered with precocious line groups showed no obvious clinical symptoms and chickens survived. This was because the chicken had known antigens inducing protective immunity. The responses were related to the role of cell mediated immunity in the intracellular parasite infections such as *E. tenella*.

Changes anatomical pathology; Severity of attack or coccidiosis infection was influenced by the number of parasites that infected (dose of infection), immune power and age of host. Ten thousands of oocysts of *E. tenella* dose in this study led to pathological changes in the mucosa of the cecum where mucosal bleeding was visible as evidenced by histopathologic form of bleeding, tissue degeneration and necrosis and infiltration of inflammatory

cells covering almost three-quarters of the field of view of the sample under a microscope to infection first. It caused each age group level chicken not to be infected so the chicken had not been stimulated both cellular immunity via cell-mediated and humoral immunity. This was because the chicken's body was not familiar with incoming antigens. Once chicken was infected with *Eimeria* antigens and recovered from the infection, it will have immunity. Yet, this immunity had short lifespan, unless the chickens were always associated with coccidia<sup>6</sup>.

On the fourth day post-infection at mucosal bleeding cecum, there was the tunica propria layer infiltration of eosinophils, lymphocytes, monocytes and plasma cells in the mucosa and sub-mucosa of the cecum<sup>7</sup>. In the muscular layer, focal necrosis was seen around the blood vessels. In addition to the above description of the damage, there was also damage to the layer of the muscular externa. In these circumstances the release of tissue degeneration due to infection *Eimeria* spp was on the seventh day of the release of tissue degeneration<sup>8</sup>.

The extent of damage was minor in administered with precocious line groups due to immune-formed but it was still partially parasitic since it still showed the ability to inflict significant lesions. One of the factors that affected immunity against coccidiosis was exposure to parasite antigens in the host<sup>9</sup>. The previous research found a refractile body antigen (indicated as SO7) in the sporozoite of *E. tenella* which were able to provide real protection against lesions of the cecum and weight loss in chickens inoculated with a form of SO7 antigen<sup>9</sup>.

After passing the infectious agent of non-specific immune system, the development of the infectious agent should not be disturbed or in accordance with the life cycle and then continue in the face of specific components of the immune system. This was in contrast to the control group, in which oocysts were able to pass components of the non-specific and specific immunity. Specific immune system's main role involved B cells and T cells and macrophages as the cell processor (APC)<sup>11</sup>. The role of the specific immune system was caused by the chicken experiment at the first contact with the infectious agent that oocysts directly responded to specific immunization process that was also running as it should, so the infectious agent in the continuing development of its life cycle in the host did not run perfectly until eventually a number of oocysts produced and released through feces decreased<sup>10</sup>.

The presence of inflammation indicated that infectious process (*E. tenella*) in the host was running. In addition to inflammatory cells, it was also found that epithelial cells underwent inflammation (swelling) due to the cell's defense against infection. Damage occurring to the mucosa was caused by the development of schizonts, gametes and oocysts of *E. tenella* on mucosal epithelial cells, especially at the top. Forms of mucosal damage were in the form of swelling and erosion. On average, in the immunized precocious line groups mucosal epithelial damage seen in pathology was not a serious damage. This was due to the damage occurring only in the upper part of the mucosa and not up to the crypt area or muscular layers. In fact, more or less mucosal damage caused a reduction in the surface area of the cecum mucosa to absorb nutrients<sup>4</sup>. Thus in chickens infected with *E. tenella* impaired absorption of nutrients can occur and it can potentially affect the weight of the chicken.

#### 4. Conclusion

Attenuated *E. tenella* through serial passages of precocious lines in naive chicken could induce protective immunity which was represented by declining oocyst production and histopathological changes in cecum to homologous and heterologous challenges.

#### Acknowledgements

This research was supported by Directorate of Higher Education, Ministry of Education and Culture of the Republic of Indonesia for funding through higher education excellence research grant for a research contract number 965/UN3/2014. We specially thank to Ms Titah A.R for skilled technical assistance.

#### References

1. Idris, A. B., Bounous, D. I., Goodwin, M. A., Brown, J. and Krushinskie, E. A. 1996. Lack of correlation between microscopic lesion scores and gross lesion scores in commercially grown broilers examined for small intestinal *Eimeria* spp. coccidiosis. *Avian Dis.* 41: 388 – 391.
2. Yunus, M., Horii, Y., Makimura, S and Smith, A. L. 2005. The relationship between the anticoccidial effects of clindamycin and the development of immunity in the *Eimeria pragensis*/Mouse model of large intestinal coccidiosis. *J. Vet. Med. Sci.* 67 (2): 165 – 170.
3. Steel, R. G. D. and Torrie. 1995. Prinsip dan Prosedur Statistika. Penerbit P.T. Gramedia Pustaka Utama Jakarta. Hal. 168-181.
4. Van Kruiningen. 1998. Induction of secretion and surface capping of microneme proteins in *Eimeria tenella*. *Mol. Biochem. Parasitol.* 110: 311 – 321.
5. Sari, S. K. 2007. Studi perkembangan jumlah dan ukuran skizon pada ayam yang diinfeksi pertama kali dan mengalami reinfeksi oleh *Eimeria tenella* [Skripsi]. Fakultas Kedokteran Hewan. Universitas Airlangga. Surabaya.

6. Rose, M. E. 1987. Immunity to *Eimeria* infections. *Vet. Immunol. Immunopathol.* 17: 333 – 343.
7. Levine, N. D. 1985. *Protozoologi Veteriner*. Gadjah Mada University Press. Yogyakarta. Hal.180 -198.
8. Reid, W. M. 1972. Coccidiosis. In. C. H. Helbolt, M. S. Hofstad, B. W. Calnek, W. M. Reid and H. W. Morder ed. *Disease of poultry* 6<sup>th</sup> ed. Iowa State University Press. Ames.
9. Tizard, I. R. 2000. *Veterinary Immunology An Introduction* 6<sup>th</sup> Edition.
10. Kopko, S. H., Martin, S. and Barta, J. B. 2000. *Eimeria tenella* administered using various immunizing strategies. *Poult. Sci.* 79: 336-342
11. Sanderson, I. R., Quellette, A. J., Carter, E. A., Walker, W. A. and Harmatz, P. R. 1993. Differential regulation of B7 mRNA in enterocytes and lymphoid cells. *Immunology* 79:434-438.