

THE EFFICACY OF PERMOT (Passiflora foetida Linn.) LEAVES CRUDE EXTRACT OINTMENT ON THE HEALING OF SKIN OF RABBIT WITH SCABIES

by Poedji Hastutiek

Submission date: 12-Aug-2020 02:10PM (UTC+0800)

Submission ID: 1368707816

File name: The_Efficacy_of_Permot_Passiflora_foetida....pdf (3.2M)

Word count: 2449

Character count: 13921

Conference Paper

THE EFFICACY OF PERMOT (*Passiflora foetida* Linn.) LEAVES CRUDE EXTRACT OINTMENT ON THE HEALING OF SKIN OF RABBIT WITH SCABIES

Poedji Hastutiek and Hana Eliyani

Faculty of Veterinary Medicine Universitas Airlangga

Abstract

This research aimed to know the efficacy of active compound of Permot (*P. foetida*) leaves crude extract ointment as a bioacaricide in rabbit through observation of after treatment histopathological changes on skin of body part naturally infested with *Sarcoptes scabiei*. Permot leaves were isolated and extracted in n-hexane solvent. Sixteen rabbits were randomly divided into four groups, control (Po), P1, P2 and P3, the group of rabbits with scabies treated respectively with 5, 10 and 15% of permot leaves crude extract ointment. Therapy was conducted topically on day 0; 1; 2; 3; 4; 5. Efficacy was examined from Haematoxylin Eosin (HE) stained skin histopathological features under microscope with magnification of 100x, 400x and 1000x. The obtained skin histopathological feature data were assessed qualitatively. The application of 5% ointment (P1) showed erosion and severe inflammatory cells infiltration in the epidermis; follicle proliferation and sebaceous were not present. In the dermis, severe sebaceous adenitis and folliculitis were evident. Massive inflammatory cells infiltration was found in hypodermis. The therapy using 5% ointment resulted 45% success rate. The application of 10% permot leaves crude extract ointment (P2) showed severe hypergranulation in the epidermis, severe proliferation of follicle and sebaceous gland, mild sebaceous adenitis and mild folliculitis in the dermis, as well as moderate inflammatory cells infiltration in the hypodermis. The therapy using 10% ointment resulted 60% success rate. The application of 15% ointment (P3) showed mild hypergranulation in the epidermis, mild follicle proliferation and inflammatory cells (PMN) infiltration in the dermis; and moderate inflammatory cells infiltration in the hypodermis. The therapy using 15% ointment resulted 90% success rate.

Keywords: scabiosis, rabbits, *Passiflora foetida*, ointment, histopathology.

1. Background of the Problem

Scabies is a mange caused by *Sarcoptes scabiei*. This skin disease is chronic, difficult to cure and quite high in prevalence (61%). *Sarcoptes* sp., *Demodex* sp and *Chorioptes* sp.,

Corresponding Author:
Poedji Hastutiek

Received: 03 October 2017
Accepted: 10 October 2017
Published: 29 November 2017

Publishing services provided
by Knowledge E

© Poedji Hastutiek and Hana Eliyani. This article is distributed under the terms of the Creative Commons Attribution License, which permits unrestricted use and redistribution provided that the original author and source are credited.

Selection and Peer-review
under the responsibility of the
VMIC Conference Committee.

 OPEN ACCESS

How to cite this article: Poedji Hastutiek and Hana Eliyani, (2017) "THE EFFICACY OF PERMOT (*Passiflora foetida* Linn.) LEAVES CRUDE EXTRACT OINTMENT ON THE HEALING OF SKIN OF RABBIT WITH SCABIES" in *The Veterinary Medicine International Conference 2017*, KnE Life Sciences, pages Page 486-496. DOI 10.18502/kls.v3i6.1158

mites infestation in 3 districts in East Java was 15.2%. Scabies in the students of the Islamic boarding school in Malang was 89.9% (Sarjono dkk., 1998). All kinds of animals around the world are susceptible to this disease. Pets that are often suffered from scabies and have a good predisposing factor for the infestation of scabies, is rabbit. This disease is zoonotic, disturbing the community, especially the owner and families will always feel itchy. The itchiness occurs several hours after contact with an animal with scabies. Indonesia has many plants that can be used as medicinal ingredients, but few have been studied either about the beneficial content or pharmacological effects. Therefore it is very important to promote research on beneficial plant material as medicine. One of the medicinal plants containing active ingredients that can be used as bioinsecticides is the Permot plant (*Passiflora foetida* Linn.). Permot leaves extract contains alkaloids, terpenoids and phenols. Terpenoids containing isophytol and phytol have efficacy as bioinsecticide against *Aedes aegypti* mosquito larvae (Hastutiek and Sunarso, 2013). Active compounds of alkaloids and terpenoids had an effect as contact toxins and abdominal toxins against IV instar larvae of *Ae. aegypti* mosquitoes and caused degeneration and cell proliferation of the digestive tract (Hastutiek and Sunarso, 2014). Ointment is one form of topical medication often used for the treatment of skin diseases. The application of 15% Permot leaves crude extract on rabbit suffering from scabies showed that 50% experienced a healing process, crusts were reduced and fur began to grow on the third day (Eliyani and Hastutiek, 2015). The objective of this research was to know the efficacy of active compound of Permot (*P. foetida*) leaves crude extract ointment as bioacaricide in rabbit through observation of after treatment histopathological changes on skin of body part naturally infested with *Sarcoptes scabiei*.

2. Materials and Methods

Sixteen rabbits naturally suffered from scabies that showed clinical symptoms of scabies such as crusting and skin thickening of the ear, alopecia on the muzzle, around the eyes, tail and leg area were used in this study. Animals aged 12-18 months weighing 1-1.5 kg.

Rabbits were adapted to the research environment for one week. Skin/mites scraping was performed on skin of rabbits clinically suffered from scabies on the ear, around the mouth or nose, around the neck and feet before and after treatment to determine the extensiveness (number of mites per microscope field of view) at magnification of 40 x and 100 x.

TABLE 1: Histopathologic changes of rabbit skin after treated with Permot (*P. foetida* Linn.) leaves crude extract ointment at concentrations of 5% (P1), 10% (P2), 15% (P3) and healthy rabbits (control) with HE staining observed under a microscope at 100 × magnification.

TREATMENT	HISTOPATHOLOGICAL CHANGES			DESCRIPTION
	EPIDERMIS	DERMIS	HIPODERMIS	
KONTROL	Normal	Normal	Normal	
P1 5%	1.Erosion 2.severe inflammatory cells infiltration	1.follicle proliferation and Sebaceous gland was not present 2. severe sebaceous adenitis berat 3. Folikulitis berat	1. severe inflammatory cells infiltration	Treatment conducted on scabies skin was 45% successful
P2 10%	1.severe hypergranulation	1.follicle proliferasi folikel dan kel. Sebaceous berat 2. mild Sebaceous adenitis 3. mild folliculitis ringan	1. moderate inflammatory cells infiltration	Treatment conducted on scabies skin was 60% successful
Po 15%	mild hypergranulation	1.follicle proliferation 2.mild inflammatory cells (PMN) infiltration	normal	Treatment conducted on scabies skin was 90% successful

Treatments on rabbits included 5, 10 and 15% Permot leaves crude extract ointment applied topically once daily for five consecutive days. In Po group rabbits were healthy and merely smeared with vaseline. In P1, P2 and P3 groups rabbits suffering from scabies were treated topically with ointment at concentration of 5, 10 and 15% respectively at day 1-5.

At day 6 all rabbits were anesthetized and sacrificed. The skin parts of the treated lesion were collected, washed with physiological sodium chloride and kept in pots prefilled with 10% formalin, and subsequently processed into histopathological preparations.

Rabbit skin histopathological preparation were observed under a microscope with magnification of 100, 400 and 1000x. Skin histopathological feature data from five different field of view were assessed qualitatively.

3. Research Results

The observation of histopathologic changes in rabbit skin that are naturally infested with *S. scabiei* after treated with Permot (*P. foetida* Linn.) leaves crude extract ointment compared with normal rabbits with HE staining observed under a microscope at 100 × magnification are presented in Table 1 below.

4. Histopathological Features of Rabbit Skin after Treatment

4.1. On Normal Skin (Control)

In the control it was seen normal histopathological features i.e. the dermis layer, epidermis layer and hair follicles in normal circumstances and no change. This was because the control was just smeared with vaseline only.

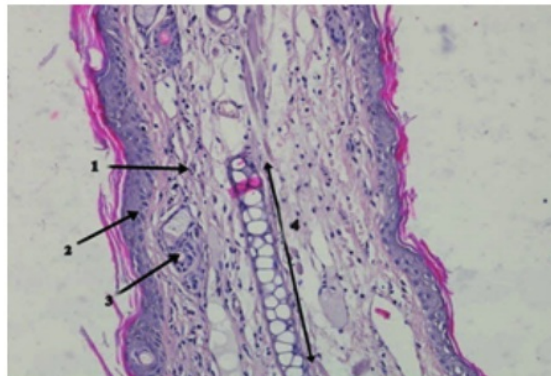


Figure 1: Normal skin; 1= dermis layer; 2= epidermis layer; 3= Hair follicle; 4= cartilage. (HE staining, 100 × magnification; Nikon H600L microscope; DS Fi2 300 megapixel camera).

4.2. Treatment 1 (5%)

In the application of 5% Permot leaves crude extract ointment, it was seen that erosion and infiltration of inflammatory cell was severe in the epidermis. Proliferation of follicles and sebaceous glands were not present, severe sebaceous adenitis, severe folliculitis in the dermis. Severe inflammatory cell inflammation in the hypodermis. Treatment conducted on scabies skin resulted a success rate of 45%.

4.3. Treatment 2 (10%)

In the application of 10% Permot leaves crude extract ointment, there was a severe hypergranulation in the epidermis. Proliferation of the follicle and the severe sebaceous glands, mild sebaceous adenitis, mild folliculitis of the dermis. Moderate inflammatory cells infiltration in the hypodermis. Treatment conducted on the scabies skin resulted a success rate of 60%.

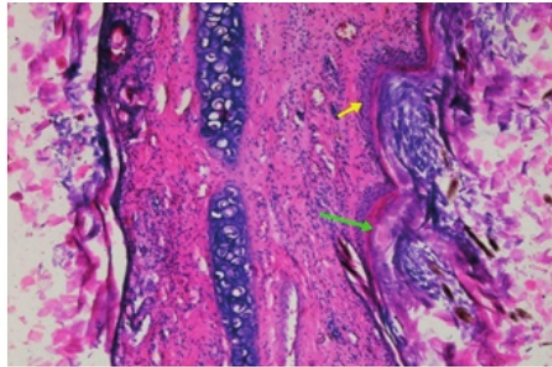


Figure 2: Erosion occurred in the epidermis so that the epidermal layer was thinning due to severe hyperkeratosis (green arrow) and severe infiltration of inflammatory cells (yellow arrow). (HE staining, 1000 × magnification).

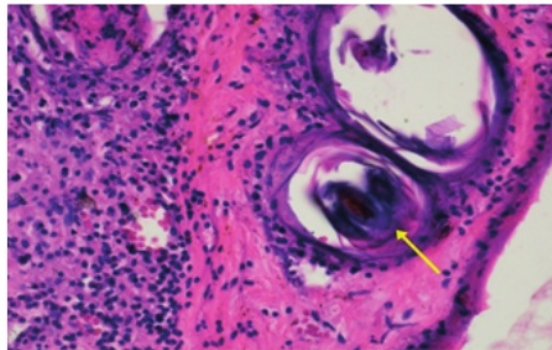


Figure 3: Proliferation of follicles in the dermis (yellow arrow). (HE staining 400 × magnification).

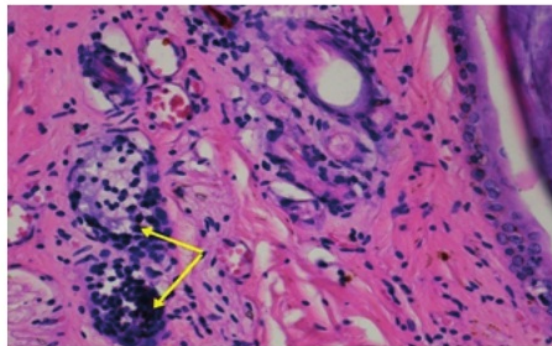


Figure 4: Severe Sebaceous adenitis in the dermis (yellow arrow). (HE staining, 400 × magnification).

4.4. Treatment 3 (15%)

In the application of 15% Permot Leaves crude extract ointment, there was a mild hypergranulation in the epidermis. Follicle proliferation and mild inflammatory cells

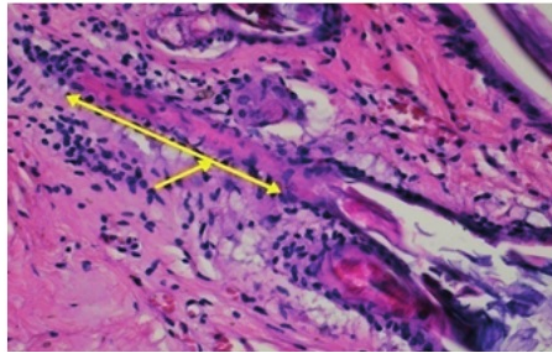


Figure 5: Severe folliculitis of the dermis (yellow arrow). (HE staining, 400 × magnification).

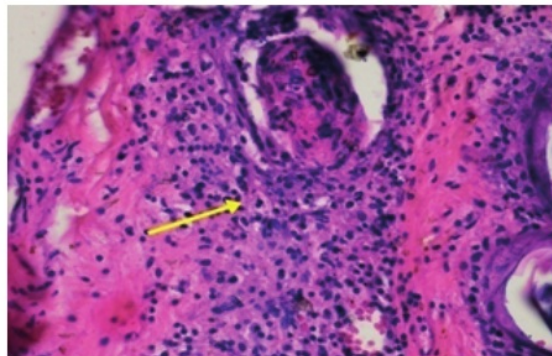


Figure 6: Severe inflammatory cells infiltration in hypodermis (yellow arrow). (HE staining, 400 × magnification).

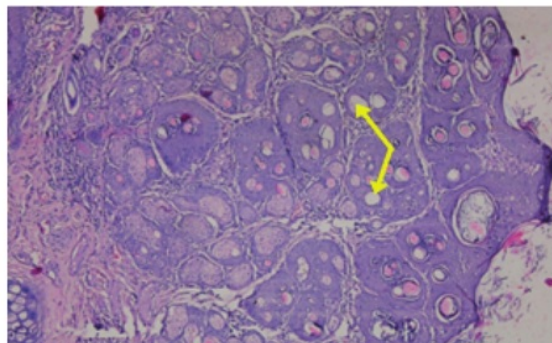


Figure 7: Severe hypergranulation occurred in the epidermis (yellow arrow). (HE staining, 1000 × magnification).

infiltration (PMN) in the dermis. Moderate inflammatory cells infiltration in hypodermis. Performed treatment on skin with scabies resulted a success rate of 90%.

Successful therapy with Permot leaves crude extract ointment in all treatment groups was caused by the content of alkaloids, flavonoids and saponins. The alkaloid

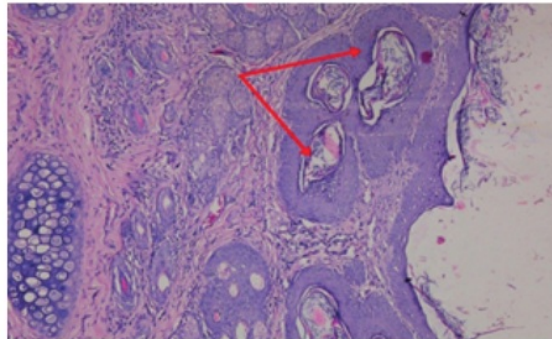


Figure 8: Follicular proliferation due to damage (red arrow). (HE staining, 1000 × magnification).

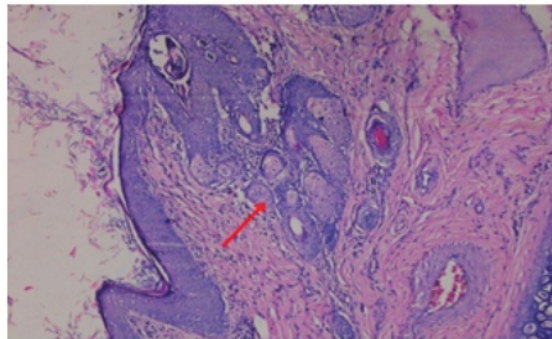


Figure 9: Severe sebaceous glands in the dermis (red arrow). (HE stain 1000 × magnification).

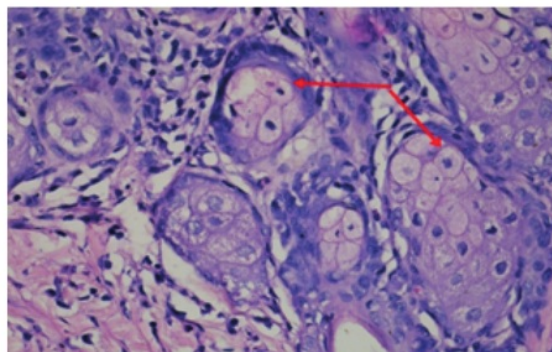


Figure 10: Mild Sebaceous adenitis in the dermis (red arrow). (HE staining, 400 × magnification).

active compound acted on the ganglia of the central nervous system. Alkaloids are very effective against various insects, especially soft-bodied insects. In mites, alkaloids and saponins worked both as contact poison and stomach poison. Alkaloids and saponins had the ability to work as good contact poison because of the ability to penetrate the insect cuticle which killed slowly followed by stop feeding action (antifeedant), and also caused digestive system disorders because alkaloids acted as stomach poison that

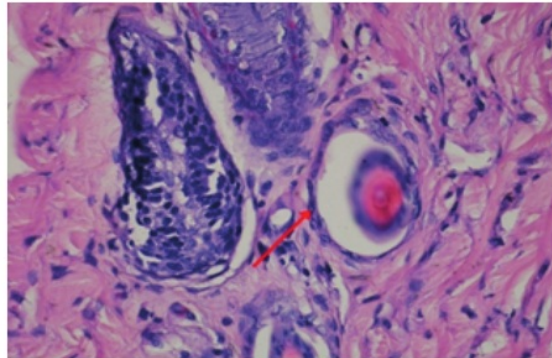


Figure 11: Mild folliculitis in the dermis (red arrow); (HE staining, 400 × magnification).

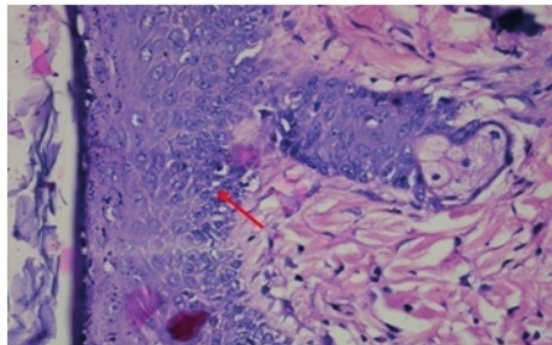


Figure 12: Moderate inflammatory cells infiltration in hypodermis (red arrow); (HE staining, 400 × magnification).

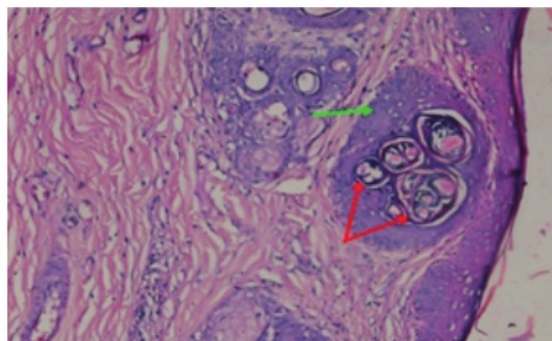


Figure 13: Mild hypergranulation in the epidermis (green arrow) and follicular proliferation in the dermis (red arrow). (HE staining, 200 × magnification).

entered through the mouth of larvae (Soparat, 2010). Toxic saponins had properties such as detergents that could increase penetration because of their ability to dissolve the lipophilic material in water and irritated the gastrointestinal mucosa. In addition, it had a bitter taste that decreased the appetite so that the mites would die of starvation

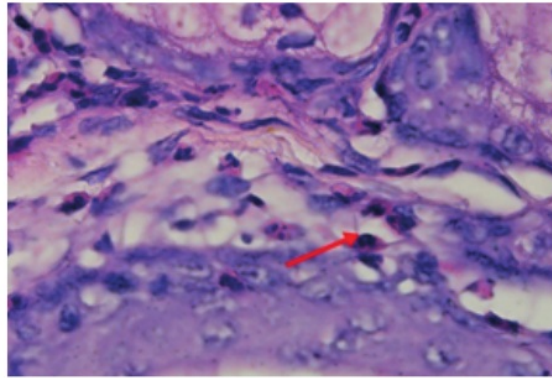


Figure 14: Mild PMN inflammatory cells infiltration in the dermis layer (red arrow); (HE staining, 400 × magnification).

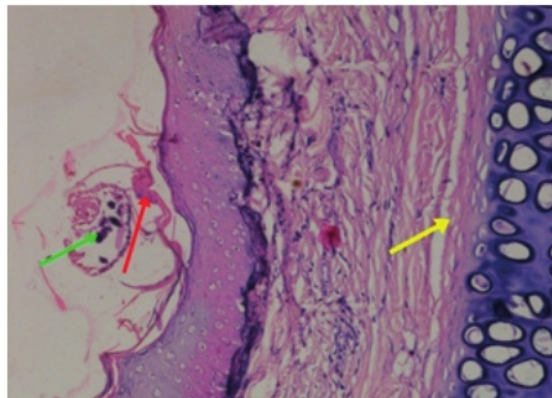


Figure 15: Normal hypodermis (yellow arrow), epidermis under mild hyperkeratosis (red arrow), *Sarcoptes scabiei* mite on the epidermis (green arrow); (HE staining, 200 × magnification).

(Novizan 2002). Flavonoids could enter through the cuticle that lined the body of the mite so that subsequently damaged the cell membranes therefore it could be used as bioacaricida.

The absorption of the active compound as contact poison occurred in the cuticle. The active compound penetrated into the body of the insect through parts covered by thin cuticles, such as intersegmental membranes, the lining of the joints at the base of the feet and the chemoreceptors of the tarsus. The active compound was capable of diffusing from the outermost layer of the cuticle through the deeper layer to the hemolympha, following the flow of hemolympha and dispersed throughout the body of the larvae. Death of mites was due to energy (ATP) depletion in mitochondria and this condition was in accordance with the mechanism of action of the active alkaloid compounds at the cellular level. The active compound inhibited the transfer of electrons on site I by blocking the binding between NADH in the electron transfer

chain in the cell respiration process that resulted in the inhibition of metabolic energy formation process, so that cell respiration ceased and caused death.

This study observed the healing of crusts and alopecia on the skin due to *S. scabiei* mite infestation. This phase began on the third day because the flavonoids played a direct role as antibiotics and antiseptics that could kill microorganisms. Terpenoids acted as antibacterials due to the isopyhtol and phytol compounds (Hastutiek and Sunarso, 2014). Both of which were part of terpenoid which acted as bioacaricide to mites.

5. CONCLUSION

Based on research result about histopathological features of rabbit skin that has been treated with Permot (*Passiflora foetida* Linn.) leaves crude extract for 5 days. The treatment of skin of rabbit with scabiosis using 5% Permot leaves ointment resulted a success rate of 45%. The treatment of skin of rabbit with scabiosis using 10% Permot leaves ointment resulted a success rate of 60%. The treatment of skin of rabbit with scabiosis using 15% Permot leaves ointment resulted a success rate of 90%.

References

- [1] Eliyani H., dan P. Hastutiek. 2015. Efikasi Formulasi Salep Crude Ekstrak Daun Permot (*Passiflora foetida* Linn.) sebagai Terapi Scabiosis pada Kelinci. Lembaga Penelitian dan Pengabdian kepada Masyarakat UNAIR.
- [2] Hastutiek P., dan A. Sunarso. 2013. Identifikasi Komponen Kimia Ekstrak daun Permot (*Passiflora foetida* Linn.) dengan TLC dan GC-MS sebagai Kandidat Bioinsektisida terhadap nyamuk. Seminar Nasional Biologi/IPA dan Pembelajar-annya di Universitas Negeri Malang 1-2 Nopember 2014.
- [3] Hastutiek P., dan A. Sunarso. 2014. Gambaran Histopatologi Saluran Pencernaan Larva Instar IV Nyamuk *Aedes aegypti* setelah perendaman dengan Senyawa Aktif Daun Permot (*Passiflora foetida* Linn.) dan potensinya sebagai Bioinsektisida. *Vet. Medika* 8(2): 137-144.
- [4] Novizan. 2002. Membuat dan memanfaatkan Pestisida ramah lingkungan. Jakarta: Agromedia Pustaka, Hal 77.
- [5] Sardjono, T.W., S. Poeranto, L. Hakim, P. Sanjoto, dan Sobaktiningsih. 1998. Faktor-Faktor-faktor terhadap keberhasilan penanggulangan scabies di pondok pesantren. *Majalah Parasitol. Indonesia* 11: 33-42.

- [6] Soparat, S. 2010. Chemical ecology and function of alkaloids. <http://pirun.ku.ac.th/g4686045/media/alkaloid.pdf>. (dikutip: 10 September 2011)

THE EFFICACY OF PERMOT (*Passiflora foetida* Linn.) LEAVES CRUDE EXTRACT OINTMENT ON THE HEALING OF SKIN OF RABBIT WITH SCABIES

ORIGINALITY REPORT

8%

SIMILARITY INDEX

3%

INTERNET SOURCES

3%

PUBLICATIONS

7%

STUDENT PAPERS

PRIMARY SOURCES

1

Submitted to Universitas Airlangga

Student Paper

7%

2

Abdul Khair, Noraida Noraida. "Young and Old Sugar Apple (*Annona squamosa* Linn) Leaf Extracts As an *Aedes aegypti* Larva Insecticide", *Medical Laboratory Technology Journal*, 2019

Publication

1%

Exclude quotes Off

Exclude matches Off

Exclude bibliography On

THE EFFICACY OF PERMOT (*Passiflora foetida* Linn.) LEAVES CRUDE EXTRACT OINTMENT ON THE HEALING OF SKIN OF RABBIT WITH SCABIES

GRADEMARK REPORT

FINAL GRADE

/0

GENERAL COMMENTS

Instructor

PAGE 1

PAGE 2

PAGE 3

PAGE 4

PAGE 5

PAGE 6

PAGE 7

PAGE 8

PAGE 9

PAGE 10

PAGE 11
